Ref

TOXICOLOGY AND APPLIED PHARMACOLOGY 18, 944–957 (1971)

Toxicity of Hexachlorobenzene in Japanese Quail with Special Reference to Porphyria, Liver Damage, Reproduction, and Tissue Residues

J. G. VOS, H. L. VAN DER MAAS, A. MUSCH, AND ERICA RAM

Institute of Veterinary Pathology and Institute of Veterinary Pharmacology and Toxicology, University of Utrecht, Biltstraat 172, Utrecht, The Netherlands

Received August 6, 1970

Toxicity of Hexachlorobenzene in Japanese Quail with Special Reference to Porphyria, Liver Damage, Reproduction, and Tissue Residues. VOS, J. G., VAN DER MAAS, H. L., MUSCH, A. and RAM, ERICA. (1971). *Toxicol. Appl. Pharmacol.* 18, 944–957. The fungicide hexachlorobenzene (HCB), was given for 90 days to Japanese quail at dietary concentrations of 0, 1, 5, 20, and 80 ppm. Tremors and mortality occurred in birds fed 80 ppm. Red fluorescence of tissues, liver damage (enlargement of nuclei and nucleoli, proliferation of bile ductules, necrosis of hepatocytes), erythrophagocytosis in the spleen, ceroid granules in the tubules of the kidney, reduced reproduction and reduced volume of eggs were found in birds from the 80 ppm group. Shell-thickness index was unaltered. Increased liver weight, slight liver damage and enlarged fecal excretion of coproporphyrin occurred in the 5 ppm group; the no-effect level was established at 1 ppm. Significantly higher brain residues were found in male compared to female birds. HCB residues in birds of prey found in a certain area are higher than residues found in Japanese quail fed 1 ppm HCB.

Hexachlorobenzene (HCB, C_6Cl_6) is a crystalline substance which is insoluble in water. It is used as a fungicide, to control fungal diseases in cereals; it is also used in organic synthesis.

HCB has been identified in tissues of wild birds in The Netherlands (de Vos, R. W., personal communication). High residues were often found in predatory birds (Vos *et al.*, 1968; Koeman *et. al.* 1969a). It was also detected in fish, mussels, and birds in the aquatic environment (Koeman *et al.*, 1969b). Minor quantities of HCB were found in vegetable and animal fat (Wit, 1970).

HCB became widely known as the result of a mass-poisoning in Turkey. Cam and Nigogosyan (1963) mentioned more than 3000 cases of human poisoning in the years 1955–1959. The main symptoms were photosensitization and porphyrinuria.

The acute toxicity of HCB is low: 500 mg/kg ip is nonlethal in rats; the oral lethal dose in guinea pigs is greater than 3 g/kg (Davis *et al.*, 1959); the oral lethal dose of a 15% suspension of HCB in female Japanese quail is greater than 1 g/kg (unpublished data). Feeding of a diet containing 0.2% HCB resulted within a month in the death of 13 of 33 rats (Ockner and Schmid, 1961). In a preliminary subacute toxicity study in Japanese quail it was found that the feeding of 20 ppm HCB (lowest level) was still lethal (Vos *et al.*, 1968).

59344

HEXA

The present study was carried
uail in order to evaluate residu

Seventy-five adult Japanese qu
a 90-day feeding experiment. T
dark. The food consisted of
imals were wing-banded indiv
ents. Groups of 15 quail (12 fe
ived diets containing 0, 1, 5, 2
rity ≥ 99.5% C_6Cl_6).
The quail were fed and watere
cretion of coproporphyrin and
was determined according t
ckman spectrophotometer. Fe
same cage. At the end of th
ces were homogenized and alic
s.

Egg production in the differen
oduction per female per day. E
1–90 were incubated to determi
y rotated and was maintained
midity of 70%. Eggs which fa
re infertile or contained a dea
cted in the last month of the ex
ss, according to the method o
oduct of length and breadth (
opsy, all animals that died or
cted to a gross pathologic ex
raviolet light using red fluores
ies of porphyrins. Total body
art were recorded.
Microscopic examination wa
duct, heart, lung, thyroid, cr
e, cecum, large intestine, sk
ed in 10% buffered formalin,
d eosin. Sections of liver, sple
oreover, selected sections wer
thyl green-pyronin and for H
stained Paraplast-embedded
liver, kidney, and small inte
roscope (Zeiss, exciting filte
ram super pressure lamp HE
In order to carry out hemat
bdivided into 3 groups, were

9136

The present study was carried out to establish a no-effect level of HCB in Japanese quail in order to evaluate residues found in wild birds.

METHODS

Seventy-five adult Japanese quail (*Coturnix coturnix japonica*), 2.5 mo old, were used in a 90-day feeding experiment. They were maintained under a regimen of 14 hr light: 10 hr dark. The food consisted of a turkey starter ration containing 22% protein. The animals were wing-banded individually and allocated at random to the various treatments. Groups of 15 quail (12 females and 3 males; 4 females and 1 male per cage) received diets containing 0, 1, 5, 20, and 80 ppm HCB (B.D.H. microanalytical reagent, purity $\geqslant$ 99.5% C_6Cl_6).

The quail were fed and watered ad libitum and were weighed weekly. The 24-hr fecal excretion of coproporphyrin and protoporphyrin, as parameters for chemical porphyria, was determined according to the method described by Rimington (1961), using a Beckman spectrophotometer. Feces of the different groups were collected always from the same cage. At the end of the experiment feces were analyzed from all cages. The feces were homogenized and aliquots of 1–2 g were used for spectrophotometric analysis.

Egg production in the different subgroups was recorded and calculated as mean egg production per female per day. Eggs collected during days 37–46, days 64–73 and days 81–90 were incubated to determine the hatch of fertile eggs. The incubator automatically rotated and was maintained at an optimum temperature of 37.2°C and a relative humidity of 70%. Eggs which failed to hatch were opened to determine whether they were infertile or contained a dead embryo. Moreover, 25 eggs of each group were collected in the last month of the experiment to determine the index for the egg-shell thickness, according to the method of Ratcliffe (1967): egg-shell weight (mg) divided by the product of length and breadth (mm). Also, the volume of those eggs was recorded. At autopsy, all animals that died or were killed at the end of the feeding period were subjected to a gross pathologic examination. In addition, organs were examined under ultraviolet light using red fluorescence as an indicator for the presence of excess quantities of porphyrins. Total body weight and the weight of the liver, kidneys, spleen, and heart were recorded.

Microscopic examination was made of liver, spleen, kidney, pancreas, ovary/testis, oviduct, heart, lung, thyroid, crop, glandular stomach, muscular stomach, small intestine, cecum, large intestine, skin, skeletal muscle, and spinal cord. Specimens were fixed in 10% buffered formalin, embedded in Paraplast, and stained with hematoxylin and eosin. Sections of liver, spleen, and kidney were also stained with Perls' iron stain. Moreover, selected sections were stained with PAS, Sudan black, Ziehl–Neelsen, azan, methyl green-pyronin and for hemoglobin-hemosiderin, reticulin, fibrin, and myelin. Unstained Paraplast-embedded selected sections and unmounted fresh cryostat sections of liver, kidney, and small intestine of killed birds were examined in a fluorescence microscope (Zeiss, exciting filters BG 38/2.5 and BG 12/4, barrier filters 53 and 33, Osram super pressure lamp HBO 200 W).

In order to carry out hematologic examinations, 22 female adult Japanese quail, subdivided into 3 groups, were fed for 4 wk diets containing 0, 20, and 120 ppm HCB.

Terminal blood samples were taken by puncture of the brachial vein. These examinations included hemoglobin and hematocrit determinations, erythrocyte counts, and serum glutamic–oxaloacetic transaminase activity (Reitman and Frankel, 1957) using a Beckman/Spinco 151 specktrocolorimeter.

HCB residues in liver and brain of animals fed 1 and 5 ppm HCB were determined by gas chromatography with electron capture detection (Vos and Koeman, 1970).

In order to determine the recovery of the residue in determinations of HCB, different quantities of HCB were added to 5-g samples of homogenized liver tissue, resulting in 15 final concentrations ranging from 0.2–100 ppm HCB. These determinations showed a mean recovery percentage of 47.9 ± 6.0 SD; a low, but rather constant recovery, due to the rather unfavorable partition coefficient of HCB between hexane and dimethylformamide. A correction for the actual HCB content was not made.

The significance of any difference between the treatment and control groups was measured using the van der Waerden test for 2 unrelated samples, usually on a two-sided significance level (van der Waerden, 1957). This test is a refinement of the Wilcoxon test.

RESULTS

The body weights of female quail fed the 5 ppm and the 20 ppm diet were significantly higher at the end of the study compared with birds fed the 0, 1, and 80 ppm diets (see Table 6). The general health of the birds remained unaffected except for the 80 ppm group; 5 (4 females and 1 male) died between 18 and 62 days of the experiment (Table 1), after a short period of rapid loss of weight, ruffled feathers, tremor, and ataxia.

TABLE 1

MORTALITY AND FLUORESCENCE IN ULTRAVIOLET LIGHT OF JAPANESE QUAIL FED HCB FOR 90 DAYS

Dietary conc (ppm)	Number of birds	Number of deaths	Number of birds showing fluorescence in UV light	
			Macroscopically	Microscopically[a]
0	15	0	0	0
1	15	1	0	0
5	15	0	0	0
20	14	2	2	3
80	15	5	11	8

[a] Only liver, kidney, and small intestine tissue of the killed birds was studied in the UV microscope.

Significant increases in the coproporphyrin excretion (Table 2) were seen at the end of the study in the 5 ppm and higher levels, though a dose-related higher excretion was already visible after 10 days of HCB feeding. This trend was also seen in the protoporphyrin excretion (Table 2), but vanished in the last half of the experiment, following a considerable rise of the protoporphyrin excretion in the control animals.

Macroscopic fluorescence (Table 1) of liver, bile, small intestine, kidneys and [illegible] was found in birds from the 80 ppm group that died, while the killed birds of the [illegible]

TABLE 2

COPROPORPHYRIN AND PROTOPORPHYRIN EXCRETION IN FECES OF HCB-FED JAPANESE QUAIL (μg/24 HOURS BIRD)[a]

TABLE 2

COPROPORPHYRIN AND PROTOPORPHYRIN EXCRETION IN FECES OF HCB-FED JAPANESE QUAIL (μg/24 HOURS/BIRD)[a]

Time of sample (days)	Coproporphyrin					Protoporphyrin				
	Dietary conc (ppm)					Dietary conc (ppm)				
	0	1	5	20	80	0	1	5	20	80
10	14.6 (5)	21.2 (5)	55.2 (5)	59.8 (5)	103.2 (5)	18.4 (5)	20.4 (5)	44.6 (5)	—	119.6 (5)
30	20.2 (5)	36.8 (5)	60.8 (5)	84.4 (5)	135.6 (5)	18.4 (5)	102.0 (5)	54.2 (5)	107.0 (5)	93.6 (5)
52	21.6 (5)	56.2 (5)	49.2 (5)	43.6 (4)	75.0 (3)	63.2 (5)	80.4 (5)	63.6 (5)	113.2 (4)	95.0 (3)
66	35.8 (5)	56.8 (5)	28.6 (5)	64.2 (4)	90.0 (10)	71.8 (5)	64.6 (5)	65.6 (5)	70.8 (4)	87.0 (10)
87-89[b]	26.0 (5) 24.2 (5) 31.8 (5)	32.4 (5) 29.6 (4) 41.0 (5)	72.8 (5) 73.4 (5) 86.0 (5) [c]	55.4 (4) 71.4 (4) 81.2 (4) [c]	112.0 (10)	64.2 (5) 27.4 (5) 101.0 (5)	88.0 (5) 44.4 (4) 67.2 (5)	67.4 (5) 80.6 (5) 85.2 (5)	78.0 (4) 75.6 (4) 99.2 (4)	102.6 (10)

[a] The number of birds per sample is given in brackets.
[b] In this case, feces were collected from 3 separate cages, in order to make statistical analysis possible.
[c] $P < 0.05$, on a one-tail significance level.

showed only a weak red fluorescence of bone. Two birds from the 20 ppm group showed red fluorescence of liver (a bird that died) and liver as well as bone (a killed bird).

The mean egg production per female per day (Table 3) did not differ significantly between the groups. The still high production per living quail in the 80 ppm group is remarkable. The hatchability of the fertile eggs (Table 4) was lower in the control animals as compared with the 1 and 5 ppm groups. A strongly reduced hatchability

TABLE 3

EGG PRODUCTION OF JAPANESE QUAIL FED HCB FOR 90 DAYS

Dietary conc (ppm)	Mean egg production per female per day		
	Cage 1	Cage 2	Cage 3
0	0.37	0.49	0.30
1	0.34	0.27	0.64
5	0.44	0.60	0.57
20	0.70	0.71	0.56
80	0.51	0.68	0.46

TABLE 4

REPRODUCTION RESULTS OF JAPANESE QUAIL FED HCB FOR 90 DAYS

Dietary conc (ppm)	Hatchability (% hatch of all fertile eggs)		
	Eggs collected on day 37–46	Eggs collected on day 64–73	Eggs collected on day 81–90
0	36	47	40
1	69	59	62
5	59	56	57
20	27	39	23
80	17	7	0

TABLE 5

SHELL-THICKNESS INDEX AND VOLUME OF EGGS FROM JAPANESE QUAIL FED HCB FOR 90 DAYS[a]

Dietary conc (ppm)	Number of eggs	Shell-thickness index	Volume
0	25	0.93 ± 0.07	10.0 ± 0.7
1	25	0.96 ± 0.07	9.9 ± 0.3
5	25	0.92 ± 0.09	10.1 ± 0.8
20	25	0.91 ± 0.07	9.4 ± 0.8[b]
80	25	0.94 ± 0.06	9.1 ± 0.9[c]

[a] Mean values ± SD.
[b] $P \leq 0.05$.
[c] $P \leq 0.01$.

TABLE 6

ORGAN WEIGHTS AND ORGAN:BODY WEIGHT RATIOS OF KILLED FEMALE JAPANESE QUAIL FED HCB FOR 90 DAYS[a]

Organ weight (g)

TABLE 6

ORGAN WEIGHTS AND ORGAN:BODY WEIGHT RATIOS OF KILLED FEMALE JAPANESE QUAIL FED HCB FOR 90 DAYS[a]

Dietary conc (ppm)	Number of female birds	Terminal body weight (g)	Organ weight (g)			
			Heart	Liver	Spleen	Kidneys
0	12	149 ± 8.7	1.16 ± 0.08	4.61 ± 1.03	0.067 ± 0.026	1.39 ± 0.18
1	11	148 ± 13.4	1.18 ± 0.21	4.71 ± 0.98	0.067 ± 0.041	1.31 ± 0.17
5	12	157 ± 10.1[b]	1.24 ± 0.13	6.35 ± 1.65[b]	0.062 ± 0.015	1.58 ± 0.29
20	9	161 ± 10.6[b]	1.36 ± 0.22[b]	7.64 ± 1.35[c]	0.064 ± 0.013	1.64 ± 0.17
80	7	148 ± 15.5	1.03 ± 0.15	7.95 ± 2.28[c]	0.045 ± 0.015	1.37 ± 0.12
			Organ:body weight ratio (g/100 g body weight)			
0	12		0.78 ± 0.07	3.08 ± 0.57	0.045 ± 0.017	0.93 ± 0.08
1	11		0.80 ± 0.14	3.18 ± 0.66	0.047 ± 0.031	0.88 ± 0.08
5	12		0.79 ± 0.07	4.04 ± 0.96[b]	0.039 ± 0.030	1.01 ± 0.18
20	9		0.85 ± 0.12	4.75 ± 0.71[c]	0.040 ± 0.008	1.03 ± 0.11[b]
80	7		0.70 ± 0.10[b]	5.31 ± 1.25[c]	0.031 ± 0.011	0.93 ± 0.05

[a] Mean values ± SD.
[b] $P < 0.05$.
[c] $P < 0.01$.

was found in eggs from the 80 ppm group when compared with the controls. Egg-shell thinning did not occur in any of the test groups, but the egg volumes were significantly reduced in the 20 ppm and 80 ppm groups (Table 5).

Organ weights and organ: body weight ratios of the female quail are given in Table 6. The heart weights increased significantly in the 20 ppm group, while the heart-body weight ratios were decreased significantly in the 80 ppm group. Liver weights and liver body weight ratios increased significantly in birds fed the 5, 20, and 80 ppm HCB diets. Kidney: body weight ratios were increased significantly in the 20 ppm group. Dose related, increased liver weights were also observed in the males (3 birds per group).

Microscopic examination revealed the presence of lymphoid foci in practically all tissues of birds from all groups, including control animals. The distribution and meaning of those foci in chickens is already described by Lucas *et al.* (1954).

Since HCB is a hepatotoxic compound, special attention was paid to this organ. Pathologic findings in the liver of killed birds are given in Table 7. Histologic examination of all livers showed the presence of light to sometimes moderate centrolobular fatty infiltration in many, mainly female birds including the control animals. This infiltration

TABLE 7

PATHOLOGIC FINDINGS IN LIVERS OF JAPANESE QUAIL FED HCB FOR 90 DAYS

Dietary conc (ppm):	0		1		5		20		80	
Number of birds:	12 ♀	2 ♂	11 ♀	3 ♂	12 ♀	3 ♂	9 ♀	3 ♂	8	2 ♂
Heterophils infiltration in lymphoid foci	2	—	2	—	1	—	4	—	5	
Heterophils infiltration in periportal area	1	—	—	—	—	—	2	—	5	
Heterophils in sinusoids	1	—	1	—	2	—	4	—	4	1
Basophilic cells in sinusoids	—	—	—	—	1	1	3	—	4	
Scattered swollen degenerated hepatocytes (cellular edema)	—	—	—	—	2	—	2	—	5	2
"Foamy" aspect of isolated hepatocytes	—	—	—	—	—	—	3	—	6	
Lysis of isolated hepatocytes	1	—	—	—	1	—	1	—	4	
Necrosis of isolated hepatocytes	—	—	—	—	1	1	2	—	3	
Enlargement of nuclei	—	—	—	1	1	2	5	1	2	
Hypertrophy of nucleoli	—	—	—	—	7	1	5	1	4	2
Proliferation of bile ductules and "oval" cells	—	—	—	—	1	1	5	—	2	
Protein droplets in hepatocytes, sinusoids, or central veins	—	—	—	—	1	1	5	—	5	2

was mostly limited to the margin of the lateral part of the left lobe. The morphology varied between plurivacuolar and large monovacuolar infiltrations. The frequency of fatty infiltration decreased with increasing HCB concentration; it was only incidentally found in birds fed 80 ppm. It was considered not to be due to the HCB treatment, since it is a common finding in laying birds. Perls' stain for iron generally resulted in more positive Kupffer cells and parenchymal cells in birds fed the 80 and 20 ppm diets. The Perls' positive material in the Kupffer cells stained also PAS positive, slightly Sudan black, and Ziehl-Neelsen positive and showed a yellow-brownish fluorescence. The

HCB-induced enl
stain: the nucleoli
content. Liver dar

1

2

FIG. 1. Severely aff
the hypertrophied nu
(black arrow). Hema
FIG. 2. Erythropha
red blood cells in th
macrophages (white

HCB-induced enlarged liver cell nucleoli were studied, using the methyl green-pyronin stain: the nucleoli stained intensely with pyronin, which indicates an increase of RNA content. Liver damage in the birds dying from the 80 ppm diet was more severe: especi-

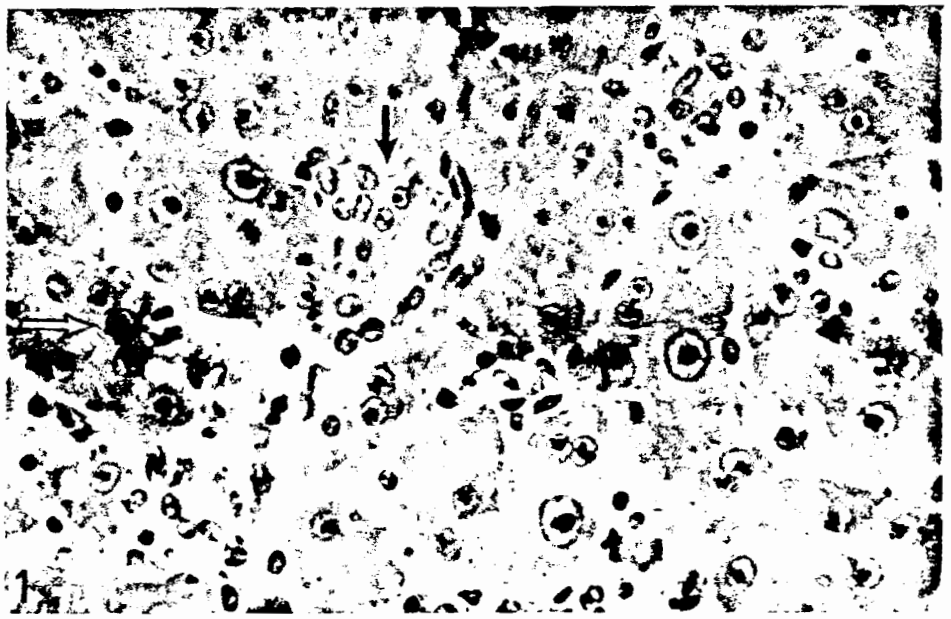



FIG. 1. Severely affected liver of a killed female bird from the 80 ppm group. Note the enlarged nuclei, the hypertrophied nucleoli (white arrow), and the proliferation of bile ductules and bile ductular cells (black arrow). Hematoxylin and eosin. × 640.

FIG. 2. Erythrophagocytosis in the spleen of a killed bird fed 80 ppm HCB. Marked sequestration of red blood cells in the reticular tissue of the white pulp (black arrow), surrounded by iron-loaded macrophages (white arrow). Hemoglobin-hemosiderin. × 640.

ally the enlargement of the nuclei (Fig. 1), necrosis of single parenchymal cells, the occurrence of protein droplets, proliferation of bile ductules in the portal region and the occurrence of "oval" cells. These "oval" cells are probably proliferating ductular

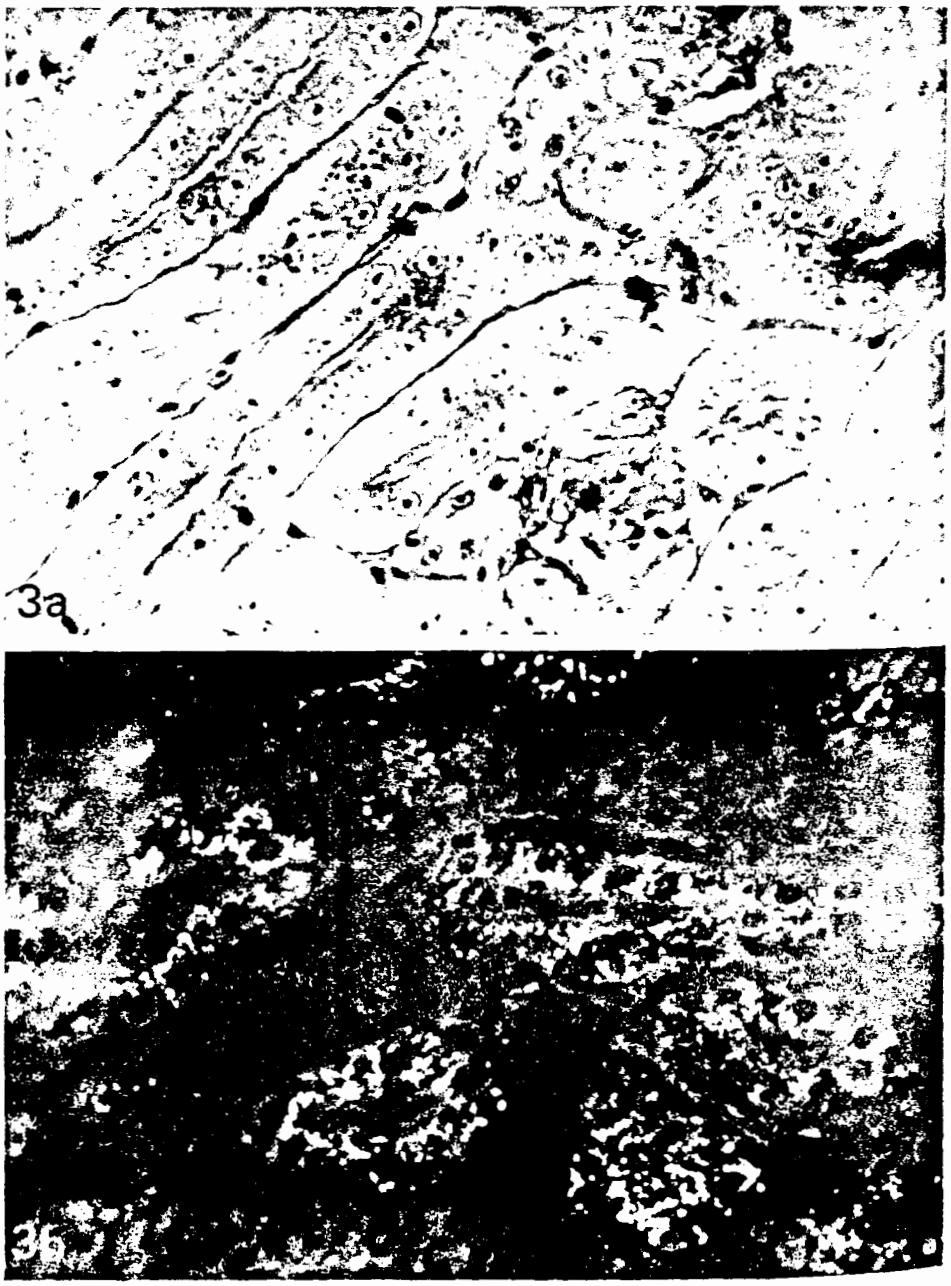

FIG. 3. Ceroid granules in the kidney tubules of a female quail fed HCB for 90 days. (a) PAS-positive ceroid granules in the cytoplasm of tubular cells. Note the decreased PAS staining of the glomeruli. PAS. ×640. (b) Fluorescence of ceroid granules in the tubular epithelial cells. Unstained section. ×640.

epithelial cells as was s
by Grisham and Hart
panied by fibrotic acti
architecture of the lob
protein droplets.

Following the descri
a moderate sequestratio
tissue, surrounding the
rarely in the 20 ppm gr
control and experimen
found in the white pulp
red pulp in birds of the
generally reduced in th
found in this group.

Kidney damage was
fed 20 ppm and to a gre
luted tubules stained so
aspect, and incidentall
center of glomeruli sh
animals. This was ofte
was sometimes less po
were demonstrated in
from the 80 ppm group
group. Selected section
were also positive with
brownish fluorescence

Light to severe loss
skeletal muscle section
accompanied by increa
of fragmented cells. A
died.

The glandular stom
and sometimes necr ti
glands. Infiltration of

In the pancreas of a
crine pancreas was fou

No evidence of any
observed.

The results of the her
4 wk are given in Tabl
creased hemoglobin an
activity was significanti
liver damage found in

Tissue HCB concent
cantly higher brain lev
residues were not sign

epithelial cells as was shown in an electron microscopic study of hepatic degeneration by Grisham and Hartroft (1961). The proliferation of bile ductules was not accompanied by fibrotic activity (azan stain). The reticulin stain showed that the normal architecture of the lobules was preserved. Fibrin could not be demonstrated in the protein droplets.

Following the description by Lucas *et al.* (1954) of the histology of the chicken spleen, a moderate sequestration of erythrocytes (Fig. 2) was found in the wide layer of reticular tissue, surrounding the splenic arteries, in most female birds of the 80 ppm group and rarely in the 20 ppm group. Some sequestration was also recorded in the male birds of control and experimental groups, although it seemed dose-related. Hemosiderin was found in the white pulp macrophages surrounding the reticular tissue (Fig. 2) and in the red pulp in birds of the 80 ppm group and also in 20 ppm fed birds. The red pulp was generally reduced in the 80 ppm group, which might explain the lower spleen weights found in this group.

Kidney damage was also observed in HCB-treated animals. It was found in animals fed 20 ppm and to a greater extent in 80 ppm fed birds; the epithelial cells of the convoluted tubules stained sometimes strongly eosinophilic. Swelling of these cells, a "foamy" aspect, and incidentally protein droplets within the cytoplasm were noted. Rarely, the center of glomeruli showed a smaller number of nuclei than were found in control animals. This was often accompanied by Perls' positive material, while the PAS stain was sometimes less positive. Moderate to large quantities of Perls, positive granules were demonstrated in the convoluted tubules and in the tubuli recti in nearly all birds from the 80 ppm group; slight to moderate quantities in kidney sections of the 20 ppm group. Selected sections of the 80 ppm birds showed that the Perls' positive granules were also positive with PAS, Sudan black, and Ziehl–Neelsen and showed a yellow-brownish fluorescence (Fig. 3a,b).

Light to severe loss of transverse striation under polarized light was found in the skeletal muscle sections of nearly all birds of the 80 ppm group. This was sometimes accompanied by increased birefringence of eosinophilic cells or by loss of birefringence of fragmented cells. Atrophy of muscle cells was also found in birds of this group which died.

The glandular stomach of 3 killed birds from the 80 ppm group showed degenerated and sometimes necrotic cells in the terminal secretory part of some deep proventricular glands. Infiltration of heterophils was also present in 2 cases.

In the pancreas of a female bird of the 5 ppm group, an adenocarcinoma of the exocrine pancreas was found.

No evidence of any microscopic change in the sections of the other organs was observed.

The results of the hematologic examinations of birds fed 0, 20, and 120 ppm HCB for 4 wk are given in Table 8. Two birds from the 120 ppm group died. Significantly decreased hemoglobin and hematocrit values occurred in the 120 ppm group. Serum GOT activity was significantly increased in both test groups, which can be associated with the liver damage found in the 90 days test.

Tissue HCB concentrations of birds fed 1 and 5 ppm are given in Table 9. Significantly higher brain levels were found in the males as compared with the females; liver residues were not significantly higher in the males.

TABLE 8

RESULTS OF THE HEMATOLOGIC EXAMINATIONS MADE IN FEMALE JAPANESE QUAIL FED HCB FOR 4 WEEKS[a]

Dietary conc (ppm)	Number of birds	Hemoglobin (g/100 ml)	Hematocrit (%)	Erythrocytes (10^6 mm^3)	SGOT (U/l)	
0	6	16.6 ± 2.1	49.3 ± 5.5	2.9 ± 0.3	[illegible]	[illegible]
20	6	13.7 ± 1.5	45.2 ± 3.4	2.8 ± 0.3	[illegible]	[illegible]
120	8	11.8 ± 2.3[b]	39.6 ± 7.1[b]	2.7 ± 0.5	[illegible]	[illegible]

[a] Mean values ± SD.
[b] $P \leq 0.05$.

TABLE 9

TISSUE HCB CONCENTRATIONS OF JAPANESE QUAIL FED HCB FOR 90 DAYS

1 ppm				5 ppm			
	Liver 7 *Females*		Brain 5 *Females*		Liver 7 *Females*		Brain [illegible] *Females*
	0.48		0.33		6.35		[illegible]
	0.35		0.42		9.41		[illegible]
	1.61		0.38		8.48		1.54
	0.50		0.22		4.86		[illegible]
	1.15		1.01		9.22		[illegible]
	0.60		—		5.53		[illegible]
	0.86		—		4.33		[illegible]
Mean	0.79	Mean	0.47	Mean	6.88	Mean	[illegible]
	3 *Males*		3 *Males*		3 *Males*		3 *Males*
	0.41		0.71		16.70		[illegible]
	1.58		2.88		4.88		[illegible]
	4.39		3.37		4.10		[illegible]
Mean	2.13	Mean	2.32[a]	Mean	8.56	Mean	[illegible]

[a] $P \leq 0.05$, on a one-tail significance level, between males and females.

DISCUSSION

Subacute feeding of 5 ppm HCB to Japanese quail resulted in increased liver [illegible] (Table 6), increased fecal coproporphyrin excretion (Table 2), and slight liver [illegible] (Table 7). Using these parameters, a no-effect level of 1 ppm in the dry food [illegible] established.

HCB did not influence the shell-thickness index, but reduced the volumes of the eggs from the 20 ppm and 80 ppm groups (Table 5). However, it must be considered that the quail is not a very suitable animal for such experiments; e.g., slight shell thinning in the quail can be produced only using a heavy DDT dosage (Bitman *et al.*, [illegible]

The spectrophotometric determination of the fecal coproporphyrin excretion appeared to be a very sensitive criterium (Table 2). Thus an increased excretion of porphyrins can possibly be used as a method to determine no-effect levels of other porphyrogenic chemicals, especially since enlarged excretion of coproporphyrin and protoporphyrin was already demonstrated after 10 days of HCB feeding. Granick (1963) attributes the porphyria to an increase in the activity of δ-aminolevulinic acid (ALA) synthetase, in chick embryo liver cells in vitro, as the main action of HCB. This increase in enzymatic activity resulted from a de novo synthesis of ALA synthetase.

HCB caused a remarkable liver enlargement (Table 6), which is possibly related to an induction of the drug enzyme system, or to the porphyrogenic action. Lottsfeldt and Labbe (1965) found a doubling in liver size within 3 days, after injections with the porphyrogenic chemical allylisopropylacetamide. The RNA per cell increased 44% in the porphyric liver while the DNA per cell remained unchanged. HCB-induced hypertrophy of the nucleolus was found in the present study (Table 7, Fig. 1). This hypertrophy is very likely due to an increase of RNA content (positive for pyronin), as is already discussed by Rouiller (1964) for thioacetamide and ethionine. Biochemical analysis of isolated nuclei revealed an increase in RNA content and in the RNA: protein nitrogen ratio.

Nuclear enlargement was also found in the present study (Table 7, Fig. 1). Christie and Le Page (1961) discussed the significance of the large nucleus phenomenon, found in dimethylnitrosamine administration, and consider it a rather common liver cell reaction to chronic toxic injury.

Pigment granules were found especially in the kidney tubular cells of birds fed 80 ppm HCB, and in the Kupffer cells of the liver of both test and control animals, although dose-related and most pronounced in the 80 ppm fed animals. These granules (Fig. 3a,b) showed a yellow-brownish fluorescence and stained with PAS, Sudan black, and Ziehl–Neelsen, which strongly indicate ceroid pigment. Lipofuscin deposits in the tubular cells of the kidney are also suggested by Campbell (1963) in his study with rats fed HCB. The pigment granules stained also positive with Perls, but Porta and Hartroft (1969) do not consider the iron an integral part of ceroid pigment, although it is often associated with ceroid pigment.

Decreased hemoglobin and hematocrit values (Table 8) are indicative for a microcytic anemia; the erythrophagocytosis in the spleen suggests an increased turnover rate of the red blood cells.

To elucidate the tremor, observed in birds from the 80 ppm group and also observed in prior studies using Japanese quail (Vos *et al.*, 1968) and rats (Ockner and Schmid, 1961; Campbell, 1963), a detailed study of the nervous system seems to be important, though Campbell (1963) did not find any histologic lesion in the central nervous system and the peripheral nerves.

The significantly higher brain residues found in the males as compared with the female birds (Table 9) can be explained by the excretion of HCB through the egg; high egg residues were found in a prior study (Vos *et al.*, 1968).

Not much information is available about the possible metabolic breakdown of HCB. Only Parke and Williams (1960) state that at least no ethereal sulfates, glucuronides, or mercapturic acids are formed after oral and subcutaneous administration of HCB to rabbits.

In this subacute study it is found that the no-effect level of HCB in Japanese quail was 1 ppm. The mean liver residue of the female birds in this group was 0.79 ppm, the mean liver residue in the 5 ppm group was 6.88 ppm (Table 9). Liver residues of 6 Japanese quail, that died after feeding of 100 ppm HCB, ranged from 85 to 720 ppm, mean 235 ppm (Vos *et al.*, 1968). Liver residues of 14 birds of prey: sparrow-hawk (*Accipiter nisus*), buzzard (*Buteo buteo*), and hooded crow (*Corvus cornix*), found in the field in The Netherlands during 1965–1968, ranged from 0.8 to 431 ppm, mean 45.5 ppm (Vos *et al.*, 1968). Liver residues of 20 birds of prey and owls: kestrel (*Falco tinnunculus*), buzzard (*Buteo buteo*), sparrow-hawk (*Accipiter nisus*) marsh harrier (*Circus aeruginosus*), barn owl (*Tyto alba*), long-eared owl (*Asio otus*), and crane (*Grus grus*), found in the field in The Netherlands in the winter of 1968–1969, ranged from 1.1–4.5 ppm, mean 48.2 ppm (Koeman *et al.*, 1969a).

It is concluded, from the residues found in wild birds when compared with the residues found in this study in Japanese quail, that the use of HCB as a seed dressing can have noxious, perhaps sometimes lethal, effects on birds of prey, when they have fed on seed-eating animals that are contaminated with HCB.

ACKNOWLEDGMENTS

The authors wish to thank Mr. J. H. Koeman for his support and helpful discussion, Miss C. A. P. M. Schnellen for technical assistance, and Mr. H. W. Antonisse for statistical analysis of the data. This study was supported, in part, by the Central Organization for Applied Scientific Research (T.N.O.).

REFERENCES

BITMAN, J., CECIL, H. C., HARRIS, S. J., and FRIES, G. F. (1969). DDT induces a decrease in eggshell calcium. *Nature (London)* **224**, 44–46.

CAM, C., and NIGOGOSYAN, G. (1963). Acquired toxic porphyria cutanea tarda due to hexachlorobenzene. *J. Amer. Med. Ass.* **183**, 88–91.

CAMPBELL, J. A. H. (1963). Pathological aspects of hexachlorobenzene feeding in rats. *S. Afr. J. Lab. Clin. Med.* **9**, 203–206.

CHRISTIE, G. S., and LE PAGE, R. N. (1961). Enlargement of liver cell nuclei: effect of dimethylnitrosamine on size and desoxyribosenucleic acid content. *Lab. Invest.* **10**, 729–743.

DAVIS, E. F., TUMA, B. L., and LEE, L. C. (1959). Handbook of Toxicology, (D. S. Dittmer ed.), Vol. 5: Fungicides, p. 19. Saunders, Philadelphia.

GRANICK, S. (1963). Induction of the synthesis of δ-aminolevulinic acid synthetase in liver parenchyma cells in culture by chemicals that induce acute porphyria. *J. Biol. Chem.* **238**, 2247–2249.

GRISHAM, J. W., and HARTROFT, W. S. (1961). Morphologic identification by electron microscopy of "oval" cells in experimental hepatic degeneration. *Lab. Invest.* **10**, 317–332.

KOEMAN, J. H., VINK, J. A. J. and DE GOEIJ, J. J. M., (1969a). Causes of mortality in birds of prey and owls in The Netherlands in the winter of 1968–1969. *Ardea* **57**, 67–76.

KOEMAN, J. H., TEN NOEVER DE BRAUW, M. C., and DE VOS, R. H. (1969b). Chlorinated biphenyls in fish, mussels and birds from the river Rhine and the Netherlands coastal area. *Nature (London)* **221**, 1126–1128.

LOTTSFELDT, F. I., and LABBE, R. F. (1965). Some cytologic changes of rat liver in experimental porphyria. *Proc. Soc. Exp. Biol. Med.* **119**, 226–229.

LUCAS, A. M., DENINGTON, E. M., COTTRAL, G. E., and BURMESTER, B. R. (1954). Predisposition of so-called normal lymphoid foci following inoculation with lymphoid tumor filtrate. I. Pancreas. *Poultry Sci.* **33**, 562–584.

OCKNER, R. K., and SCHMID
chlorobenzene intoxication.
PARKE, D. V., and WILLIAMS,
halogenobenzenes: (a) pent
trichlorobenzene. *Biochem.*
PORTA, E. A., and HARTROFT,
Academic Press, New York
RATCLIFFE, D. A. (1967). Decr
215, 208–210.
REITMAN, S., and FRANKEL, S.
glutamic oxaloacetic and gl
RIMINGTON, C. (1961). Quant
urine and faeces. Broadshe
may be obtained from Dr.
Barnstaple, Devon.
ROUILLER, C. (1964). *The Liv*
Vol. 2, pp. 349–352. Acade
VAN DER WAERDEN, B. L. (1957)
VOS, J. G., and KOEMAN, J. H
biphenyls in chickens with s
and tissue residues. *Toxicol.*
VOS, J. G., BREEMAN, H. A., a
chlorobenzene in wild birds a
Meded. Rijksfac. Landbouw
WIT, S. L. (1970). National In
communication.

OCKNER, R. K., and SCHMID, R. (1961). Acquired porphyria in man and rat due to hexachlorobenzene intoxication. *Nature (London)* **189**, 499.

PARKE, D. V., and WILLIAMS, R. T. (1960). 81. Studies in detoxication. The metabolism of halogenobenzenes: (a) penta- and hexa-chlorobenzenes. (b) further observations on 1:3:5-trichlorobenzene. *Biochem. J.* **74**, 5–9.

PORTA, E. A., and HARTROFT, W. S. (1969). *Pigments in Pathology* (M. Wolman, ed.), p. 210. Academic Press, New York.

RATCLIFFE, D. A. (1967). Decrease in eggshell weight in certain birds of prey. *Nature (London)* **215**, 208–210.

REITMAN, S., and FRANKEL, S. (1957). A colorimetric method for the determination of serum glutamic oxaloacetic and glutamic pyruvic transaminases. *Amer. J. Clin. Pathol.* **28**, 56–63.

RIMINGTON, C. (1961). Quantitative determination of porphobilinogen and porphyrins in urine and faeces. Broadsheet No. 36 of the Association of Clinical Pathologists. Copies may be obtained from Dr. R. B. H. Tierney, Pathology Laboratory, 75, Boutport Street, Barnstaple, Devon.

ROUILLER, C. (1964). *The Liver: Morphology, Biochemistry, Physiology* (C. Rouiller, ed.), Vol. 2, pp. 349–352. Academic Press, New York.

VAN DER WAERDEN, B. L. (1957). *Mathematische Statistik*, pp. 287–295. Springer, Berlin.

VOS, J. G., and KOEMAN, J. H. (1970). Comparative toxicologic study with polychlorinated biphenyls in chickens with special reference to porphyria, edema formation, liver necrosis, and tissue residues. *Toxicol. Appl. Pharmacol.* **17**, 656–668.

VOS, J. G., BREEMAN, H. A., and BENSCHOP, H. (1968). The occurrence of the fungicide hexachlorobenzene in wild birds and its toxicological importance. A preliminary communication. *Meded. Rijksfac. Landbouwwetensch. Gent* **33**, 1263–1269.

WIT, S. L. (1970). National Institute of Public Health, Utrecht, The Netherlands. Personal communication.