CANADIAN JOURNAL OF COMPARATIVE MEDICINE

REVUE CANADIENNE DE MÉDECINE COMPARÉE

LANL Reference

JANUARY 1976 JANVIER

VOLUME 40, NO. 1

0019

CONTENTS SUJETS

THE STRUCTURE OF PILI (FIMBRIAE) OF *Moraxella bovis*
C. F. Simpson F. H. White and T. S. Sandhu 1

EFFECT OF TRAUMA ON PLASMA GLUCAGON AND INSULIN CONCENTRATIONS IN SHEEP
R. P. Brockman and J. G. Manns 5

LEAD AND MERCURY RESIDUES IN KIDNEY AND LIVER OF CANADIAN SLAUGHTER ANIMALS
M. G. Prior 9

FUSARIOTOXICOSIS FROM BARLEY IN BRITISH COLUMBIA I. NATURAL OCCURRENCE AND DIAGNOSIS
J. A. Greenway and R. Puls 12

FUSARIOTOXICOSIS FROM BARLEY IN BRITISH COLUMBIA II. ANALYSIS AND TOXICITY OF SUSPECTED BARLEY
R. Puls and J. A. Greenway 16

THE INDIRECT HEMAGGLUTINATION TEST FOR THE DETECTION OF ANTIBODIES IN CATTLE NATURALLY INFECTED WITH MYCOPLASMAS
H. J. Cho, H. L. Ruhnke and E. V. Langford 20

MERCURY AND MINK I. THE USE OF MERCURY CONTAMINATED FISH AS A FOOD FOR RANCH MINK
G. Wobeser, N. O. Nielsen and B. Schiefer 30

MERCURY AND MINK II. EXPERIMENTAL METHYL MERCURY INTOXICATION
G. Wobeser, N. O. Nielsen and B. Schiefer 34

Contents continued overleaf — Suite des sujets au verso

Canada Post Postage paid Postes Canada Port payé

Third class Troisième classe

0-2

9205

Mercury and Mink II. Experimental Methyl Mercury Intoxication

G. Wobeser, N. O. Nielsen and B. Schiefer*

ABSTRACT

Adult female mink were fed rations containing 1.1, 1.8, 4.8, 8.3 and 15.0 ppm mercury as methyl mercury chloride over a 93 day period. Histopathological evidence of injury was present in all groups. Mink fed rations containing 1.8 to 15.0 ppm mercury developed clinical intoxication within the experimental period. The rapidity of onset of clinical intoxication was directly related to the mercury content of the ration. Mercury concentration in tissue of mink which died were similar, despite differences in mercury content of the diets and time of death. The average mercury concentration in the brain of mink which died was 11.9 ppm. The lesions of methyl mercury poisoning are described and criteria for diagnosis are discussed.

RÉSUMÉ

On a servi à des visons femelles adultes, durant 93 jours, des rations contenant respectivement 1.1, 1.8, 4.8, 8.3 et 15 ppm de chlorure de mercure méthylique. Des sujets de tous les groupes développèrent des lésions histologiques; ceux qui recevaient les rations contenant de 1.8 à 15 ppm de mercure développèrent une intoxication clinique, au cours de la période expérimentale. La rapidité de l'apparition des signes de l'intoxication s'avéra directement proportionnelle à la teneur des rations en mercure. La quantité de mercure décelée dans les tissus des visons qui moururent s'avéra sensiblement la même, indépendamment des différences dans la teneur en mercure des rations et du temps de la mort. La concentration moyenne de mercure retrouvée dans le cerveau des visons qui moururent s'élevait à 11.9 ppm. Les auteurs décrivent les lésions de l'empoisonnement par le chlorure de mercure méthylique et commentent les critères qu'ils utilisèrent pour le diagnostiquer.

INTRODUCTION

The reasons for studyng mercury poisoning in mink have been described in a previous report (35). The fish used as a ration for mink in that study contained a low level of mercury (0.44 ppm) and intoxication did not result during the experimental period. Fish with much higher concentrations of mercury in their tissue than those used in that study have been reported from Canadian waters so that the possibility of mercury poisoning in mink is real. The present experiment was designed to describe the pathology of methyl mercury poisoning in mink and to correlate clinical signs and pathological lesions to mercury intake, length of exposure and mercury concentrations in mink tissue as an aid in the diagnosis of possible field cases of intoxication.

*Department of Veterinary Pathology, Western College of Veterinary Medicine, University of Saskatchewan, Saskatoon, Saskatchewan S7N 0W0

Based on a thesis submitted by G. Wobeser in partial fulfilment of the requirements for the Ph.D. degree at the University of Saskatchewan.

Submitted March 14, 1975.

MATERIALS AND METHODS

Thirty adult female mink of the pearl color phase were assigned to one of six groups of five mink each. All mink were weighed and placed in individual wire cages. The mink were fed in slight excess once daily on the cage wire. Water was supplied *ad libitum.*

The mink were examined in the cages several times each day and periodically were removed from the cages individually and allowed to run about the room so that gait and behaviour could be more adequately assessed. Daily food consumption was recorded as normal, less than normal or absent.

A manufactured complete mink food[1] was used as the basal ration for all groups. The control group (group I) received this ration, while the principal groups received the same ration to which methyl mercury chloride[2] had been added at the concentrations shown below:

Group	Mercury (ppm)
II	1.1
III	1.8
IV	4.8
V	8.3
VI	15.0

These rations were mixed thoroughly with an electric mixer in a fume hood. The prepared rations were sealed in plastic containers and frozen until needed.

Two mink from each group were allowed to die of intoxication or were killed at the termination of the experiment (93 days) in the case of groups I and II. These mink were necropsied as soon after death as possible and tissues were collected for histopathological examinations as previously described (35). The brain of these animals was sectioned mid-sagitally and one half, together with portions of skeletal muscle, liver, kidney and a quantity of fur from the dorsal aspect of the body, were placed in individual plastic bags and frozen until analyzed for mercury.

The remaining three mink in each group were killed when showing obvious clinical signs (group III to VI) or at the termination of the experiment in the case of groups I and II. These animals were anaesthetized by the intraperitoneal injection of pentobarbitol sodium[3] and placed in dorsal recumbency. The thorax was opened by a mid-ventral incision, the pericardium was incised and the heart exposed. A 14 gauge 5 cm hypodermic needle was inserted into the left ventricle and positioned through the aortic valves so that the tip was present in the ascending aorta. An additional quantity of anaesthetic was then injected through this needle and an infusion apparatus was connected. Prior to the commencement of infusion the right ventricle was incised to allow exsanguination.

A solution composed of 210 ml of heparinized saline and 40 ml of 10% buffered formalin was infused until fluid leaving the right ventricle contained very little blood. The amount used varied from 120 to 180 ml. Following exsanguination, approximately 300 ml of 10% buffered formalin was infused. All solutions were delivered from a height of approximately 60 cm. Following infusion the brain and spinal cord, together with the Gasserian (semilunar) ganglia and portions of liver, kidney, spleen, mesenteric lymph node, stomach, duodenum, colon, lung and the sciatic nerves were immersed in 10% buffered formalin.

Specimens for histopathology were processed routinely, sectioned at 6μ and stained with hematoxylin and eosin (H&E). Luxol-fast blue stain for myelin, Holzer's stain for astrocytes and Bielschowsky's stain for axons as modified for paraffin sections were used selectively. Frozen sections of liver were stained with Oil Red O.

After fixation, one sciatic nerve from each mink was processed by the method of Walsh (34). The nerve fibers were separated by teasing and small groups of well separated fibers were mounted on slides in Farrant's medium[4].

Specimens for mercury analysis were processed and analyzed by the methods previously described (35).

[1]Pelsifood, Trouw of Canada Ltd., Seaforth, Ontario.

[2]Alpha Inorganics Inc., Beverly, Massachusetts.

[3]Nembutal, Abbott Laboratories Ltd., Montreal, Quebec.

[4]The British Drug Houses, Ltd., Toronto, Ontario.

RESULTS

Clinical Findings

All animals in Group I (control) remained clinically normal during the experiment period. In groups fed mercury the onset of clinical signs of intoxication was directly related to the mercury content of the diet (Table I). The only clinical sign noted in Group II (1.1 ppm mercury in feed) was a slight tendency of two of the animals to move more slowly than normal during the last three days of the experiment. No deaths occurred in this group.

Group III (1.8 ppm mercury in feed) — Animal III-1 was found dead on day 59, no premonitory signs other than partial anorexia had been noted. Slight posterior ataxia was observed in two mink (III-3 and 4) on day 60. By day 74, mink III-4 moved very slowly and when placed on a smooth tile floor the rear legs "splayed" to the side (Fig. 1). This mink appeared to be very inquisitive and totally unafraid of the investigator. No clinical signs other than decreased food intake were observed in animals III-2 and 5, until day 78. At that time slight posterior ataxia was observed. Animal III-5 died the following day. The remaining animals (III-4, 2 and 3) were killed on days 85, 91 and 93, respectively, at which time all animals exhibited marked posterior ataxia.

Group IV (4.8 ppm mercury in feed) — Animal IV-3 was found dead on day 26. Mild posterior ataxia, and a stilted "shuffling" gait was first noted in one mink on day 28 and by the following day this animal was markedly ataxic and a clonic convulsion of approximately one minute duration occurred when the animal was handled, this animal died the same day. Mild posterior ataxia and a shuffling gait with the tail raised was noted in two of the remaining animals on day 31 and in the final animal on day 32. The ataxia became more pronounced over the following three days and the animals would often fall to lateral recumbency while walking. One of these animals showed evidence of dysphonia, the vocalization being higher pitched and more irregular than normal.



Fig. 1. Mink, Group III, day 75. Splaying of hind legs.

Group V (8.3 ppm mercury in feed) — Clinical signs observed were similar to those in group IV. However, the onset was more rapid and the clinical course was shorter. Clonic convulsions of one to two minutes duration accompanied by chewing and salivation occurred in two mink when they were handled. Fine head tremors were observed in two mink. Vomition after eating and dysphonia, as previously described were noted in one mink each. Vision in these mink was difficult to assess because of the indifference of the animals toward their environment. However, the mink which survived for 26 days appeared to be blind at that time, making no attempt to avoid objects placed in its path.

Group VI (15.0 ppm mercury in feed) — Clinical signs were essentially as seen in group V. These animals ran an extremely short clinical course, progressing from an apparently normal state to one of lateral recumbency in only one to two days. Periodic, spontaneous, clonic convulsions accompanied by chewing and salivation were observed in three mink. Fine head tremors and pronounced coarse lateral movements of the head were also observed. These animals would often lie in ventral or lateral recumbency and make swimming motions with their limbs and circling was common in those that could walk.

Mink in all of the principal groups lost a considerable amount of weight over the course of the experiment (Table II).

Accumulation of Mercury in Tissue

The mercury concentration in tissues of the two mink which were allowed to die

TABLE I. Timing of Occurrence of Clinical Signs and Death in Mink Fed Rations Containing Various Amounts of Methyl Mercury Chloride (Hg)

Group	Hg in Ration (ppm)	Animal Number	Onset of Clinical Signs (days)		
			Anorexia	Ataxia	Death
II	1.1	1	—	—	93[a]
		2	—	—	93[b]
		3	—	—	93[a]
		4	—	—	93[b]
		5	—	—	93[a]
III	1.8	1	51	—	59
		2	64	78	91[b]
		3	51	60	93[b]
		4	51	60	85[b]
		5	59	78	79
IV	4.8	1	23	28	29
		2	23	31	36[b]
		3	—	—	26
		4	25	32	36[b]
		5	25	31	36[b]
V	8.3	1	20	21	23[b]
		2	16	18	19
		3	18	20	23
		4	17	21	26[b]
		5	19	20	22[b]
VI	15.0	1	—	—	18
		2	16	17	19
		3	18	18	20[b]
		4	17	18	20[b]
		5	18	18	19[b]

[a]Sacrificed, clinically normal
[b]Sacrificed, clinical signs of intoxication present

TABLE II. Average Weight Changes from Initial Weight to That at the Time of death

Group	Change in Weight (% of Initial Body Weight)	
	Mean	Range
I	− 2.5[a]	(+ 3.0 to −13.8)
II	−20.6	(−13.2 to −39.0)
III	−26.3	(−11.2 to −39.3)
IV	−12.3	(− 6.7 to −25.2)
V	−15.7	(−10.6 to −18.9)
VI	−18.8	(−14.7 to −25.0)

[a]Weight of four animals remained virtually stationary, one animal lost 13.8% of initial body weight

in groups III, IV, V and VI and the two mink killed without being infused with formalin in groups I and II are shown in Table III. In general the mercury concentrations in the tissues of mink which died were similar, despite differences in the mercury content of the diet and time to death. Mercury concentrations in brain and muscle tissue were rather similar and lower than those in liver and kidney of the same animal. The mercury content of the fur of mink in Groups V and VI was similar to that of the control group. The mink which survived longer (groups II, III and IV) had somewhat higher levels of mercury in their fur.

The mean concentration of mercury (ppm) in the tissues of mink which died were: brain 11.9, muscle 16.0, kidney 23.1, liver 24.3. The mercury concentrations in the tissues of mink in group II which showed only lethargy when sacrificed, were similar to and in some instances higher than those in individual mink which died.

Macroscopic Findings

Mink in the principal groups had less fat than those in group I. However, all mink had some remaining fat. The liver of all mink in groups III to VI and of two mink in group II were paler than normal with a variable yellow color. The digestive tract of mink which died and of most of those showing clinical signs when sacrificed was empty. A small amount of dark material

TABLE III. Mercury Concentration in the Tissues of Mink which Received Rations Containing Various Amounts of Methyl Mercury Chloride (Hg)

Group	Hg in Ration (ppm)	Animal Number	Days Fed Hg	Hg (ppm)				
				Liver	Kidney	Brain	Muscle	Fur
I	0.1	3[a]	93	0.7	1.0	0.1	0.3	1.1
		5[a]	93	0.2	0.5	0.1	0.1	0.7
II	1.1	3[b]	93	30.2	21.2	7.1	7.1	1.8
		5[b]	93	20.5	23.6	9.3	8.5	1.8
III	1.8	1[c]	59	21.3	26.7	4.1	4.9	—
		5[c]	79	21.3	17.9	12.2	—	2.3
IV	4.8	1[c]	29	23.0	26.7	12.3	20.5	1.7
		3[c]	26	18.1	17.9	8.6	7.8	1.7
V	8.3	2[c]	19	37.2	23.2	14.5	20.2	1.2
		3[c]	23	26.2	19.8	12.1	14.7	1.2
VI	15.0	1[c]	18	20.3	24.5	15.9	23.0	1.0
		2	19	27.3	28.3	15.4	21.0	1.4

[a]Sacrificed. clinically normal
[b]Sacrificed. animal somewhat lethargic
[c]Died

resembling blood was present in the stomach of one of the mink which died in each of groups V and VI. No source for this was detected.

Histological Findings

No remarkable lesions were observed in group I.

Group VI (15.0 ppm mercury in feed) — Nervous system: The severity of lesions was uniform within this group. Neuronal necrosis occurred throughout the brain but the most severely affected area was the occipital region of the cerebral cortex where there was extensive necrosis of neurons in the middle laminae, with laminae I, II and VI appearing relatively intact. Focal areas of neuronal necrosis involving all laminae were also present (Fig. 2). Necrotic neurons were shrunken, angular and had condensed eosinophilic cytoplasm and small pyknotic nuclei. Contraction of necrotic neurons gave the affected areas a somewhat fenestrated appearance. Proliferation and swelling of capillary endothelial cells and of glial cells, particularly elongated microglial cells, was prominent in the damaged areas. The most outstanding feature was extensive perivascular accumulation of cells resembling lymphocytes and histocytes about larger vessels throughout both the cerebral grey and white matter (Fig. 3).

Neuronal degeneration and necrosis, characterized by pyknosis of nuclei, were present in the granular layer of the cerebellum of all animals. This change was confined to the median and basal areas and most prominent in the lingula. All mink in this group had marked porosity of the white matter of the cerebellar peduncles, particularly in the superior and inferior cerebellar peduncles. This change appeared to be swelling and vacuolation of the myelin sheaths. Numerous swollen degenerating axons were evident in this area. Perivascular cellular accumulations similar to those in the cerebral cortex were present around many large vessels. Necrosis of neurons, gliosis, axonal degeneration and perivascular cellular accumulations were present in nuclei throughout the thalamus, hypothalamus, midbrain and in the fastigial and dentate nuclei. The basal ganglia appeared to be relatively unaffected. Neuronal necrosis with neuronophagia was found in the Gasserian ganglion of one mink.

Changes in the sciatic nerve were difficult to interpret in histological slides and were limited to local swelling and vacuolation of myelin. In teased preparations stained with osmium tetroxide there were individual fibres with disruption and contraction of the myelin sheath and formation of osmophilic ovoids near the nodes of Ranvier (Fig. 4). These changes were consistent along the length of individual fibres

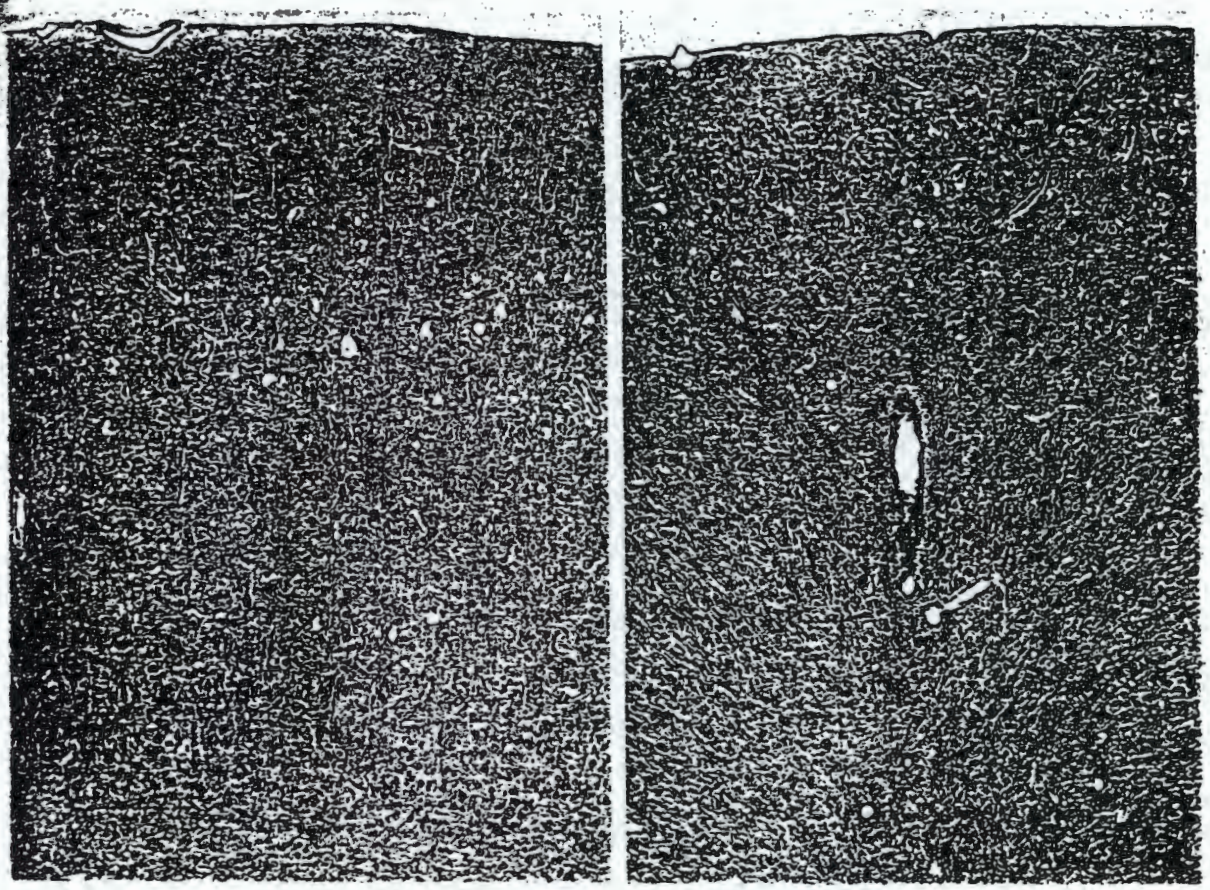

Fig. 2. Mink. Group VI, day 20. Occipital cortex. H and E. X75. Left: Laminar necrosis of neutrons in central laminae. Right: Diffuse necrosis of neurons in all laminae with perivascular mononuclear cell accumulation.

but were present in only a small percentage of nerve fibres.

Vacuolation of myelin was noted in foci in the dorsal columns of the spinal cord and a few lymphoid cells were present about vessels in these areas.

Other systems: The liver of all animals had extensive vacuolar degeneration. The epithelium of the proximal convoluted tubules of both control and principal mink in this experiment contained vacuoles. However, this vacuolation was most prominent in the mink in group VI. Within the spleens of these mink the character of cells in the Malpighian corpuscles differed from that seen in control animals in which the lymphocytes within the corpuscles were uniformly small, with dark basophilic nuclei. In animals in group VI the lymphocytes in the marginal and central areas of the follicles were larger with pale vesicular nuclei (Fig. 5).

Group V (8.3 ppm mercury in feed) — Nervous system: The character and distribution of lesions in this group were essentially the same as that seen in animals

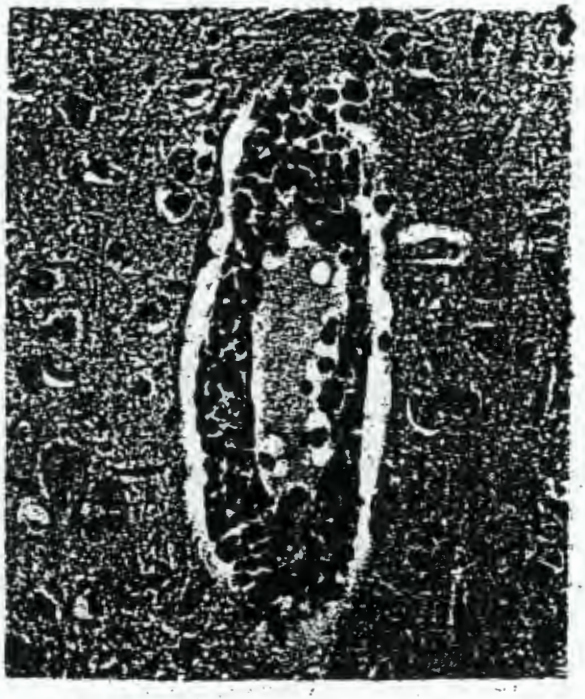

Fig. 3. Mink. Group VI, day 20. Cerebral cortex. Vessel with prominent perivascular lymphoid cell accumulation. H and E. X320.

Fig. 4. Mink. Group VI. Isolated nerve fibres from sciatic nerve. Degeneration and retraction of myelin with formation of osmophilic ovoids. Osmium tetroxide. X370.

in group VI. Prominent perivascular accumulations of lymphoid and histocytic cells were present about vessels in all areas of the cerebral cortex and also in areas of necrosis in the thalamus and hypothalamus. Degenerative changes in the cerebellar peduncles were present in all mink as was pyknosis of granular cell nuclei in the basal and medial areas of the cerebellum. The red, fastigial and dentate nuclei appeared to be more severely involved than other nuclei. The sciatic nerves had lesions similar to those of mink in group VI.

Other systems: Changes in liver, spleen and kidney were similar to those in group VI.

Group IV (4.8 ppm mercury in feed) — Nervous system: Lesions in animals in this group were similar in distribution to those in the prior two groups but were more variable in intensity. Neuronal necrosis and loss was evident in laminae III, IV and V of the occipital cortex of all mink. This was accompanied by microgliosis, astrocyte and capillary endothelial proliferation and axonal degeneration. Perivascular cellular accumulations similar to those previously described were present about cerebro-cortical vessels in three mink. Neuronal necrosis was present in other areas of the cerebral cortex but to a much lesser degree than in more acutely poisoned mink and occurred as scattered foci accompanied by glial cell proliferation. Degeneration of granular cells of the cerebellum was present in one mink in this group. The cerebellar peduncles had lesions similar to but less severe than those previously reported. A few necrotic neurons were detected in subcortical nuclei and in two mink neuronal necrosis with neuronophagia, gliosis, capillary endothelial proliferation and axonal degeneration were present in the red nucleus. A similar lesion was present in the nucleus of the lateral leminiscus in one mink. Very few fibres in the sciatic nerves of these mink showed degenerative changes.

Other systems: Vacuolar degeneration of the liver was present in two mink and changes in the spleen were similar to those in groups V and VI. The kidneys were unremarkable.

Group III (1.8 ppm mercury in feed) — Nervous system: Lesions in this group were similar to those in group IV. Perivascular accumulation of lymphoid and histiocytic cells was found around only one vessel in the cerebral cortex of one mink. Scattered pyknotic nuclei were found in the basal region of the granular cell layer of the cerebellum of one mink. Occasional necrotic neurons were present in subcortical nuclei. These were most prominent in the red, fastigial and dentate nuclei and in the nucleus of the lateral leminiscus (Fig. 6).

Other systems: Vacuolar degeneration of hepatocytes was present in the liver of one mink. The spleen of four of the animals had changes as previously described. The kidneys were unremarkable.

Group II (1.1 ppm mercury in feed) — Nervous system: Lesions in the cerebral cortex were limited to small foci of neuronal necrosis in laminae III and IV of the occipital cortex. A vessel in association with one of these foci in one mink had a single layer of surrounding lymphoid cells. Necrosis of neurons and astrocytosis was observed in the nucleus of the lateral leminiscus of two mink. In one mink a few vacuolated spaces with swollen axons were

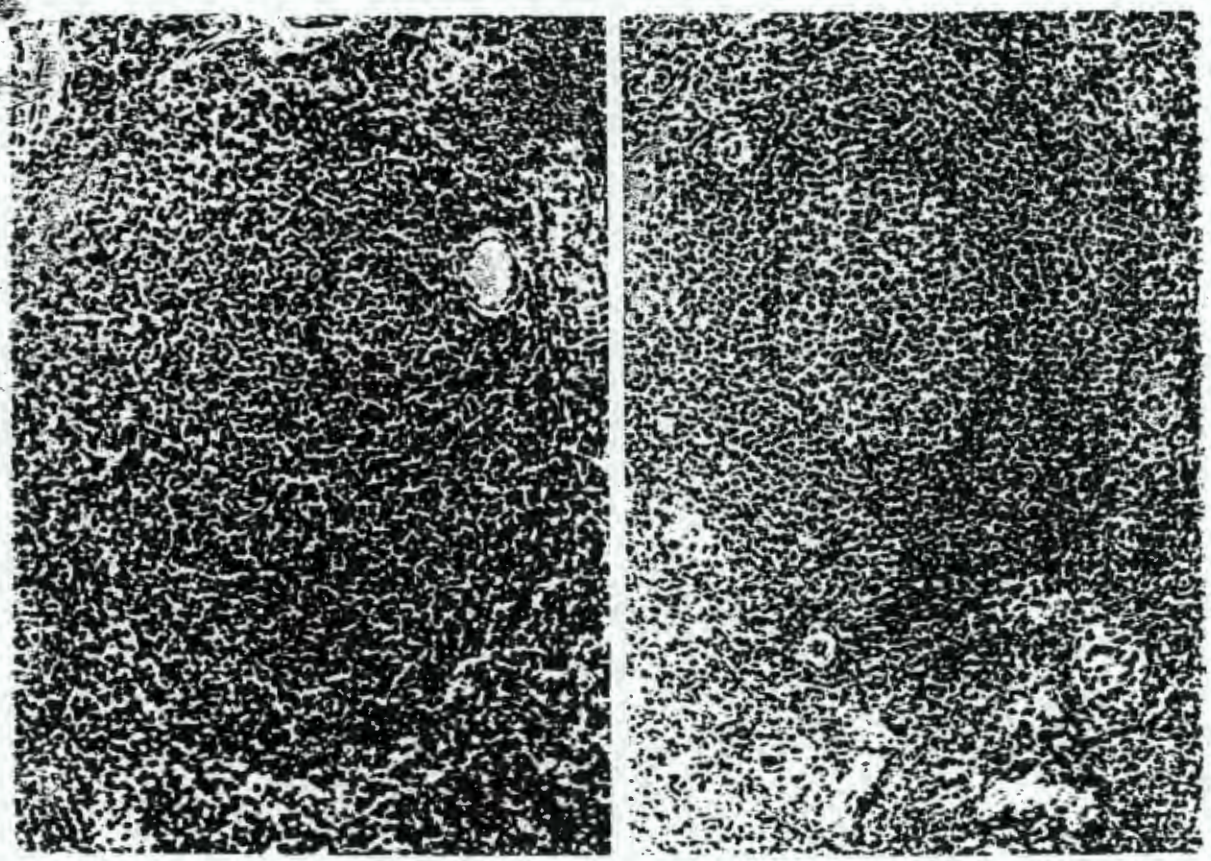

Fig. 5. Mink spleen. Malpighian corpuscle. H and E. X145. Left: Control animal. Right: Group VI, day 19. Depletion of small lymphocytes with replacement by large pale vesicular cells.

observed in the superior cerebellar peduncles and in another mink necrosis of neurons in the fastigial nucleus was observed. Retraction of myelin from about the axon was not observed in teased specimens of sciatic nerves from these mink, although the myelin occasionally had a granular appearance near the nodes of Ranvier.

Other systems: Liver and kidney from these mink were unremarkable. Three of the five mink showed cellular changes in the Malpighian corpuscles of the spleen, as described in other groups.

DISCUSSION

Mercury in the form of methyl mercury chloride administered in the diet was found to be toxic for mink. Rations containing from 1.8 to 15.0 ppm of mercury produced clinical evidence of toxicosis within the 93 day experimental period. A ration containing 1.1 ppm of mercury caused pathological alterations in the nervous system but did not produce obvious clinical evidence of intoxication within the experimental period.

The clinical signs of anorexia, weight loss, head tremor, ataxia and convulsions observed in mink in the present study were similar to those reported in alkyl mercury intoxication in other carnivores (1, 7, 14, 28, 30). The main behavioral changes noted in the present study were listlessness and indifference to the investigator. No clear assessment of the visual perception of the animals could be made.

The clinical course of poisoning in mink was shorter than that reported in other carnivores receiving rations with similar levels of mercury. Hanko *et al* (14) reported a latent period before the appearance of clinical signs of about 14 and 21 days in ferrets receiving rations containing 7 and 5 ppm mercury, respectively. These latent periods were similar to those of mink in group V which received a ration containing 8.3 ppm mercury and were shorter than the latent period of mink in

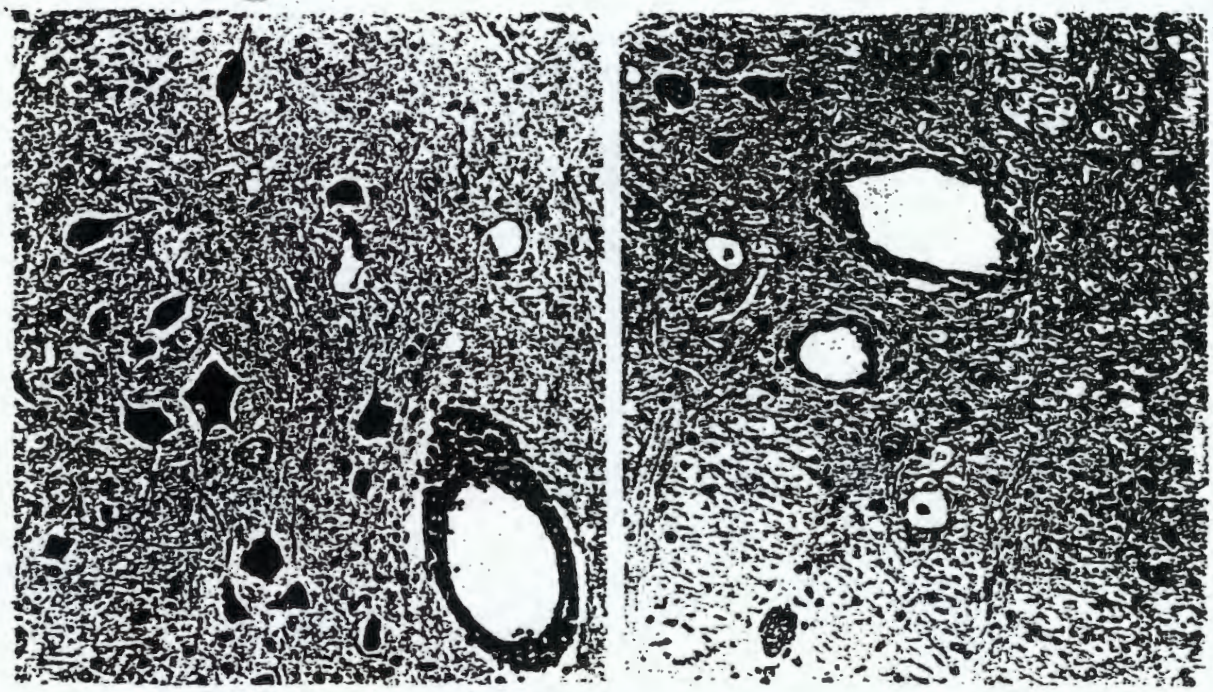

Fig. 6. Mink. Group III, day 91. Subcortical nuclei. H and E. X196. Neuronal necrosis, neuronophagia and perivascular lymphoid cell accumulation. Left: red nucleus. Right: nucleus raphis.

group IV which received food containing 4.8 ppm mercury. The survival period of the ferrets after the onset of clinical signs ranged from 21 to 37 days (14), while the longest survival of any mink receiving similar levels of mercury in the food was 13 days and the average survival after onset of clinical signs was only 6.4 days. The mean survival time was influenced by the sacrifice of animals when showing clinical signs. However, based on the short clinical course of animals which died, it is unlikely that this had a great effect.

The length of the latent period varied inversely with the mercury content of the diet. The occurrence of similar mercury levels in the tissues of mink from different groups at the time of death suggests that this period represented the time required for accumulation of toxic levels of mercury in tissue. Supporting this view is the fact that mercury concentrations in the tissues of mink in group II which may have been beginning to show clinical signs were similar to those in mink which died or had obvious clinical disease.

In view of the lesions present in the nervous system of animals in group II it could be expected that they would have developed distinct clinical signs had the experimental period been longer. The occurrence of clinically silent damage to the nervous system of alkyl mercury poisoned animals has been previously reported (13, 32) and undoubtedly reflects to some degree the difficulty in adequately assessing nervous function in experiment animals (13). It is also possible that the nervous system of these animals may have been functioning in a state of compensation for loss of parenchyma (Tryphonas, L., personal communication, 1968).

The clinical signs of anorexia, ataxia and convulsions as observed in these mink would not provide a reliable method for the diagnosis of mercury poisoning in field cases. Mink infected with viral diseases such as distemper and Aujeszky's disease or suffering from thiamine deficiency (Chastek paralysis) may show similar clinical signs (5,8).

The mercury concentration in the brains of mammals showing neurological symptoms of alkyl mercury poisoning has been found to range from 2 to 61 ppm (3). Berglund *et al* (3) concluded that, despite differences in species and widely different doses of methyl mercury used by authors to produce intoxication, the critical level in brain may be of the order of 10 ppm mercury for most mammals. The average mercury concentration in the brain of mink which died after showing neurological signs was 11.9 ppm. The level of 4.1 ppm mercury in the brain of one mink which died was somewhat anomalous, particularly

since a level more than twice as high was found in the brain of a mink which was exhibiting minimal signs (Table III). This may represent a difference in individual susceptibility to alkyl mercury poisoning.

The only previous report of methyl mercury poisoning in a mustelid was that of Hanko *et al* (14). Total mercury and methyl mercury concentrations in the brain of the four ferrets used in that study were reported but the results were difficult to interpret because methyl mercury content was higher than the total mercury content in three of the four animals. In one ferret the brain was found to contain 14 ppm mercury in the form of methyl mercury but only 7 ppm of total mercury. The mean total mercury concentration in the brains of the four ferrets at the time of death was approximately 26.8 ppm (7-39 ppm). This value was considerably higher than the average value for mink in the present study. This discrepancy may be related to interspecific differences in susceptibility. The ferrets survived an average of 46.9 days (14) compared to an average of 27.5 days for mink in groups IV and V which received diets containing similar levels of mercury. Thus there was ample opportunity for higher accumulation in the ferrets. Differences in the toxicity of the methyl mercury compounds used in the two studies might be a factor. However, the data reviewed by Berglund *et al* (3) and those of Albanus *et al* (1) and Charbonneau *et al* (7) suggest that there are no distinct differences in the toxicity of methyl mercury salts or between methyl mercury salts and methyl mercury in the form found in contaminated fish.

The distribution pattern of mercury among organs in mink was similar to that reported in most mammals (3) and was very similar to that reported in ferrets (14). The mercury concentration in the fur of mink in the principal groups did not differ widely from that of the controls. This finding is in direct contrast to reports of Hg concentration in the hair of poisoned humans (20) and cats (1, 20). Albanus *et al* (1) found that at least 20% of the total body mercury burden was present in the fur of cats poisoned over approximately a 90 day period. The explanation for this discrepancy may lie in the seasonal nature of fur growth in mink. The mink in this study had just become "prime", i.e. had just completed the growth of their winter fur, prior to the beginning of the study and little or no hair growth would have been expected during the period of the study.

The nervous system appears to be the "critical organ" in methyl mercury poisoning of mink as in other mammalian species (3). This term, critical organ, was defined by Berglund *et al* (3) as "the organ in the body whose function is especially affected by a chemical agent". The primary action of mercury seemed to be neurotoxicity and in general, the severity of this action was directly related to the mercury concentration in the ration and thus rate of intake. The concentration of mercury in the brain of mink which died in all groups was rather similar. However, the rate of accumulation of this "critical level" seemed to be important in determining the extent and distribution of neurological damage. In those groups (V and VI) receiving the highest levels of mercury in the ration, neuronal necrosis was evident throughout the cerebral cortex, subcortical nuclei and in the basal areas of the cerebellum and advanced degeneration of myelinated tracts in the cerebellar peduncle was evident. Those groups (II, III and IV) with a longer latent period and lower daily rate of mercury intake had lesions of a more localized nature, particularly involving the occipital region of the cerebral cortex and certain nuclear groups. Involvement of the granular layer of the cerebellum was much less common than in the more acutely poisoned group. It is unlikely that a state of equilibrium between intake and elimination was reached in any of these groups, so that all cases should be regarded as a form of acute or subacute poisoning in which mercury levels were increasing in tissues until the critical level for that organ was reached.

The occurrence of mononuclear cell accumulations in a perivascular location has been reported in alkyl mercury poisoned rats (17), cattle (12) and swine (19) and seems to have been a common finding in carnivores, having been reported in cats (1, 7, 29, 30, 31) and ferrets (14). The lesion would appear to be a response to neuronal damage rather than a primary lesion since it was not evident in some animals in the subacute groups which did have early neuronal degeneration and necrosis but was consistently present in animals more acutely poisoned and showing severe neuronal necrosis. These perivascular cuffs occurred in association with areas of necrosis.

Degenerative arteriopathy has been de-

scribed in alkyl mercury poisoning in several species (9, 15, 18, 19, 26 and Tryphonas, L., personal communication, 1968) but was not observed in mink in this study and has not been reported in either cats (1, 7, 28, 29) or ferrets (14).

The type and distribution of lesions seen in mink were similar to those reported in ferrets (14) and cats (1, 7, 14).

Vacuolation of hepatocytes was a common finding in mink receiving higher levels of mercury in the diet. Frozen sections of liver stained for lipids indicated that this was the result of accumulation of lipid within hepatocytes. The accumulation of lipid in the liver may have been due to a combination of increased metabolism of fat mobilized from depots as a result of anorexia and possibly a direct interference with normal fat metabolism in the liver. Interference with hepatic enzyme systems by methyl mercury has been demonstrated by Lucier *et al* (22). Fatty degeneration of the liver was observed in methyl mercury-poisoned ferrets (14) and has been a common finding in methyl mercury poisoning in many other species.

Hydropic degeneration of proximal tubular epithelium of the kidney has also been a common finding in methyl mercury poisoning and may be the result of demethylation of methyl mercury with the accumulation of inorganic mercury at this site resulting in enzyme inhibition (11).

Hanko *et al* (14) reported "hypoplasia" of the lymphatic tissue of the spleen in ferrets and Diamond and Sleight (9) described partial or complete loss of lymphoid follicles with reticulo-endothelial cell hyperplasia in the spleens of subchronically poisoned rats. The change in the mink appeared to be a lack of mature small lymphocytes and replacement by larger cells with more abundant cytoplasm and a less basophilic nucleus. Lukes (23) has classified changes in splenic white pulp seen in various states. That seen in the mink does not correspond exactly with any of the proposed classes but most closely resembles the class described as Type III-A (or activated with basophilic stem cells and large and small lymphocytes) (23). The clinical states associated with this type were graft rejection, infectious mononucleosis, *Herpes simplex* infection, post radiation and post bone marrow damage (23). Bone marrow from the mink was not examined. Bone marrow atrophy has been reported in both human and animal methyl mercury intoxication (25, 29, 31). The association of the post radiation clinical state with a change in lymphoid follicles similar to that seen in methyl mercury poisoning is very interesting. The loss of lymphocytes from the spleen after radiation (6) appears to be similar to that described by Diamond and Sleight (9) in methyl mercury poisoning. Methyl mercury may be somewhat radiomimetic in other ways, for example, both ionizing radiation and methyl mercury have been reported to selectively injure granular cells in the cerebellum (16), both may injure the blood barrier (9, 28) and both are genetically active (3) and may produce an increased incidence of chromosomal breakages (27). This aspect of the action of methyl mercury deserves further study.

In a previous study (35) we were unable to find any effect of feeding rations containing 50 and 75% respectively, of fish containing 0.44 ppm of mercury over a 145 day period. However, in the present study rations containing 1.1 ppm of mercury as methyl mercury chloride caused substantial weight loss and histopathological evidence of neural damage within 93 days. Freshwater fish form a large part of the diet of ranch mink in many areas of Canada and fish containing mercury levels as high as those in any of the experimental rations used have been reported from contaminated waters in Canada (2, 21). These findings would indicate that methyl mercury poisoning could very easily occur in areas in which mercury-contaminated fish are used as food for ranch mink. Mercury poisoning could also occur in wild piscivorous mammals such as the wild mink. There is no documented evidence of this having occurred. However, high levels of mercury have been reported in Swedish otter (*Lutra lutra*) and mink (33), and Fimreite (10) related that a trapper had discontinued trapping in the heavily contaminated Clay Lake area of northwestern Ontario, "because furbearers such as mink (*Mustela vison*) and otter (*Lutra canadensis*) had totally disappeared during the last years".

The differential diagnosis of mercury poisoning in mink must be based upon a combination of clinical, pathological and analytical findings. The clinical signs observed could easily be confused with those of a number of neurological diseases. The pathology of methyl mercury intoxication in mink is similar to that reported in other mammals. However, the presence of promi-

nent, perivascular cellular accumulations and the variability of lesions in relation to rate of intake of mercury could be mistaken as signs of a nonsuppurative encephalitis.

Brain and muscle appear to be the most suitable organs for analysis in methyl mercury intoxication and mercury concentrations greater than 5 ppm in association with appropriate clinical and pathological findings could be used as criteria for diagnosis.

ACKNOWLEDGMENTS

The technical assistance of Miss D. Guedo, Mr. E. Bueckert and Mr. J. Blackstock is gratefully acknowledged. Financial support was provided by Canada Mink Breeders Association.

G. Wobeser was a Fellow of the Medical Research Council of Canada.

REFERENCES

1. ALBANUS, L., L. FRANKENBURG, C. GRANT, U. VON HAARTMAN, A. JERNELOV, G. NORDBERG, M. RYDALV, A. SCHUTZ and S. SKERFVING. Toxicity for cats of methyl mercury in contaminated fish from Swedish lakes and of methylmercury hydroxide added to fish. Envir. Res. 5: 425-442. 1972.
2. BLIGH, E. G. Mercury and the contamination of freshwater fish. Manuscr. Rep. Ser. Fish. Res. Bd. Can. 1088: 1-23. 1970.
3. BERGLUND, F., M. BERLIN, G. BIRKE, U. VON EUHLER, L. FRIBERG, B. HOLMSTEDT, E. JONSON, C. RAMEL, S. SKERFVING, A. SWENSSON and S. TEJNING. Methyl mercury in fish. A toxicologic-epidemiologic evaluation of risks. Report of an expert group. Nord. hyg. Tidskr. supp. 4: 1-364. 1971.
4. BRIGHTMAN, M. W., I. KLATZO, Y. OLSSON and T. S. REESE. The blood-brain barrier to proteins under normal and pathological conditions. J. neurol. Sci. 10: 215-239. 1970.
5. BUDD, J., T. J. PRIDHAM and L. H. A. KARSTAD. Common diseases of fur bearing animals. I. Diseases of mink. Can. vet. J. 7: 25-31. 1966.
6. CASARETT, A. P. Radiation Biology. Englewood Cliffs, New Jersey: Prentice-Hall, Inc. 1968.
7. CHARBONNEAU, S. M., I. C. MUNRO, E. A. NERA, R. F. WILLIES, T. KUIPER-GOODMAN, F. IVERSON, C. A. MOODIE, D. R. STOLTA, F. A. J. ARMSTRONG, J. F. UTHE and H. C. GRICE. Subacute toxicity of methylmercury in the adult cat. Toxic. appl. Pharmac. 27: 569-581. 1974.
8. CHRISTODOULOU, T., E. TSIROYIANNIS, O. PAPADOPOLOULOS and T. TSANGARIS. An outbreak of Aujeszky's disease in minks. Cornell Vet. 60: 65-73. 1970.
9. DIAMOND, S. S. and S. D. SLEIGHT. Acute and subchronic methyl mercury toxicosis in the rat. Toxic. appl. Pharmac. 23: 197-207. 1972.
10. FIMREITE, N. and L. M. REYNOLDS. Mercury contamination of fish in northwestern Ontario. J. Wildl. Mgmt 37: 62-68. 1973.
11. FOWLER, B. A. Ultrastructural evidence for nephropathy induced by long-term exposure to small amounts of methyl mercury. Science 175: 780-781. 1972.
12. FUJIMOTO, Y., K. OSHIMA, H. SATOH and Y. OHTA. Pathological studies on mercury poisoning in cattle. Jap. J. vet. Res. 4: 17-32. 1956.
13. GRANT, C. A. Pathology of experimental methyl mercury intoxication: Some problems of exposure and response. IVth Rochester International Conference on Environmental Toxicity, Proc. Rochester, New York, June 17-19. 1971.
14. HANKO, E., K. ERNE, H. WANNTORP and K. BORG. Poisoning in ferrets by tissues of alkyl mercury-fed chickens. Acta. vet. scand. 11: 268-282. 1970.
15. HAY, W. J., A. J. RICHARDS, W. H. McMENEMY and J. N. CUMINGS. Organic mercurial encephalopathy. J. Neurol. Neurosurg. Psychiat. 26: 192-202. 1963.
16. HERNDON, R. M. Thiophen induced granule cell necrosis in the rat cerebellum. An electron microscopic study. Expl Brain Res. 6: 49-68. 1968.
17. HUNTER, D., R. R. BOMFORD and D. S. RUSSEL. Poisoning by methyl mercury compounds. Q. J. Med. 33: 193-213. 1940.
18. JUBB, K. V. F. and P. C. KENNEDY. Pathology of Domestic Animals. Volume 2. 2nd Ed. pp. 391-393. London: Academic Press. 1970.
19. KAHRS, R. F. Chronic mercurial poisoning in swine. A case report of an outbreak with some epidemiological characteristics of hog cholera. Cornell Vet. 58: 67-75. 1968.
20. KITAMURA, S. Determination on mercury content in bodies of inhabitants, cets, fishes, and shell in Minamata district and mud of Minamata Bay. In Minamata Disease. M. Kutsuna, Editor. pp. 257-266. Study group of Minamata disease, Kumamoto University, Japan. 1968.
21. LOCKHART, W. L., J. F. UTHE, A. R. KENNEDY, and P. M. MEHRLE. Methyl mercury in northern pike (Esox lucius): distribution, elimination, and some biochemical characteristics of contaminated fish. J. Fish. Res. Bd. Can. 29: 1519-1523. 1972.
22. LUCIER, G., O. McDANIEL, P. BRUBAKER and R. KLEIN. Effects of methylmercury hydroxide on rat liver microsomal enzymes. Chem. biol. Interactions 4: 265-280. 1971.
23. LUKES, R. J. The pathology of the white pulp of the spleen. In The Spleen. K. Lennert and D. Harms, Editors. pp. 130-138. Berlin: Springer-Verlag. 1970.
24. MIYAKAWA, T., M. DESHIMARU, S. SUMIYOSHI, A. TERAOKA, N. UDO, E. HATTORI and S. TATETSU. Experimental organic mercury poisoning: Pathological changes in peripheral nerves. Acta neuropath. 15: 45-55. 1970.
25. MORIKAWA, N. Pathological studies on organic mercury poisoning II. Experimental production of congenital cerebellar atrophy by bisethylmercuric sulfide in cats. Kumamoto med. J. 14: 87-93. 1961.
26. PRICK, J. J. G., A. E. H. SONNEN and J. L. SLOOFF. Organic mercury poisoning II. Proceedings, Koninklijke Nederlandse Akademie van Wetenschappen 70: 170-186. 1967.
27. SKERFVING, S., A. HANSSON and J. LINDSTEN. Chromosome breakage in human subjects exposed to methyl mercury through fish consumption. Archs envir. Hlth 21: 133-139. 1970.
28. STEINWALL, O. and Y. OLSSON. Impairment of the blood-brain barrier in mercury poisoning. Acta neurol. scand. 45: 351-361. 1969.
29. TAKEUCHI, T. Pathology of Minamata disease. In Minamata Disease. M. Kutsuna, Editor. pp. 141-228. Study group of Minamata disease. Kumamoto University, Japan. 1968.
30. TAKEUCHI, T. Experiments with organic mercury, particularly with methyl mercury compounds: similarities between experimental poisoning and Minamata disease. In Minamata Disease. M. Kutsuna, Editor. pp. 229-252. Study Group of Minamata Disease. Kumamoto University, Japan. 1968.
31. TAKEUCHI. T., N. MORIKAWA, H. MATSUMOTO and Y. SHIRAISHI. A pathological study of Minamata disease in Japan. Acta neuropath. 2: 40-57. 1962.
32. TRYPHONAS, L. and N. O. NIELSEN. Pathology of chronic alkylmercurial poisoning in swine. Am. J. vet. Res. 34: 379-392. 1973.
33. VOSTAL, J. Transport and transformation of mercury in nature and possible routes of exposure. In Mercury in the Environment. L. Friberg and J. Vostal, Editors. pp. 15-28. Cleveland, Ohio: CRC Press. 1972.
34. WALSH, J. C. Gold neuropathy. Neurology, Minneapolis 20: 455-458. 1970.
35. WOBESER, G., N. O. NIELSEN and B. SCHIEFER. Mercury and mink I. Mercury contaminated fish as food for ranch mink. Can. J. comp. Med. 40: 30-33. 1976.