oxication. *J. Pediatr.*

malian Physiology, p.

on (Fe, Sr, Pb) in the

ınd iron against some

ıse: Severe and mild
222.
suckling rat and its
6:266–278.
ntent of hair. *Arch.*

:hropoietic factor on

'city by low dietary

:ontent and toxicity

23:83–100.

ved March 10, 1977
:pted July 27, 1977

9/15/1977 Rel 0517

HISTOPATHOLOGIC EFFECTS OF DIETARY CADMIUM ON KIDNEYS AND TESTES OF MALLARD DUCKS

Donald H. White

U.S. Fish and Wildlife Service, Patuxent Wildlife Research Center, Gulf Coast Field Station, Victoria, Texas

Mack T. Finley

U.S. Fish and Wildlife Service, Patuxent Wildlife Research Center, Laurel, Maryland

John F. Ferrell

Experimental Pathology Laboratories, Inc., Herndon, Virginia

Mallard ducks fed 2, 20, or 200 ppm cadmium chloride were sacrificed at 30, 60, and 90 d. No mortality occurred during the study and body weights remained unchanged. Kidney weights of the 200-ppm group were significantly greater after 60 and 90 d than those of controls; also, testis weights were significantly lower after 90 d. Kidneys of ducks fed 2 and 20 ppm cadmium were relatively unaffected; however, slight to severe kidney lesions were found in the 200-ppm group after 60 d of treatment. No significant lesions were found in mallard testes after feeding 2 ppm cadmium in the diet, and only a few birds in the 20-ppm group showed slight to moderate gonad alterations. After 90 d of treatment, however, testes of males fed 200 ppm had atrophied and the spermatogenic process had ceased. This study should provide important information for the interpretation of cadmium levels found in kidneys and testes of wild ducks.

INTRODUCTION

Cadmium toxicity has been shown experimentally in several animal groups. Lesions were produced in the testes of brook trout (*Salvelinus fontinalis*) exposed to water containing 10 and 25 ppb cadmium (Sangalong and O'Halloran, 1973). Severe bone lesions occurred in young rats fed cadmium in their diets (Yoshiki et al., 1975) and sublethal injections of cadmium into rats and mice led to acute destruction of the testes

We thank R. Dyrland and P. Kramer for technical assistance and C. Glenn for typing the manuscript. G. Heinz and J. Patton provided critical reviews of the manuscript.

M. T. Finley's present address is U.S. Fish and Wildlife Service, Fish-Pesticide Research Laboratory, Route 1, Columbia, Missouri.

Requests for reprints should be sent to Donald H. White, U.S. Fish and Wildlife Service, Patuxent Wildlife Research Center, Gulf Coast Field Station, P. O. Box 2506, Victoria, Texas 77901.

Journal of Toxicology and Environmental Health, 4:551–558, 1978
Copyright © 1978 by Hemisphere Publishing Corporation
0098–4108/78/0404–0551$2.25

9236

(Parizek, 1957; Kar and Das, 1960; Nordberg, 1971). Dietary administration of cadmium to young Japanese quail (*Coturnix coturnix japonica*) produced adverse effects in the testis, kidney, liver, heart, and esophagus (Richardson et al., 1974).

Although little information is available concerning the effects on waterfowl of cadmium exposure through food chains, cadmium has been detected in moderate amounts ($\leqslant 10$ ppm) in kidneys and livers of canvasbacks (*Aythya valisineria*) from the Chesapeake Bay (D. H. White and R. C. Stendell, unpublished data). Since canvasbacks are declining in numbers, it seemed appropriate to investigate the effects of dietary cadmium on ducks.

We conducted a chronic feeding study with mallards (*Anas platyrhynchos*), using levels of cadmium ranging from those that might be obtained by wild ducks through the food chain to somewhat higher levels, in the hope of showing a dose-response relationship. We examined the uptake and distribution of cadmium in blood, brain, muscle, gonad, liver, and kidney at various intervals and performed a histopathologic evaluation on sections of kidney and testis. In this paper we present the findings of the latter study.

METHODS

Fifty-five pairs (one male, one female) of first-year adult mallards obtained from breeding stock at the Patuxent Wildlife Research Center were randomly assigned to 90 X 90 X 60 cm vinyl wire cages supplied with running water. A long-day light cycle (14 L:10 D) was maintained throughout the study. After a 3-wk equilibration period, the ducks were fed *ad libitum* for 90 d with commercial duck breeder mash coated with either 2, 20, or 200 ppm (wet weight) cadmium as cadmium chloride dissolved in propylene glycol. Propylene glycol alone was mixed into the control diet. Three feed samples from each treatment group were taken at intervals throughout the study and frozen for cadmium analysis. Groups treated with cadmium consisted of 15 pairs each; the control group consisted of 10 pairs. Food intake per pair was estimated during the study on a daily basis.

After 30, 60, and 90 d random samples of 5 pairs from each treatment group were weighed, bled, and sacrificed (controls were sacrificed at 30 and 90 d only). Birds were necropsied and certain tissues saved for cadmium analysis. One kidney from each male and female and one testis from each male was placed in Bouin's solution for 3 d and then transferred to 10% buffered neutral Formalin.

The tissues were prepared and examined for lesions at the Experimental Pathology Laboratories, Inc., Herndon, Virginia. Tissues were embedded in paraffin, sectioned, and stained with hematoxylin and eosin before microscopic examination.

etary administra-
turnix japonica)
, and esophagus

the effects on
dmium has been
s and livers of
y (D. H. White
are declining in
ects of dietary

mallards (*Anas*
e that might be
at higher levels,
examined the
le, gonad, liver,
ogic evaluation
the findings of

adult mallards
esearch Center
supplied with
as maintained
ne ducks were
h coated with
nium chloride
ixed into the
were taken at
alysis. Groups
control group
ing the study

ich treatment
rificed at 30
es saved for
nd one testis
d and then

the Experi-
Tissues were
in and eosin

The cadmium analyses were conducted at the Environmental Trace Substances Research Center, Columbia, Missouri. A portion of each sample was ashed with a nitric acid and perchloric acid mixture, digested in an acidic solution, and assayed on a Perkin-Elmer model 303 atomic absorption spectrophotometer. The limit of quantitation was 0.005 ppm on a wet-weight basis.

RESULTS

Analyses of the feed samples for cadmium yielded means of 0.08, 1.6, 15.2, and 210 ppm cadmium (wet weight) for the control, 2-, 20-, and 200-ppm groups, respectively. Ducks consumed an average of 110 g of food daily for the 90-d treatment period and maintained body weights averaging 1153 g. Food consumption and body weights did not differ significantly among treatment groups ($p > 0.05$, analysis of variance).

No birds died during the study, and necropsy revealed that the birds were in good flesh and most contained fat deposits. There was no difference in liver weights among treatment groups. Kidney weights relative to body weight in the 200-ppm group were significantly greater ($p < 0.01$, *t*-test) at 60 and 90 d than those in controls (5.7 ± 0.2 versus 3.6 ± 0.3). Testis weights relative to body weight in the 200-ppm group were significantly less ($p < 0.05$) at 90 d than those in controls (2.3 ± 1.2 versus 7.3 ± 1.8).

A summary of the histopathologic alterations found in the kidney and testis of mallard ducks fed dietary cadmium is presented in Table 1. The alterations were classified according to the severity of the condition. No significant pathological alterations were present in kidneys or testes from the 20 control ducks; however, alterations were present in sections of kidney and testis from some of the ducks fed cadmium. In the kidney, cadmium caused degeneration of the renal tubules, which in some cases had progressed to the stage of actual necrosis of the tubular epithelium (Fig. 1); there usually was an associated interstitial inflammatory process. The kidney lesions were related to the concentration of dietary cadmium and to the period of treatment. Birds in the 200-ppm group had a greater incidence of kidney lesions than those in the other treatment groups, and the lesions were more frequent at 60 and 90 d than at 30 d. All 10 kidneys of ducks in the 200-ppm group showed slight to severe interstitial nephritis and tubular degeneration after 60 and 90 d (Table 1). Slight to moderate tubular necrosis was evident in 7 of 10 animals in the 200-ppm group after 60 d, and 7 of 10 showed slight to severe alterations after 90 d. Kidneys of ducks fed 2 and 20 ppm dietary cadmium were relatively unaffected; slight tubular degeneration was present in 1 bird of the 20-ppm group but no tubular necrosis occurred in either group (Table 1).

A range of changes was noted in testicular sections from both control and test ducks. In one control bird and two test birds spermatogenesis

TABLE 1. Histopathology Incidence Table for Mallards Fed either 0, 2, 20, or 200 ppm Dietary Cadmium

Alteration and group	No. of birds in group with condition								
	30 d[a]			60 d			90 d		
	Slight[b]	Moderate	Severe	Slight	Moderate	Severe	Slight	Moderate	Severe
				Kidney[c]					
Interstitial nephritis									
Control	0	0	0		–[d]		0	0	0
2 ppm	2	0	0	1	0	0	1	0	0
20 ppm	2	0	0	1	0	0	1	1	0
200 ppm	3	0	0	3	5	2	2	4	4
Tubular degeneration									
Control	0	0	0		–[d]		0	0	0
2 ppm	0	0	0	0	0	0	0	0	0
20 ppm	0	0	0	0	0	0	1	0	0
200 ppm	2	0	0	3	3	4	1	3	6
Tubular necrosis									
Control	0	0	0		–[d]		0	0	0
2 ppm	0	0	0	0	0	0	0	0	0
20 ppm	0	0	0	0	0	0	0	0	0
200 ppm	0	0	0	1	6	0	1	4	2
				Testis[e]					
Interstitial orchitis									
Control	0	0	0		–[d]		0	0	0
2 ppm	0	0	0	0	0	0	0	0	0
20 ppm	1	0	0	0	0	0	0	0	0
200 ppm	0	0	0	0	0	0	1	0	0
Epididymitis									
Control	0	0	0		–[d]		0	0	0
2 ppm	0	0	0	0	0	0	0	0	0
20 ppm	0	0	0	1	0	0	0	0	0
200 ppm	0	0	0	0	0	0	0	0	0
Aspermatogenesis induced									
Control	0	0	0		–[d]		0	0	0
2 ppm	0	0	0	0	0	0	0	0	0
20 ppm	0	0	0	0	1	0	0	1	0
200 ppm	0	0	0	1	0	1	0	0	3

[a] Sacrifice interval.
[b] Degree of alteration.
[c] $n = 10$ (5 males and 5 females).
[d] Controls were sacrificed at 30 and 90 d only.
[e] $n = 5$ males.

0, or 200 ppm Dietary		
	90 d	
t	Moderate	Severe
	0	0
	0	0
	1	0
	4	4
	0	0
	0	0
	0	0
	3	6
	0	0
	0	0
	0	0
	4	2
	0	0
	0	0
	0	0
	0	0
	0	0
	0	0
	0	0
	0	0
	0	0
	0	0
	1	0
	0	3

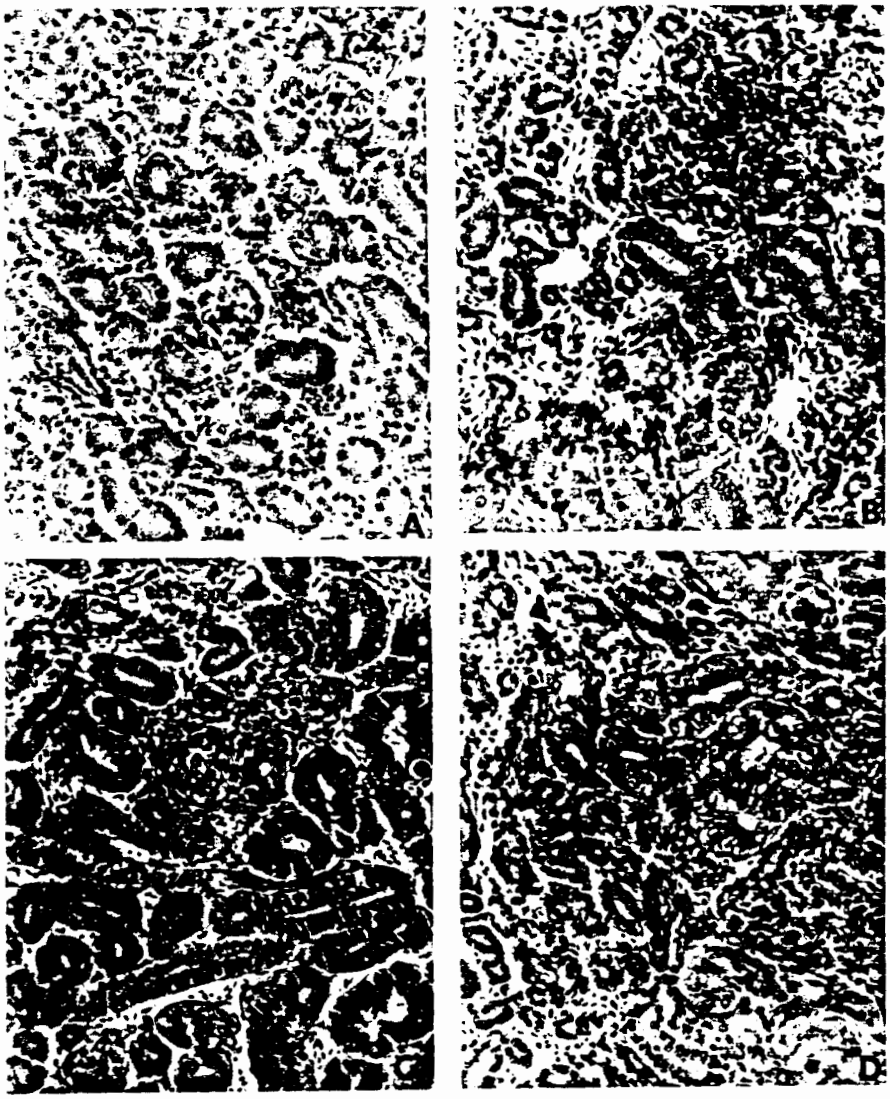

FIGURE 1. Pathological alterations in duck kidneys. (A) Normal, (B) slight tubular changes and mononuclear inflammatory cells, (C) moderate tubular degeneration, and (D) severe tubular degeneration.

progressed normally until the primary spermatocyte stage, then ceased. We considered this form of aspermatogenesis compatible with seasonal or cyclic changes. In some test birds fed 20 ppm cadmium there was a slight or moderate effect; there were a few primary spermatocytes but no mature spermatozoa (Fig. 2). The spermatogenic process appeared to have ceased.

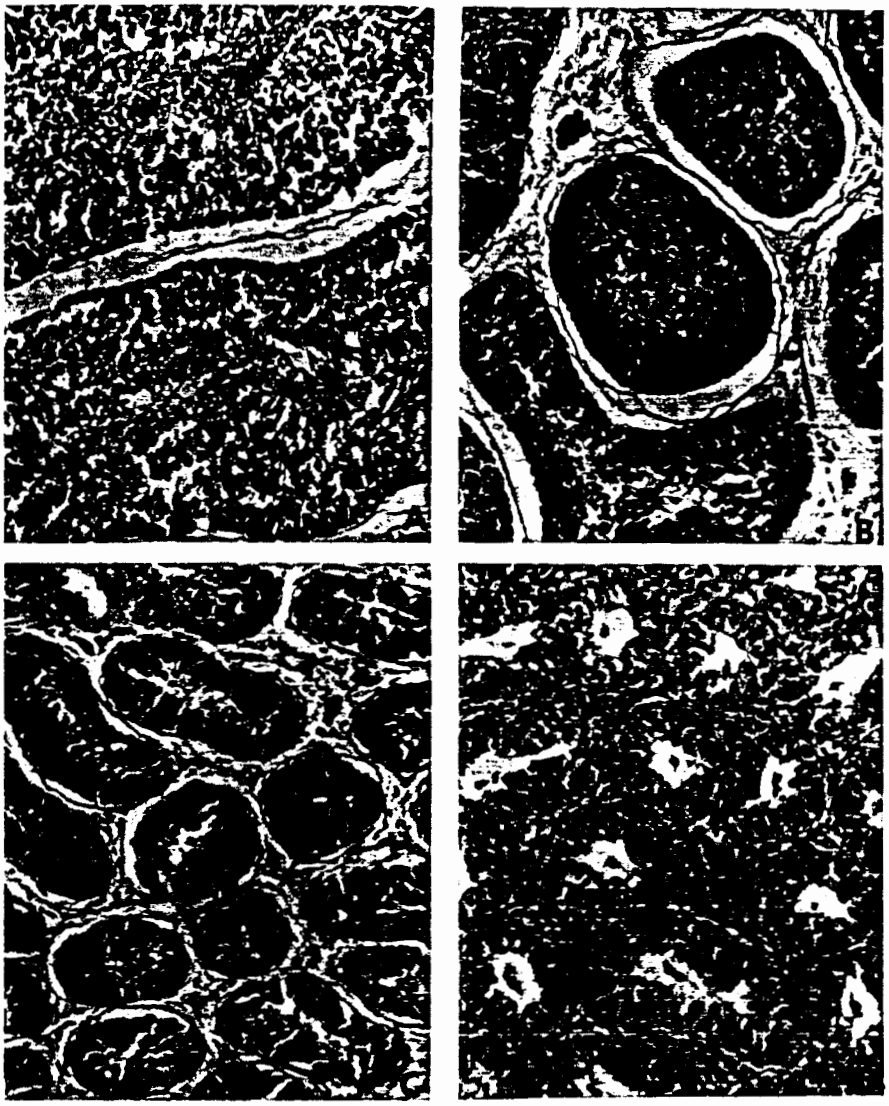

FIGURE 2. Pathological alterations in duck testis. (A) Normal testis with mature spermatozoa, (B) slight aspermatogenesis, (C) moderate aspermatogenesis, and (D) marked aspermatogenesis.

A more prominent effect was evident in certain testes of drakes fed 200 ppm dietary cadmium (Fig. 2). In these birds there were essentially only spermatogonia with no further evidence of spermatogenic activity, and the testes had atrophied. One of 5 birds exhibited this condition after 60 d of treatment and 3 of 5 birds after 90 d (Table 1). Levels of cadmium in the testes of these birds were 5.1, 14.4, 15.9, and 20.0 ppm,

ermatozoa, (B)
nesis.

drakes fed
essentially
ic activity,
lition after
Levels of
20.0 ppm,

respectively. No other testes from drakes in the study accumulated levels of cadmium this high. Aspermatogenesis was not present in controls or the group fed 2 ppm.

Mean concentrations of cadmium in kidneys and testes at each sacrifice interval are shown in Table 2. The averages in kidneys represent levels in both males and females since differences ($p > 0.05$, t-test) were not detected between sexes. A definite treatment response is evident among most groups at each interval. Also, residues increased with the number of days the birds were fed treated food, except in testes of the 2-ppm group and in kidneys of the 200-ppm group. Cadmium residues in kidneys and testes of control birds did not differ significantly ($p > 0.05$) throughout the study. Highly significant correlations were found between cadmium residues in kidneys and testes at each sacrifice interval ($p < 0.01$, mean r value = 0.87).

DISCUSSION

It appears that considerable accumulation of dietary cadmium in the adult mallard kidney over an extended period is necessary to produce kidney damage. Diets containing 2 and 20 ppm cadmium did not cause appreciable renal damage; however, the kidneys of all birds fed 200 ppm exhibited slight to severe interstitial nephritis, tubular degeneration, and tubular necrosis after 60 and 90 d of treatment. In addition, kidney weights increased significantly at both of these sacrifice periods. Richardson et al. (1974) found few kidney lesions attributable to ingestion of 75 mg/kg cadmium in the diet for 6 wk in young Japanese quail. Kidneys of young chickens fed 700 ppm dietary cadmium for 20 d

TABLE 2. Residues in Kidneys and Testes of Mallards Fed 2, 20, and 200 ppm Cadmium Chloride

		Residue (ppm wet weight)[a]		
Tissue	Group	30 d	60 d	90 d
Kidney[b]	Control	0.55 ± 0.09	–[c]	0.46 ± 0.10
	2 ppm	1.54 ± 0.03	2.90 ± 0.61	4.63 ± 1.02
	20 ppm	13.39 ± 2.70	45.77 ± 4.50	54.33 ± 6.30
	200 ppm	88.13 ± 10.74	134.20 ± 4.74	77.22 ± 4.19
Testis[d]	Control	0.01 ± 0.01	–[c]	0.03 ± 0.02
	2 ppm	0.01 ± 0.00	0.02 ± 0.01	0.02 ± 0.00
	20 ppm	0.04 ± 0.01	0.28 ± 0.15	0.72 ± 0.49
	200 ppm	0.43 ± 0.06	4.19 ± 2.98	8.47 ± 3.73

[a] Mean ± SE.
[b] $n = 10$ (5 males and 5 females).
[c] No analysis.
[d] $n = 5$ males.

increased in size by 50% relative to body weight and accumulated residues averaging 325 ppm dry weight (about 90 ppm wet weight) (Pritzl et al., 1974).

In this study, administration of 2 ppm dietary cadmium produced no significant lesions in mallard testes, but the 20-ppm diet appeared to induce slight to moderate alterations in testes of some birds. Conversely, the 200-ppm diet produced severe lesions, but only after an extended period on treatment. Dietary cadmium (75 ppm) induced testicular hypoplasia during the first 4 wk of life in young Japanese quail but cadmium residues were not detected in testes (Richardson et al., 1974); the spermatogenic cells failed to mature at 4 wk of age but maturation was normal at 6 wk.

In some cases, there were significant kidney lesions with no apparent effect on the testis, as well as examples of induced aspermatogenesis in which the kidney appeared normal; however, birds exhibiting severe testicular effects also had significant kidney alterations.

Our data should be useful in interpreting the possible adverse effects of cadmium in kidneys and testes of wild ducks, although caution should be exercised in extrapolating our results. Many factors in the wild may influence the reactions of waterfowl to cadmium exposure, including the physiological condition of the bird, its diet, and the time of year when it is exposed. Our findings do suggest, however, that ducks with relatively low accumulations of cadmium in the kidneys or testes are probably not experiencing pathological difficulties due to cadmium.

REFERENCES

Kar, A. B. and Das, R. P. 1960. Testicular changes in rats after treatment with cadmium chloride. *Acta Biol. Med. Ger.* 5:153–173.

Nordberg, G. F. 1971. Effects of acute and chronic cadmium exposure on the testicles of mice. *Environ. Physiol.* 1:171–187.

Parizek, J. 1957. The destructive effect of cadmium ion on testicular tissue and its prevention by zinc. *J. Endocrinol.* 15:56–63.

Pritzl, M. C., Lie, Y. N., Kienholz, E. W., and Whiteman, C. E. 1974. The effect of dietary cadmium on development of young chickens. *Poult. Sci.* 53:2026–2029.

Richardson, M. E., Spivey Fox, M. R., and Fry, B. E. 1974. Pathological changes produced in Japanese quail by ingestion of cadmium. *J. Nutr.* 104:323–338.

Sangalong, G. B. and O'Halloran, M. J. 1973. Adverse effects of cadmium on brook trout testis and on *in vitro* testicular androgen synthesis. *Biol. Reprod.* 9:394–403.

Yoshiki, S., Yanagisawa, T., Kimura, M., Otaki, N., Suzuki, M., and Suda, T. 1975. Bone and kidney lesions in experimental cadmium intoxication. *Arch. Environ. Health* 30:559–562.

Received July 22, 1977
Accepted September 15, 1977