Food Cosmet. Toxicol. Vol. 16, pp. 591–596
Pergamon Press Ltd 1978. Printed in Great Britain

0015-6264/78/1201-0591$02.00/0

1008

Rb

A SYNERGISTIC EFFECT OF NITROSODIMETHYLAMINE ON STERIGMATOCYSTIN CARCINOGENESIS IN RATS

K. TERAO, T. AIKAWA and K. KERA

Research Institute for Chemobiodynamics, Chiba University, 280 Chiba, Inohana 1-8-1, Japan

(*Received 21 March 1978*)

Summary—In a study of a possible syncarcinogenic effect of nitrosodimethylamine (NDMA) on sterigmatocystin (STG) carcinogenesis, male rats were fed diets containing 10 ppm STG, 10 ppm STG and 1 ppm NDMA, 1 ppm STG and 10 ppm NDMA or 10 ppm NDMA for 54 wk. Hepatic carcinomas developed in 75% of the rats fed 10 ppm STG plus 1 ppm NDMA and in 53% of those fed 10 ppm STG alone. The hepatic carcinomas developed more rapidly in the former group. About 50% of the hepatic carcinomas induced by STG or STG plus NDMA showed a tubular arrangement of tumour cells. Ultrastructurally, a mixture of the characteristic organelles of hepatocytes and ductular cells were frequently found in the same cells. Throughout the experiment, proliferation of smooth endoplasmic reticulum was observed in the hepatocytes of rats fed with NDMA. Between wk 54 and 69, Leydig-cell tumours developed in 47, 45 and 15% of the animals on the 10 ppm NDMA plus 1 ppm STG and the 1 ppm NDMA plus 10 ppm STG diets, respectively. Although, at this level, NDMA alone did not induce hepatic carcinomas, it may have a role in STG-carcinogenesis in the liver, as an inducer of carcinogen-activating enzymes.

Introduction

Sterigmatocystin (STG), a compound related to aflatoxin B_1, is a metabolite of *Aspergillus versicolor*, *A. nidulans* and Bipolaris species. Hepatocellular carcinoma and some other types of malignant tumours are induced by this mycotoxin although it is about ten times less carcinogenic than aflatoxin B_1 (Fujii, Kurata, Odashima & Hatsuda, 1976; van der Watt, 1974). In the temperate and tropical zones where it is known to be an active food contaminant, STG may be an important factor in the incidence of human hepatic carcinoma.

The widespread presence of nitroso compounds in our environment, and the fact that these compounds are taken with food as well as formed in the stomach from precursors, necessitates careful study of their potential carcinogenic hazard to man (Eisenbrand, Ivankovic, Preussmann, Schmähl & Wissler, 1975). There could be some relationship between the high incidence of hepatic carcinoma in the temperate and tropical zones and combined contamination by mycotoxins and nitroso compounds. Since the report of MacDonald, Miller, Miller & Rusch (1952), it is now well-established that several hepatic carcinogens act synergistically. Until recently, however, most of the experiments were performed on man-made compounds. The present study was undertaken to investigate the possibility of syncarcinogenic effects of nitrosodimethylamine (NDMA) and sterigmatocystin in rats, mainly from a morphological viewpoint.

Experimental

Crystalline STG used in these experiments was generously donated by Dr. Y. Hatsuda, Department of Agriculture, Tottori University, as was NDMA by Dr. M. Nakadate, National Institute of Hygienic Science, Tokyo.

From the age of 4 wk, groups of 15 or 20 male Wistar rats (supplied by Shizuoka Dobuts Nokyo, Shizuoka) were given a basal diet (CE-2 from Nihon Clea Ltd., Tokyo) containing 10 ppm STG (group 1), 10 ppm STG and 1 ppm NDMA (group 2), 1 ppm STG and 10 ppm NDMA (group 3) or 10 ppm NDMA (group 4). A further 30 rats given the basal diet alone served as controls (group 5). The experimental diets were fed for 54 wk after which basal diet was given for the remaining period. After the first 5 wk of feeding, one animal from each experimental group was killed and autopsied. All surviving animals were kept under observation for a total period of 69 wk. Autopsies were performed on all animals that died or were killed during the experiment or at termination.

For light microscopy, samples of all the major organs were fixed in 10% formalin and stained with haematoxylin and eosin or periodic acid–Schiff or by silver impregnation. For electron microscopy, pieces of the liver tissue and/or tumours were fixed in 2·5% glutaraldehyde for 12 hr, post-fixed in 1% osmium tetroxide for 2 hr and embedded in Epon 812 for sectioning. Ultrathin sections were double-stained with uranyl acetate and lead citrate.

Results

No pathological changes were detected grossly or by light microscopy in the rats killed at wk 5, but electron microscopy showed a marked proliferation of the smooth endoplasmic reticulum (Fig. 1) and an

9247

Table 1. *Incidence of hepatic carcinomas and testicular Leydig-cell tumours in rats given sterigmatocystin and or dimethylnitrosamine*

Group no.	Carcinogens administered STG (ppm)	NDMA (ppm)	No. of rats alive at wk 1	54	No. of rats with Hepatic carcinoma	Leydig-cell tumours	Mean time to autopsy (wk)
1	10	—	15	14	8/15	0/15	60
2	10	1	20	15	15/20	3/20	57
3	1	10	20	17	1/20	9/20	69
4	—	10	15	14	0/15	7/15	69
5	—	—	30	25	0/30	0/30	69

accumulation of inter- and perichromatin granules. in the hepatocytes of the rats fed diets containing STG and/or NDMA. At a later stage, hepatic carcinoma developed in 53, 75 and 5% of the animals in groups 1 (10 ppm STG), 2 (10 ppm STG/1 ppm NDMA) and 3 (1 ppm STG/10 ppm NDMA), respectively. These were diagnosed at mean autopsy times of 60, 57 and 69 wk respectively, for these three groups. No metastases were found. Tumours in the liver were first observed after 54 wk of treatment with STG alone (group 1) and after 46 wk of treatment with STG plus NDMA (group 2). The number of rats with hepatic carcinoma increased after wk 60 in group 1 and wk 54 in group 2. By wk 69 the incidence of hepatic carcinomas was 8/14 and 15/15 in groups 1 and 2 respectively. Only one other hepatic carcinoma was detected, at wk 69, and this was in a rat given 1 ppm STG plus 10 ppm NDMA (group 3). There were no hepatic carcinomas in rats fed 10 ppm NDMA alone or in control rats.

In rats from groups 1 and 2 autopsied between wk 40 and 50 multiple gray-white nodules up to 1 mm in diameter were visible on the surface of the liver. Histological examination revealed that these nodules were clear-cell foci or neoplastic nodules. In the ensuing 12 wk they developed into hepatic carcinomas. Occasionally, circumscribed, firm, gray-white neoplastic lesions were present in every lobe of group 1, 2, and 3 rat livers and were usually from 0·5 to 2·0 cm in diameter. There was a hollow area at the surface of the neoplastic lesion in several instances. Histologically, most hepatic carcinomas were diagnosed as well- and/or poorly-differentiated trabecular type; moreover, about 50% of the hepatic carcinomas induced by STG and/or STG plus NDMA showed characteristic features (Fig. 2). These tumours showed glandular arrangements and occasional wide lumina. The lining cells were in direct contact with underlying hepatocellular carcinoma cells without intervening connective tissue. The development of hepatic carcinoma with glandular arrangement was independent of the length of time during which the animal had been receiving an experimental diet. Those tumours which showed a hollow area on the surface were always adenomatous in nature. The lumina were usually irregular, the lining cells were cuboid or flat and the cytoplasm was eosinophilic. Cells with glandular arrangement showed polarization of organelles in relation to the luminal and basal surface. With silver impregnation, they showed basement membrane and abundant granules at the luminal surface of the cytoplasm, while most of the hepatic carcinoma cells showed no such polarized distribution of the cell organelles. Occasionally the lumina of these glands were filled with eosinophilic material which did not stain with periodic acid–Schiff. Mitotic figures were frequently observed. A transitional form between lining cell and trabecular hepatic carcinoma cell was seen (Fig. 3). Clear cell foci and basophilic areas were numerous in the liver of rats treated with STG plus NDMA. The livers of rats treated with 10 ppm NDMA for 54 wk showed almost normal histological patterns.

The ultrastructure of well-differentiated hepatocellular carcinoma was similar to that reported previously (Ghadially & Parry, 1966; Ma & Webber, 1966; Ruebner, Gonzalez-Licea & Slusser, 1967; Yasutake, Nakao & Matsunaga, 1962). Lining cells both with and without basement membrane were distinguished (Figs 4 & 5). The lining cells with basement membranes usually showed dense collagen fibres and several fibroblasts under the basement membrane, while those without the membrane had no such stromal components. The ultrastructure of these two cell types was essentially similar. Most of lining cells showed a transitional form between hepatocytes and biliary cells (Figs 4 & 5). Numerous small microvilli were present on the luminal surface of the lining cells. The cells connected with neighbouring cells at complicated interdigitations. Intracytoplasmic fibrils were abundant and they anchored frequently in desmosomes. The granular endoplasmic reticulum was relatively scanty. Ribosomes attached not separately but in contact with each other on the cisternae of the granular endoplasmic reticulum and were usually only on one side of the cisternae (Fig. 5 inset). Free ribosomes and polysomes were numerous in the cytoplasm of tubular types of the hepatic carcinoma cells. Smooth endoplasmic reticulum was frequently proliferated. Membrane whorls were often present in the cytoplasm of both lining cells and underlying hepatocellular carcinoma cells (Fig. 4). Glycogen particles had decreased in number. Peroxisomes were always present. Golgi apparatus was well-developed. Mitochondria were numerous and of normal shape, though electron-dense matrix granules were more numerous than usual. Nuclei were irregular in contour and nucleoli were always prominent.

Until wk 54 no macroscopic tumours apart from those in the liver were found in any rats fed NDMA. Tumours of the testis were encountered thereafter in all groups of rats that had received NDMA. The incidence of these tumours was 15% in group 2, 45% in group 3 and 47% in group 4. The contra-lateral

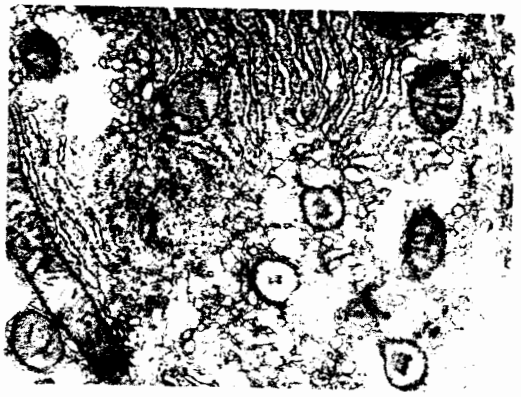

Fig. 1. Hepatocyte from a rat fed a diet containing 10 ppm STG and 1 ppm NDMA for 5 wk, showing proliferation of smooth endoplasmic reticulum in the cytoplasm. × 20,000.

Fig. 2. Hepatic carcinoma from a rat of group 2, that received a diet containing 10 ppm STG and 1 ppm NDMA for 54 wk, showing a glandular arrangement of carcinoma cells, and lining cells in direct contact with the underlying carcinoma cells. Haematoxylin and eosin. × 200.

Fig. 3. Hepatic carcinoma from a rat of group 2 showing transitional form between lining cells and trabecular hepatic carcinoma cells. Haematoxylin and eosin. × 500.

Fig. 4. Hepatic carcinoma of a group 2 rat showing lining cells (L) without basement membrane but having well-developed microvilli at the luminal surface of the cytoplasm, and a membrane whorl (arrowed, Inset). H: Malignant hepatocyte. × 3000. Inset: × 18,000.

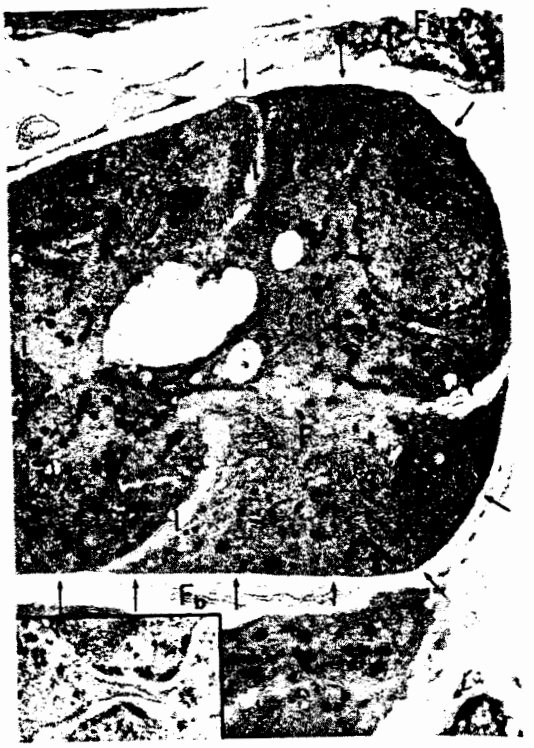

Fig. 5. Hepatic carcinoma, induced by STG, showing distinct basement membrane (arrowed) around the carcinoma cells of glandular arrangement and several fibroblasts (Fb) under the membrane. In the cytoplasm of the tumour cells there are abundant microfibrils (F), proliferated smooth endoplasmic reticulum (S), interdigitations (I) and free ribosomes. × 5300. Inset showing an irregular arrangement of ribosomes on the cisternae of granular endoplasmic reticulum. × 60,000.



Fig. 6. Leydig-cell tumour cells in a rat fed 10 ppm NDMA for 69 wk. The tumour is composed of small cells with scanty cytoplasm and large cells with abundant eosinophilic vacuolated cytoplasm. Haematoxylin and eosin. × 200.

testis was occasionally atrophic. No mascroscopic tumours were present in the testes of rats in group 1 and the control group.

Testicular neoplasms in rats treated with NDMA or NDMA plus STG were typical Leydig-cell tumours, soft and yellowish white, and were up to 1·5 cm in diameter. Large tumours were composed of small cells with scanty cytoplasm and large cells with abundant eosinophilic vacuolated cytoplasm (Fig. 6). In the immediate vicinity of the tumour tissue, seminiferous tubules were atrophic. The proliferation of Leydig cells in the testes of older rats in all groups was frequently seen. They were detected only on microscopic examination. Their histological pattern was essentially similar to that of interstitial cell tumours.

Discussion

The data presented here demonstrated that a low concentration of NDMA may act synergistically in STG hepatocarcinogenesis. This result agrees with the previous report of the syncarcinogenic effect of minute doses of the four carcinogens: NDMA, nitrosodiethylamine, nitrosomorpholine and 4-dimethylaminoazobenzene (Schmähl, 1970). The incidence of hepatic tumours was higher in group 2 fed STG and NDMA than in those fed STG alone and the tumours developed more rapidly in the former group, although under the conditions of this experiment the level of NDMA used was apparently below the effective hepatocarcinogenic dose. No pathological changes were detected in rats fed 10 ppm NDMA continuously for 54 wk, but Magee & Barnes (1956) found that 50 ppm NDMA induced tumours in almost all the treated animals.

There is increasing evidence that minimal doses of two carcinogens elicit either a synergistic response or an inhibitory effect on liver carcinogenesis. Although there is still some disagreement about the exact factors determining either accentuation or suppression of hepatocarcinogenesis, it was confirmed recently that many carcinogens, including NDMA and aflatoxin B_1 are activated by drug-metabolizing enzymes (Nagata & Kodama, 1976). Fouts, Rogers & Gram (1966) have shown that there is a close relationship between the proliferation of smooth endoplasmic reticulum and the induction of drug-metabolizing enzymes such as *P*-450. It is interesting, therefore, that the proliferation of the smooth endoplasmic reticulum was always observed in the livers of rats fed with experimental diets containing NDMA. Although the low level of NDMA in the present experiments induced no hepatic carcinomas, it may play an important role in STG-carcinogenesis as an inducer of carcinogen-activating enzymes.

About 50% of hepatic carcinomas induced by STG or STG plus NDMA showed tubular arrangement of tumour cells. The histological pattern of this tumour is different from that of cholangiocarcinoma. Histologically, the classical cholangiocarcinoma is composed of single columnar tumour cells and stroma in which there are abundant fibroblasts, collagen fibers and capillaries. In contrast, tubularized hepatic carcinoma induced by STG or STG plus NDMA usually had only capillaries as stroma. The fine structure of these tumour cells was intermediate between ductular cells and hepatic parenchymal cells. The characteristic organelles of the hepatocyte, such as peroxisomes, proliferating agranular endoplasmic reticulum, and membrane whorls, were found in the same cells as were the typical organelles of ductular cells such as basement membrane, abundant intracytoplasmic fibrils, well-developed Golgi apparatus and free ribosomes. Glandular or tubular arrangement of hepatocytes has been observed in a variety of experimental conditions and in several human livers (Ghadially & Parry, 1966; Ma & Webber, 1966; Phillips & Steiner, 1966; Ruebner *et al.* 1967). However, little information is available about the hepatic carcinoma consisting of cells with organelles intermediate between ductular and hepatocyte types. Biliary hepatocytes, as designated by Phillips & Steiner (1966), are those hepatocytes which have a basement membrane and show distinctly a polarization of organelles toward a major biliary pole. Ruebner *et al.* (1967) reported a hepatoma with the coexistence of hepatomatous and cholangiocarcinomatous areas in the same cell. Such an observation was confirmed in rat hepatic carcinoma induced by 3′-methyl-4-dimethylaminoazobenzene (Ma & Webber, 1966). Whether these tubularized hepatic carcinomas represent ductular metaplasia of hepatocellular carcinoma cells or dedifferentiated hepatoblastoma is not certain.

The subject of Leydig-cell tumours in the testis of laboratory animal species is well documented. Spontaneous Leydig-cell tumours are occasionally found in aged rats and the incidence of the tumour shows a wide range depending on the strain. Crain (1958) reported a 9·3% incidence of spontaneous testicular interstitial tumours in Wistar rats aged between 18 and 24 months, whereas the incidence was 68% in Fischer rats aged between 16 and 30 months (Jacobs & Huseby, 1967). These tumours can be induced experimentally by several methods including the subcutaneous injection of cadmium (Gunn, Gould & Anderson, 1965), ligation of testicular vessels (Takewaki, 1962), administration of exogenous oestrogens (Hooker & Pfeiffer, 1942; Huseby, Dominguez & Samuels, 1961) and intrasplenic grafting of the testis (Twombly, Meisel & Stout, 1949). In this study, a relatively high incidence of Leydig-cell tumours was encountered only in rats receiving diets containing NDMA for a limited time. Moreover, a dose-response relationship for NDMA is indicated in the present experiments. Therefore, NDMA may accentuate the susceptibility of the testes to these tumours, although frequently spontaneous Leydig-cell tumours are encountered in the same strain. The histological features of NDMA-induced Leydig-cell tumours correspond in most respects with those previously reported for tumours of these cells (Crain, 1958; Gunn, Gould & Anderson, 1965; Hooker & Pfeifer, 1942; Jacobs & Huseby, 1967; Takewaki, 1962; Twombly *et al.* 1949).

The present results, indicating a possible syncarcinogenic effect of minute doses of naturally-occurring carcinogens such as STG and NDMA, may be of considerable significance to human health.

Acknowledgements—This work was supported in part by

Grants-in-Aid for Cancer Research from the Ministry of Health and Welfare of Japan. The authors are grateful to Dr. Y. Hatsuda, Department of Agriculture, Tottori University, and Dr. M. Nakadate, National Institute of Hygenic Science, Tokyo, for providing the carcinogens.

REFERENCES

Crain, R. C. (1958). Spontaneous tumors in the Rochester strain of the Wistar rat. *Am. J. Path.* **34**, 311.

Eisenbrand, G., Ivankovic, S., Preussmann, R., Schmähl, D. & Wissler, M. (1975). Some recent results on the chemistry, formation, and biological activity of N-nitroso-compounds. In *Gann Monograph on Cancer Research*. No. 17, p. 133. Japanese Foundation for Cancer Research, Tokyo, Japan.

Fouts, J. R., Rogers, L. A. & Gram, T. E. (1966). The metabolism of drugs by hepatic microsomal enzymes. Studies on intramicrosomal distribution of enzymes and relationships between enzyme activity and the structure of the hepatic endoplasmic reticulum. *Expl mol. Path.* **5**, 475.

Fujii, K., Kurata, H., Odashima, S. & Hatsuda, Y. (1976). Tumor induction by a single subcutaneous injection of sterigmatocystin in newborn mice. *Cancer Res.* **36**, 1615.

Ghadially, F. N. & Parry, E. W. (1966). Ultrastructure of human hepatocellular carcinoma and surrounding non-neoplasmic liver. *Cancer, N.Y.* **19**, 1989.

Gunn, S. A., Gould, T. C. & Anderson, W. A. D. (1965). Comparative study of interstitial cell tumors of rat testis induced by cadmium injection and vascular ligation. *J. natn. Cancer Inst.* **35**, 329.

Hooker, C. W. & Pfeifer, C. A. (1942). The morphology and development of testicular tumors in mice of the A strain receiving estrogens. *Cancer Res.* **2**, 759.

Huseby, R. A., Dominguez, O. V. & Samuels, L. T. (1961). Function of normal and abnormal testicular interstitial cells in the mouse. *Recent Prog. Horm. Res.* **17**, 1.

Jacobs, B. B. & Huseby, R. A. (1967). Neoplasms occurring in aged Fischer rats, with special reference to testicular, uterine, and thyroid tumors. *J. natn. Cancer Inst.* **39**, 303.

Ma, M. H. & Webber, A. J. (1966). Fine structure of liver tumors induced in the rat by 3′-methyl-4-dimethylaminoazobenzene. *Cancer Res.* **26**, 935.

MacDonald, J. C., Miller, E. C., Miller, J. A. & Rusch, H. P. (1952). The synergistic action of mixtures of certain hepatic carcinogens. *Cancer Res.* **12**, 50.

Magee, P. N. & Barnes, J. M. (1956). The production of malignant primary hepatic tumours in the rat by feeding dimethylnitrosamine. *Br. J. Cancer* **10**, 114.

Nagata, C. & Kodama, M. (1976). Cytochrome P-450 and carcinogenic substances. *Metabolism, Japan* **13**, 1705.

Phillips, M. J. & Steiner, J. W. (1966). Electron microscopy of cirrhotic nodules. Tubularization of the parenchyma by biliary hepatocytes. *Lab. Invest.* **15**, 801.

Ruebner, B. H., Gonzalez-Licea, A. & Slusser, R. J. (1967). Electron microscopy of some human hepatomas. *Gastroenterology* **53**, 18.

Schmähl, D. (1970). Experimentelle Untersuchungen zur Syncarcinogenese. VI. Mitteilung: Addition minimaler Dosen von vier verschiedenen hepatotropen Carcinogenen bei der Leberkrebserzeugung bei Ratten. *Z Krebsforsch.* **74**, 457.

Svoboda, D. J. (1964). Fine structure of hepatomas induced in rats with *p*-dimethylaminoazobenzene. *J. natn. Cancer Inst.* **33**, 315.

Takewaki, K. (1962). Estrogen-secreting testicular tumor produced experimentally in the rat. I. General characteristics. *Anat. Zoolog. Japn.* **35**, 57.

Twombly, G. H., Meisel, D. & Stout, A. D. (1949). Leydig cell tumors induced experimentally in the rat. *Cancer, N.Y.* **2**, 884.

van der Watt, J. J. (1974). Sterigmatocystin. In *Mycotoxins* Edited by I. F. H. Purchase, p. 369. Elsevier Scientific Publishing Co., Amsterdam.

Yasutake, S., Nakao, K. & Matsunaga, Y. (1962). Fine structure of human hepatoma. *Kurume Med. J.* **9**, 193.