1053

FUNDAMENTAL AND APPLIED TOXICOLOGY 1:389-394 (1981)

10/1/81 Ref

Induction of Hepatic and Testicular Lesions in Fischer-344 Rats by Single Oral Doses of Nitrobenzene

JAMES A. BOND, JOHN P. CHISM, DOUGLAS E. RICKERT and JAMES A. POPP
Departments of Biochemical Toxicology and Pathology, Chemical Industry Institute of Toxicology,
P.O. Box 12137, Research Triangle Park, North Carolina 27709

ABSTRACT

Induction of Hepatic and Testicular Lesions in Fischer344 Rats by Single Oral Doses of Nitrobenzene. J.A. Bond, J.P. Chism, D.E. Rickert and J.A. Popp. (1981). *Fundam. Appl. Toxicol.* 1:389-394. Since the acute toxicity of nitrobenzene (NB) in rats has not been characterized, experiments were performed to ascertain the possible deleterious effects of NB in different tissues of the male Fischer-344 rat. Rats were given single oral doses of NB (50-450 mg/kg) and at the time of sacrifice, 25 tissues were removed and examined histologically by light microscopy. Histopathological changes induced by a single oral dose of NB consistently involved only the liver and testes. One rat receiving 450 mg NB/kg had a microscopic cerebellar lesion. Hepatic centrolobular necrosis appeared inconsistently in rats given various doses of NB, while hepatocellular nucleolar enlargement was consistently detected in rats given doses of NB as low as 110 mg/kg. These data suggest that nucleolar enlargement was independent of cell death and subsequent regeneration. Testicular lesions were confined to the seminiferous tubules and consisted of necrosis of the primary and secondary spermatocytes with the appearance of multinucleated giant cells between one and four days after administration of NB 300 mg/kg. Necrotic debris and decreased numbers of spermatozoa were seen in the epididymis as early as three days after NB administration. The NB-induced methemoglobinemia does not appear to be solely responsible for the formation of early lesions in the rat liver, testes, or brain, since sodium nitrite administration, at dosages which produced methemoglobinemia equivalent to that of NB, did not produce any histopathological changes. Thus, the observed liver and testicular damage are probably due to a direct effect of NB or its metabolites.

INTRODUCTION

Nitrobenzene (NB) is produced industrially as an intermediate in the synthesis of aniline, and in the manufacture of chemical intermediates for dyes, solvents, propellants, medicinals, and agricultural chemicals. Estimates of NB release in the environment range from 8-20 million pounds annually (Dorigan and Hushon, 1976).

Methemoglobinemia is the predominant acute effect of NB in humans and laboratory animals (Nabarro, 1948; Parkes and Neill, 1953; Magos and Sziza, 1959; Harrison, 1977). Blood dyscrasias have also been reported during the stages of acute and chronic NB poisoning, including decreases in circulating hemoglobin and in erythrocyte and platelet counts; hemolytic anemia; and bone marrow hyperplasia (Shimkin, 1939; Hamblin, 1949; Parkes and Neill, 1953).

With the exception of the blood dyscrasias, no evidence of chronic toxicity of NB in humans is available, but case studies of workers acutely exposed to NB and experiments conducted in laboratory animals suggest that the liver, kidney, and spleen may be target organs for chronic NB exposure (Skimkin, 1939; Ravault et al., 1946; Hamblin, 1949). However, rigorous morphologic studies with dose-related observations have not been conducted in experimental animals.

The purpose of this investigation was to identify possible target organs of NB toxicity in Fischer-344 rats utilizing single oral doses of NB. The results indicate that both the liver and testes are affected following administration of a single oral dose of NB.

METHODS

Animals

Male (80-90 day old) Fischer-344 rats (CDF/CrlBR) weighing approximately 200 g were obtained from the Kingston, New York colony of Charles River Breeding Laboratories. On arrival, rats were housed 3 per cage in suspended wire-bottomed stainless steel cages and acclimated to the animal housing quarters for one to two weeks prior to initiating the studies. During this time, rats were fed pelleted NIH-07 diet (BioServ, Frenchtown, New Jersey), an open formula cereal based diet, and tap water *ad libitum*. Animals were housed in rooms with a 12 hour light: dark cycle. Temperature was maintained at 70 ± 5°F and the relative humidity at 50 ± 10%.

Dose-response study

Rats were divided into seven groups of six rats each and fasted 16 hrs prior to oral administration of 50, 75, 110, 165, 200, 300 or 450 mg NB/kg body weight. Control rats received corn oil, the vehicle for NB. After dosing, food and water was provided *ad libitum*.

Three rats at each dosage were sacrificed two and five days following NB (Fischer Scientific Co., Fair Lawn, New Jersey) administration. At the time of sacrifice, blood was drawn by cardiac puncture for analysis of methemoglobin and the results expressed as a percentage methemoglobinemia (Evelyn and Malloy, 1938). The liver, testes, and brain from all rats were histologically examined. Additional tissues were collected from the 450 mg/kg body weight group at 5 days following administration of NB. These tissues were: thoracic spinal cord, submixillary salivary gland, lymph node-cervical, pituitary, upper colon, urinary bladder, lung, stomach, prostate, thryoid, thymus, heart, kidney, duodenum, trachea, nasal cavity, pancreas, adrenal, spleen, esophagus, ileum, and sciatic

9326

Copyright 1981, Society of Toxicology

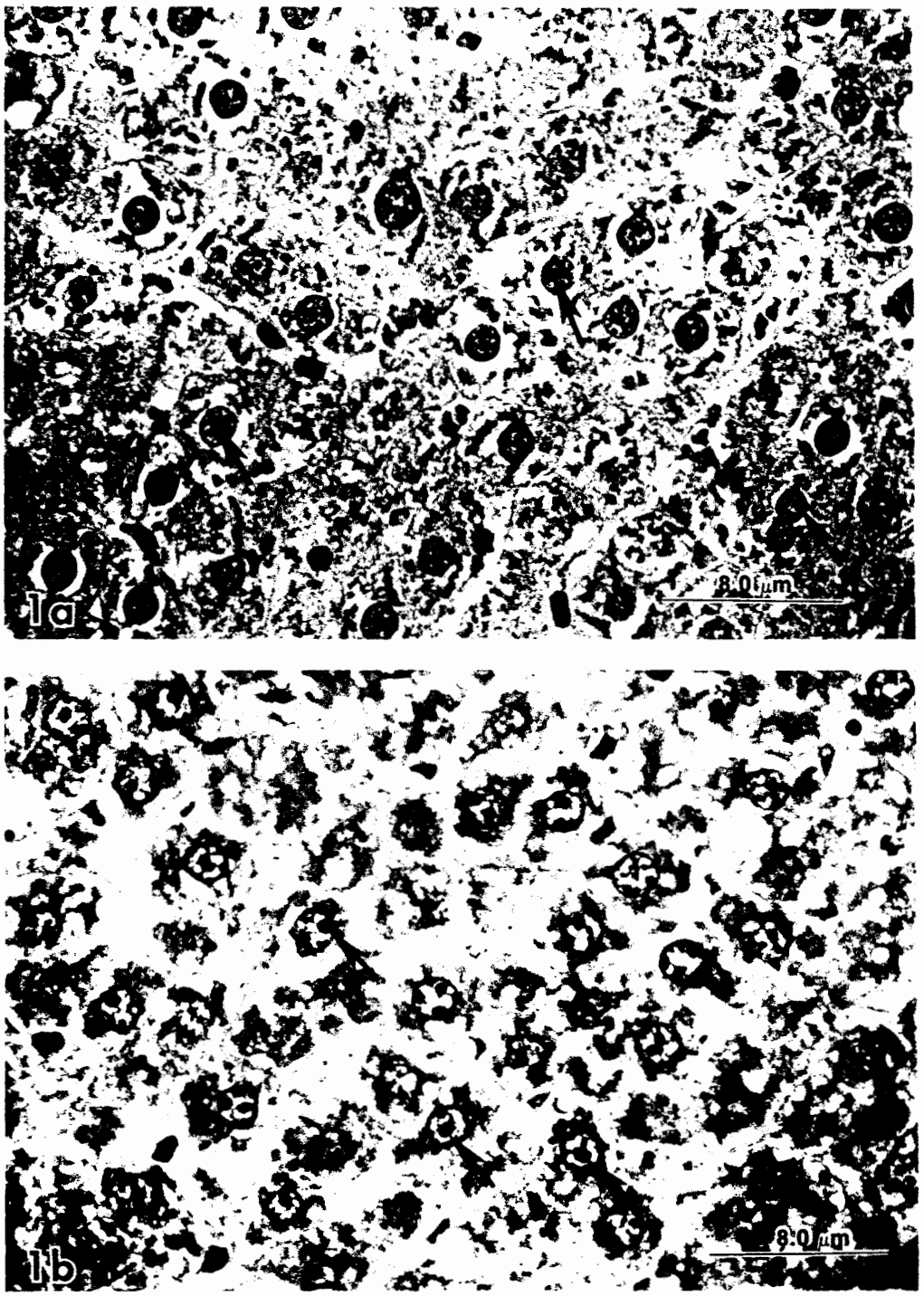

FIG 1. (a) Photomicrograph of a liver from a male rat given corn oil orally (1 mL/kg) and sacrificed two days later. Normal nucleoli are identified by arrows (400 x). (b) Photomicrograph of a liver from a male rat given nitrobenzene (300 mg/kg) orally and sacrificed two days later. Enlarged nucleoli are identified by arrows (400 x).

nerve. Tissues were individually fixed in 10% buffered formalin and routinely processed into paraffin blocks. Sections of selected tissues were cut, mounted and stained with hematoxylin and eosin for microscopic evaluation.

Time-response study

Rats were divided into seven groups of three rats each and fasted 16 hrs prior to oral NB administration (300 mg/kg body weight in corn oil). After dosing, food and water was provided *ad libitum*. Control rats received only corn oil (1 mL/kg). Rats were sacrificed at 1, 2, 3, 4, 7, and 10 days following NB administration. At the time of sacrifice, blood was drawn by cardiac puncture for analysis of methemoglobin (Evelyn and Malloy, 1938). Liver, testes, and brain were excised from all animals and examined histologically. The additional tissues listed above were removed and examined histologically from those rats sacrificed at 10 days after NB administration.

TABLE 1
Number of Animals with Histologic Lesions After Different Doses of Nitrobenzene (NB)[A,B]

	Dose (mg/kg)									
	110		165		200		300		450	
Days after NB Administration	2	5	2	5	2	5	2	5	2	5
LIVER										
Enlarged Nucleoli	3/3	0/3	3/3	0/3	3/3	2/3	3/3	3/3	3/3	3/3
Centrolobular Necrosis	1/3	0/3	0/3	0/3	2/3	0/3	0/3	1/3	3/3	3/3
TESTES AND EPIDIDYMUS										
Enlarged Spermatocytes	0/3	0/3	0/3	0/3	0/3	0/3	0/3	0/3	0/3	0/3
Necrosis of Spermatogenic Cells	0/3	0/3	0/3	0/3	0/3	1/3	0/3	3/3	0/3	3/3
Multinucleated Giant Cells	0/3	0/3	0/3	0/3	0/3	1/3	0/3	3/3	0/3	3/3
↓ Spermatozoa in Epididymis	0/3	0/3	0/3	0/3	0/3	0/3	0/3	3/3	3/3	3/3
Necrotic Debris in Epididymis	0/3	0/3	0/3	0/3	0/3	0/3	0/3	3/3	3/3	3/3

[A]Rats were given single oral doses of NB in corn oil and sacrificed either two or five days after dosing. Ratios reported represent: number of rats with observed lesion/number of rats in experimental group.

[B]No histopathological lesions were noted in livers or testes of rats receiving single oral doses of either 50 mg/kg or 75 mg/kg of NB.

TABLE 2
Number of Animals with Histologic Lesions at Various Times After Nitrobenzene (NB) Administration[A]

	Days After NB Administration					
	1	2	3	4	7[B]	10
LIVER						
Enlarged Nucleoli	3/3	3/3	3/3	3/3	0/1	0/3
Centrolobular Necrosis	2/3	0/3	0/3	0/3	0/1	0/3
TESTES AND EPIDIDYMUS						
Enlarged Spermatocytes	3/3	0/3	0/3	0/3	0/1	0/3
Necrosis of Spermatogenic Cells	3/3	3/3	3/3	3/3	0/1	1/3
Multinucleated Giant Cells	0/3	0/3	3/3	3/3	1/1	2/3
↓ Spermatozoa in Epididymis	3/3	0/3	3/3	3/3	1/1	1/3
Necrotic Debris in Epididymis	0/3	0/3	3/3	3/3	1/1	3/3

[A]Rats were treated with NB in corn oil (300 mg/kg) and sacrificed at the times indicated. Ratios reported represent: number of rats with observed lesion/number of rats in experimental group.

[B]Two rats in this group died prior to the scheduled sacrifice.

Sodium nitrite - induced methemoglobinemia

Five rats were each injected intraperitoneally with 15 mg/kg body weight sodium nitrite every three hrs for a period of three days. Preliminary studies had indicated that this dosing regimen was sufficient to maintain 20-40% methemoglobinemia. Rats were sacrificed one hour after the last injection of sodium nitrite and the liver, testes, and brain were removed for histopathological evaluation.

RESULTS

The LD_{50} of nitrobenzene (oral) in rats has previously been reported to be 640 mg/kg (Fairchild, 1977). Rats administered an oral dose of NB developed histopathological lesions in the liver and the testes. Hepatocellular nucleolar enlargement, with marginated chromatin, was the most marked and consistent lesion found in the liver (Fig 1). Obvious hepatocellular nucleolar enlargement was found two days after doses of NB as low as 110 mg/kg (Table 1). Nucleolar enlargement was noted as early as 24 hrs after a single dose of NB (300 mg/kg) and persisted through 5 days in livers from rats given 200-450 mg/kg (Tables 1 & 2). Centrolobular hepatocytic necrosis appeared in all rats two or five days after administration of 450 mg/kg NB. Lower doses of NB resulted in inconsistent centrolobular necrosis in a few rats (Table 1).

Testicular lesions were restricted to the seminiferous tubules. The early lesion consisted of enlarged, pale staining cytoplasm of the primary and secondary spermatocytes. Progressive necrosis of these layers was seen with complete destruction of the spermatocytes at days two and three after 300 and 450 mg NB/kg (Table 2). NB administration had no apparent histopathological effect on spermatogonia. Within three days of NB administration, multinucleated giant cells within the seminiferous tubules were detected (Table 2, Fig 2). In addition, necrotic debris and decreased numbers of spermatozoa were noted in the epididymis as early as three days and as late as ten days after NB administration (Table 1, Fig 3). NB had no apparent effect on the epididymal epithelium.

Brains from all rats were examined histologically for lesions in the cerebrum, thalamus, midbrain, cerebellum, and medulla. A lesion was found in the brain of one rat which received

FIG 2. Photomicrograph of a seminiferous tubule from a male rat given nitrobenzene (300 mg/kg) and sacrificed three days later. Necrotic spermatogenic epithelium (a) and multinucleated giant cells (arrows) are consistent lesions. (200 x).

450 mg NB/kg body weight and sacrificed 5 days later. This lesion consisted of a bilateral malacic area and reactive gliosis in the cerebella peduncles. Similar brain lesions were previously noted in rats receiving NB in our laboratory, and one report in the literature describes a lesion in the cerebellar cortex in dogs induced by acute NB exposure (Dreshbach and Chandler, 1918).

Methemoglobin was elevated in rats treated with NB throughout the duration of both the time-course and dose-response studies. Following a single dose of NB (300 mg/kg body weight) in rats, methemoglobinemia reached a maximum (25%) within 3 hrs. Methemoglobin remained elevated at 20-25% for up to 16 hrs followed by a steady decline to 4% over a period of 10 days (Fig 4). This pattern of methemoglobin forma-

FIG 3. Photomicrograph of the epididymis from a male rat given nitrobenzene (300 mg/kg) and sacrificed 7 days later. The epididymal epithelium is normal but the tubules contain necrotic debris (a). (200 x).

tion and disappearance in rats was previously reported (Magos and Sziza, 1959). The half-time for methemoglobin disappearance from NB-treated rats was 4 days (Fig 4). Formation of methemoglobin in rats was dose-dependent at both two and five days subsequent to NB administration (Fig 5).

Administration of sodium nitrite to rats for three days resulted in a prolonged methemoglobinemia of severity similar to that produced by NB, but histopathological evaluation of the liver, testes, and brain showed no evidence of lesions.

DISCUSSION

At the doses tested, both the liver and testes were consistent target tissues for NB toxicity. Sodium nitrite, at dosages which produced methemoglobinemia equivalent to that of NB in a separate group of rats, did not produce these similar histopathologic changes. Thus, the prolonged methemoglobinemia produced by NB does not appear to be solely responsible for the lesions in the liver or testes. The observed liver and testicular damage are probably due to a direct effect of NB or its metabolites.

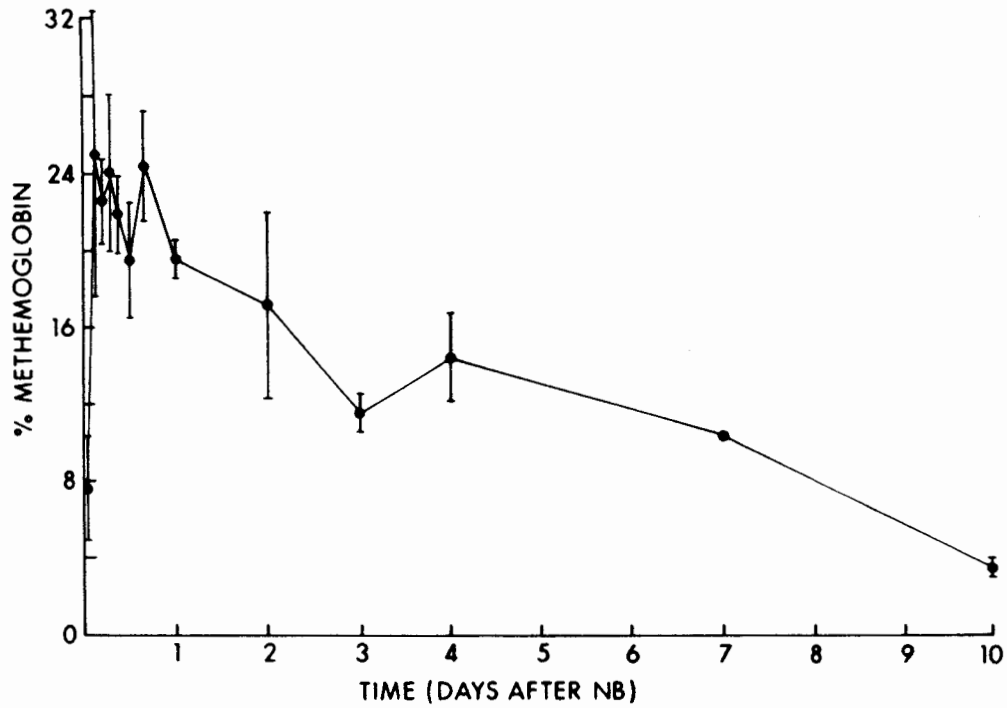

FIG 4. Time course of methemoglobin disappearance in rats following a single oral dose of nitrobenzene (300 mg/kg). Values represent the mean ± S.E. (n = 3).

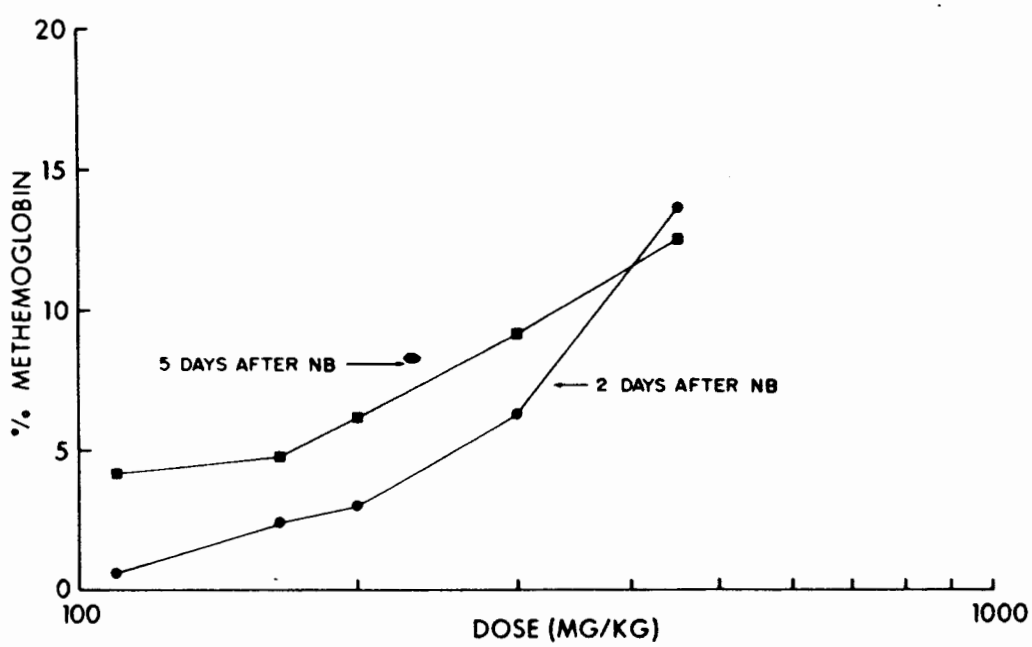

FIG 5. Percentage methemoglobinemia in rats after different doses of nitrobenzene. Values represent the mean ± S.E. (n = 3). •——•, rats sacrificed two days after a single dose of nitrobenzene; ■——■, rats sacrificed five days after a single dose of nitrobenzene.

The data in this report suggest that repeated administration of NB to rats is necessary for a sustained hypertrophy of hepatic nucleoli. Hepatic nucleolar hypertrophy, as seen with NB, is a common lesion resulting from chronic treatment of rats with some hepatocarcinogens (Svoboda and Reddy, 1975). In a comprehensive report on the effects of chemical carcinogens on cell organelles (Svododa and Reddy, 1975), ethionine and thioacetamide were reported to cause nucleolar enlargement after multiple dosing. 3'-Methyl-4-dimethylaminoazobenzene caused enlargment of hepatic nucleoli when fed to rats for three weeks (Yasuzumi et al., 1970); similar observations were noted with p-dimethylaminoazobenzene (Timme, 1974). Several of the above chemicals are hepatocarcinogens, but no data are currently available which implicate NB as an hepatocarcinogen.

Enlargement of nucleoli is a typical response in cells undergoing proliferation (Busch and Smetana, 1970), particularly regeneration. Since enlarged nucleoli were present at low doses while hepatic necrosis was observed only at high doses, the nucleolar response to NB does not appear to be solely due to cellular regeneration secondary to necrosis. The observation that low doses of NB resulted in nucleolar hypertrophy but not hepatic necrosis further supports this conclusion.

Initial changes (enlarged spermatocytes) in the rat testes occurred within 24 hrs after relatively large doses of NB (300-450 mg/kg). The appearance of necrotic debris in the seminiferous tubules and epididymis by 3 days is indicative of a rapidly developing and severe testicular lesion, which may result in a decrease in the reproductive capacity of rats. Single intraperitoneal (i.p.) doses of trifluoroethanol in rats produced specific damage to both the primary and secondary spermatocytes (Wilkenfeld et al., 1980). Similarly, single i.p. doses of quinalphas, an organophosphorous insecticide, produced spermatogenic cell degeneration and pycnotic spermatocytes in gerbils (Sarin and Saxena, 1978). Other compounds require repeated administration to induce similar types of testicular lesions in laboratory animals. For example, enlarged spermatocytes and giant cells were observed in the seminiferous tubules of rats fed 5-thioglucose for 21 days (Zysk et al., 1975). 1-Methyl-5-nitroimidazole, when given orally to rats for 14 or 30 days, induced degenerative changes in pachytene spermatocytes and the appearance of multinucleated giant cells in the seminiferous tubules (Patanelli, 1975). 1,3-Dinitrobenzene when administered in the drinking water for 8 weeks caused testicular atrophy in rats (Cody et al., 1981).

The data presented here suggest that chronic experimental studies with NB should focus on the potential effects of NB on the rat liver, testes, and brain. While the liver appears to repair the damage induced by acute NB exposure, there is not evidence in this report to suggest that the testicular damage is reversible. However, the observation that NB had no apparent effect on the spermatogonia suggests that the lesion may be reversible. A longer time of recovery may be necessary to demonstrate reversibility of the testicular lesions.

ACKNOWLEDGEMENTS

The authors wish to acknowledge the technical assistance of Belinda Scortichini, Otis Lyght, and Holly Randall for their excellent preparation of tissues for histological examination.

REFERENCES

Busch, H. and Smetana, J. (1970). In *The Nucleolus*, (ed: F.F. Becker) pp. 492-497, Academic Press, New York.

Cody, T.E., Witherup, S., Hastings, L., Stemmer, K. and Christian, R.T. (1981). 1,3-Dinitrobenzene: Toxic effects *in vivo* and *in vitro*. *Toxicol. Environ. Health* 7:829-847.

Dorigan, J. and Hushon, J. (1976). Air pollution assessment of nitrobenzene. U.S. Environ. Protection Agency, Document #PB 257 776.

Dreshbach, M. and Chandler, W.L. (1918). The toxic action of nitrobenzene, with special reference to the cerebellum. *Proc. Soc. Exp. Biol. Med.* 15:136-137.

Evelyn, K.A. and Malloy, H.T. (1938). Microdetermination of oxyhemoglobin, methemoglobin, and sulfhemoglobin in a single sample of blood. *J. Biol. Chem.* 126:655-662.

Fairchild, E.J. [ed.] (1977). Registry of toxic effects of chemical substances. Natl. Inst. Occup. Safety Health, Cincinnati, Ohio.

Hamblin, D.O. (1949). Nitro and Amino Compounds of the Aromatic Series in *Industrial Hygiene and Toxicology*, (ed: F.A. Patty) Vol II, Interscience Publ. New York.

Harrison, M.R. (1977). Toxic methemoglobinemia — a case of acute nitrobenzene and aniline poisoning treated by exchange transfusion. *Anesthesia* 32:270-272.

Magos, L. and Sziza, M. (1959). Formation of Heinz bodies and change in hemoglobin. *Acta Haematol* 22:51-57

Nabarro, J.D.N. (1948). Case of acute mononitrobenzene poisoning. *Brit. Med. Jour.* 1:929-931.

Parkes, W.E. and Neill, D.W. (1953). Acute nitrobenzene poisoning with transient aminoaciduria. *Brit. Med. Jour.* 1:653-655.

Patanelli, D.J. (1975). Suppression of fertility in the male in *Handbook of Physiology*, (ed: D.W. Hamilton) pp. 245-258, Am. Phys. Soc., Washington, DC.

Ravault, P., Bouret, J., Roche, L. (1946). Two intoxications by nitrobenzene. *Arch. Mal. Prof. Med. Trav. Secur. Soc.* 7:305-310.

Sarin, K. and Saxena, A.K. (1978). Histopathological changes induced by quinalphos in the testes and liver of Indian dessert gerbils, *Meriones hurrianae* (Jerdon). *Toxicology* 9:255-260.

Shimkin, M.B. (1939). Acute toxocity of mononitrobenzene in mice. *Proc. Soc. Exp. Biol. Med.* 42:844-846.

Svoboda, D. and Reddy, J. (1975). Some effects of chemical carcinogens on cell organelles in *Cancer: A Comprehensive Treatise* (ed: F.F. Becker), Vol. 1, pp. 289-322, Plenum Press, New York.

Timme, A.H. (1974). Aspects of experimental hepatocarcinogenesis. *S. Afr. Med. S.* 148:698-700.

Wilkenfeld, R.M., Smith, F.A. and Garman, R.H. (1980). Effects of trifluoroethanol on the testis of the rat. Abstract Nineteenth Annual Meeting, Society of Toxicology, A17.

Zysk, J.R., Bushway, A.A., Whistler, R.L., and Carlton, W.W. (1975). Temporary sterility produced in male mice by 5-thio-D-glucose. *J. Reprod. Fert.* 45:69-72.