59342

FUNDAMENTAL AND APPLIED TOXICOLOGY 6, 697–712 (1986)

1/1/86

# The Subchronic Oral Toxicity of the β-Isomer of Hexachlorocyclohexane in Rats

F. L. VAN VELSEN,* L. H. J. C. DANSE,** F. X. R. VAN LEEUWEN,* J. A. M. A. DORMANS,** AND M. J. VAN LOGTEN†

*Laboratory of General Toxicology and **Laboratory of Pathology, National Institute of Public Health and Environmental Hygiene, Bilthoven, The Netherlands

The Subchronic Oral Toxicity of the β-Isomer of Hexachlorocyclohexane in Rats. VAN VELSEN, F. L., DANSE, L. H. J. C., VAN LEEUWEN, F. X. R., DORMANS, J. A. M. A., AND VAN LOGTEN, M. J. (1986). *Fundam. Appl. Toxicol.* 6, 697–712. The 13-week oral toxicity of β-HCH, a non-pesticidal isomer of hexachlorocyclohexane, was investigated in rats with doses of 0, 2, 10, 50, or 250 mg/kg feed. Parameters studied comprised clinical signs, growth and food intake, biochemistry, hematology, organ weights, and histopathology. In all dose groups liver effects comprising increase of organ weight, centrilobular hepatocytic hypertrophy, and proliferation of smooth endoplasmic reticulum or increased activity of microsomal enzymes, were observed. In the 50 mg/kg group the weights of thymus and testes were affected. In the highest dose group, progressive clinical signs leading to the unscheduled sacrifice of approximately 50% of the rats were observed. Moreover, in the males of this group atrophy of the testes, characterized by a reduced size of the seminiferous tubules and a decreased number of interstitial cells was observed in association with spermatogenic arrest. The females in this group showed atrophy of the ovaries with impaired oogenesis and focal hyperplasia and metaplastic changes of the endometrial epithelium. These effects are discussed with respect to a possible estrogenic action of β-HCH. © 1986 Society of Toxicology.

The β-isomer of hexachlorocyclohexane (β-HCH) is frequently encountered in studies on organochlorine residues in human blood (Eckenhausen *et al.*, 1981; Baumann *et al.*, 1980; Fukano and Doguchi, 1977; Yamaguchi *et al.*, 1976; Curley *et al.*, 1969) and tissues (Baumann *et al.*, 1980; Gupta *et al.*, 1980; Curley *et al.*, 1969). The occurrence of β-HCH among other contaminants in breast milk has been reviewed recently by Jensen (1983). The presence of the compound has been demonstrated in components of the human diet such as vegetables, meat, poultry, and fish (De Vos *et al.*, 1984). The German Scientific Society (Deutsche Forschungsgemeinschaft, 1983) has published a series of studies on the possible cause of the presence of HCH isomers in food and the relevance of it for public health. It was concluded that isomers of hexachlorocyclohexane differing from each other in spatial orientation of the chlorine atoms have entered the human food chain probably during the period in which a crude mixture of these isomers found widespread application as pesticide. Generally, the α-isomer was most prominent in the mixture, about 70%, whereas the β- and γ-isomers contributed about 12% each. The rest of the mixture consisted of small amounts of other compounds.

In 1973, the Joint Meeting of Experts on Pesticides of the Food and Agriculture Organization and of the World Health Organization recommended the use of purified γ-HCH being the only isomer with pesticidal properties (WHO, 1974). The application of the crude mixture has diminished strongly, since. Nevertheless, residues of the β-isomer are still detected in human tissues.

Relatively few chronic toxicity data of β-HCH have been published in literature (Hoff-

† Deceased.



0272-0590/86 $3.00
Copyright © 1986 by the Society of Toxicology.
All rights of reproduction in

9415

mann, 1983). In a chronic study with rats, Fitzhugh *et al.* (1950) observed that the lowest dose tested, 10 mg/kg feed, still induced an increase of liver weight and slight microscopic lesions in this organ, which were not specified. In their study, no increased tumor incidence was found. However, Thorpe and Walker (1973) observed an increased incidence of liver tumors due to β-HCH feeding in a 2-year study with mice. An evaluation of the risk of β-HCH with respect to public health has never been reported due to the lack of adequate toxicity data. The objective of the present 13-week feeding study with rats is to enlarge our knowledge of the toxicity of β-HCH.

## METHODS

Weanling SPF-derived Wistar Riv:TOX rats were littermate allocated to one control and four dose groups comprising 10 males and 10 females each. The animals were kept with two of equal sex in stainless-steel wire-mesh cages. Lighting regimen was 16 hr dark and 8 hr light. The ambient temperature was 22 ± 2°C and relative humidity was 50 ± 5%.

β-HCH (purity > 98%), generously supplied by Celamerck, Darmstadt, Federal Republic of Germany, was dissolved in ethylacetate (purity: pro analysi: E. Merck, Darmstadt, Federal Republic of Germany). Equal volumes of different concentrations of β-HCH were mixed with a semisynthetic, purified feed (Muracon SSP-Tox Standard flour obtained from Trouw, Co., Putten, The Netherlands). Ethylacetate was allowed to evaporate overnight. Final concentrations of β-HCH in the diet were: 0 (<0.01), 2, 10, 50, or 250 mg/kg. Analysis of diets showed recovery for β-HCH was approximately 90%. Diets and tap water from drinking bottles were available *ad libitum* for 13-weeks.

Individual body weights and food intake per cage were determined weekly. Animals were observed daily for clinical signs. At the end of the experiment, blood was collected from the retroorbital sinus under ether anesthesia. Hemoglobin concentration (Hb), packed cell volume (PCV), red (RBC), white blood cell concentration (WBC), and mean corpuscular volume (MCV) were measured with a Coulter Counter S-5. The other blood indices, mean corpuscular hemoglobin (MCH) and mean corpuscular hemoglobin concentration (MCHC) were calculated. White blood differentials and morphologic features of erythrocytes and thrombocytes were determined microscopically.

Ether anesthesized animals were euthanized by exsanguination from the abdominal aorta. A sample of blood was deproteinized with perchloric acid. In this sample the concentration of pyruvate and lactate was determined according to Annan (1975). Serum was used to determine the activity of alanine aminotransferase (ALAT; E.C. 2.6.1.2) and of aspartate aminotransferase (ASAT; [illegible] 2.6.1.1) according to published recommendations (Committee, 1974) using reagents from J. T. Baker Chemicals Ltd. (Deventer, The Netherlands). The activity of alkaline phosphatase (AP; E.C. 3.1.3.1) was measured according to Bessey *et al.* (1946). The concentration of urea was measured spectrophotometrically; following enzymatic hydrolysis, the rate of the reaction between the resulting ammonia and α-ketoglutarate to glutamate was measured via a fixed time method using Kit No. 166421 from Boehringer Mannheim Ltd. (Mannheim, Federal Republic of Germany). Total (TT4) and free (FT4) thyroxin [illegible]trations were determined by radioimmunoassay a[illegible]ng to Corning Medical (Medfield, Mass.). The concentration of the immunoglobulin classes G (IgG) and M (IgM) was measured according to Vos *et al.* (1982).

Following exsanguination, the liver was removed quickly and weighed. For the analysis of glycogen a 1% water-homogenized liver sample was used (Roehrig and Allred, 1974). The concentration of glucose formed in the assay was measured by reduction to gluconate. The resulting hydrogenperoxide was measured spectrophotometrically after reaction with a color reagent using GOD-P[illegible]est Kit No. 124028 from Boehringer Mannheim Ltd. [illegible]er liver sample was homogenized in 4 vol of 0.1 mol/liter phosphate buffer (pH 7.4) and centrifuged for 10 min at 10,000*g*. The supernatant was stored at −90°C for subsequent microsomal enzyme determinations. The supernatants were incubated according to a method based on Gram *et al.* (1968). The concentration of *p*-aminophenol formed upon incubation with aniline was measured as an indication of the aniline hydroxylase (AH) activity (Gilbert and Goldberg, 1965). The concentration of formaldehyde, the product of incubation with aminopyrin, was [illegible]d as an indication of the aminopyrin-*N*-de[illegible]ase (APDM) activity (Cochin and Axelrod, 1959). The concentration of cytochrome *P*-450 in the supernatant was measured according to Omura and Sato (1964). Protein analyses were carried out with a bovine serum albumin standard (Lowry *et al.*, 1951).

Following macroscopical inspection, heart, kidneys, spleen, thymus, adrenal glands, thyroid gland, pituitary gland, and testes, or ovaries and uterus were weighed and together with lungs, trachea, liver, pancreas, prostate, mesenterial, and popliteal lymph nodes, subm[illegible]ar salivary glands, stomach, intestines, urinary bl[illegible] skeletal muscle, bone, eyes, and skin were fixed in 10% phosphate-buffered Formalin. Intestines were fixed using the Swiss-roll technique (Moolenbeek and Ruitenberg, 1981). Brain, after weighing, spinal cord and sciatic nerve were fixed in 25% phosphate-buffered Formalin.

For histopathological investigations, 5 μm thick Paraplast sections were stained with haematoxylin and eosin (HE). In addition, PAS-staining for the detection of gly-

cogen and Von Kossa [illegible]
was carried out. For[illegible]
were stained with Oil [illegible]
Coded sections of live[illegible]
were evaluated.

Small blocks of live[illegible]
2 hr in 2% phosphate-b[illegible]
was in 1% Millonig's p[illegible]
for 1 hr. Following del[illegible]
tissues were embedde[illegible]
sections were stained w[illegible]
were cut with an LKB [illegible]
uranyl acetate and lead [illegible]
EM 201 or 400 electr[illegible]
The Netherlands).

Statistical analysis o[illegible]
test. The inhomogene[illegible]
with respect to the deg[illegible]
Significant results wer[illegible]

*General*

Two weeks fro[illegible]
two males and tw[illegible]
group showed ata[illegible]
inactive. Within 3[illegible]
clinical signs, the[illegible]
and were sacrifice[illegible]
total of five males[illegible]
est dose group ha[illegible]
were killed. In the[illegible]
abnormalities we[illegible]

*Body Weight Ga[illegible]*

In the highest d[illegible]
males gained les[illegible]
1 Weight gain [illegible]
after the first wee[illegible]
tion in growth of [illegible]
after the third we[illegible]
dose males was n[illegible]
controls. In the l[illegible]
gained significant[illegible]
trols. The food i[illegible]
also significantly[illegible]

cogen and Von Kossa staining for detection of calcification was carried out. Formalin-fixed frozen sections of liver were stained with Oil Red O (ORO) for detection of fat. Coded sections of liver (HE and ORO), kidney and spleen were evaluated.

Small blocks of liver tissue were fixed by immersion for 2 hr in 2% phosphate-buffered glutaraldehyde. Postfixation was in 1% Millonig's phosphate-buffered osmium tetroxide for 1 hr. Following dehydration in a graded ethanol series, tissues were embedded in Epon. One-micrometer thick sections were stained with toluidine blue. Ultrathin sections were cut with an LKB ultramicrotome, double-stained with uranyl acetate and lead citrate, and examined with a Philips EM 201 or 400 electron microscope (Philips, Eindhoven, The Netherlands).

Statistical analysis of data was performed with Student's test. The inhomogeneity of variances was corrected for with respect to the degrees of freedom according to Welch. Significant results were based upon two-tailed testing.

## RESULTS

### *General*

Two weeks from the start of the experiment, two males and two females in the highest dose group showed ataxia and became progressively inactive. Within 3 days from the onset of these clinical signs, the animals became comatose and were sacrificed. Later during the study, a total of five males and six females in the highest dose group had the same clinical signs and were killed. In the other dose groups no clinical abnormalities were observed.

### *Body Weight Gain and Food Consumption*

In the highest dose group, both females and males gained less weight than controls (Fig. 1). Weight gain of females was first reduced after the first week. While a significant reduction in growth of the males was first observed after the third week. Food intake in the high dose males was not different from that in the controls. In the lower dose groups, the males gained significantly more weight than the controls. The food intake of these animals was also significantly higher than that of control males. The same effects were also observed with the females of the lowest dose group.

### *Hematology*

RBC, Hb, and PCV determined at the end of the experiment were significantly lower in both males and females of the highest dose group than in control animals (Table 1). Furthermore, the animals in this group showed an increase in the concentration of anisoplanic and polychromatic corpuscules and of mesochromatic and orthochromatic erythroblasts compared to the control group.

The WBC in the highest dose group was lower for both sexes than in the control groups; this was primarily due to decrease of the concentration of lymphocytes (Table 1). Females in all other dose groups showed a lower concentration of neutrophilic granulocytes than those in the control group. This granulocytopenia was not dose dependent.

### *Biochemistry*

Biochemical determinations did not reveal treatment-related changes in ASAT, ALAT, or AP activities or in the concentrations of urea, IgG, and IgM in serum. The concentrations in lactate and pyruvate were numerically lower with a dose-dependent trend in treated groups versus controls with exception of the males of the highest dose group (not shown). This difference was statistically significant only for the lactate concentration of males in the 50 mg/kg group. The mean concentrations of TT4 and FT4 of males in the highest dose group were significantly lower than in the control group (not shown).

Hepatic glycogen concentration in the high dose males was significantly higher than in the control rats (Table 2). Compared to the control group, a significantly higher activity of the microsomal enzymes AH and APDM and a higher concentration of cytochrome *P*-450 were noted in the highest dose group (Table 2). The 50 mg/kg group of males also had higher APDM activity than controls. APDM

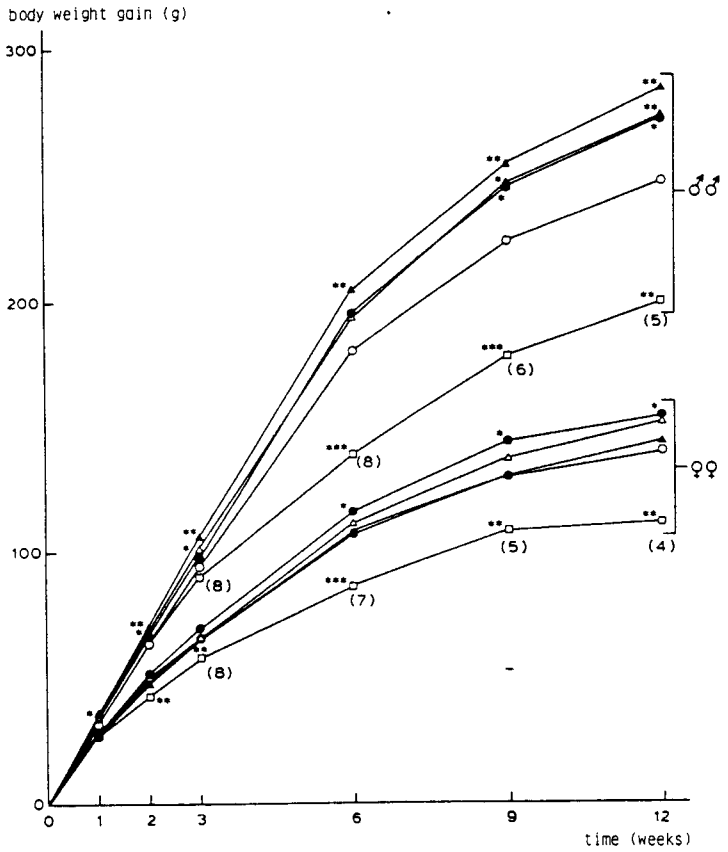


FIG. 1. Mean body weight gain of rats ($n$ = 10) during a 13-week feeding study with the $\beta$-isomer of hexachlorocyclohexane ($\beta$-HCH). (○) control; (●) 2 mg $\beta$-HCH/kg feed; (△) 10 mg $\beta$-HCH/kg feed; (▲) 50 mg $\beta$-HCH/kg feed; (□) 250 mg $\beta$-HCH/kg feed; *$0.01 \leq p < 0.05$; **$0.001 \leq p < 0.01$; ***$p < 0.001$; ( ) $n \neq 10$.

activity was elevated in high dose females compared to controls.

*Autopsy Data*

In females (Table 3), the weights of liver, kidneys, thymus, adrenal glands, uterus, and ovaries were affected by $\beta$-HCH. There was a dose-dependent increase in absolute and relative liver weights and a non-dose-dependent increase in absolute and relative weights of the kidneys and adrenal glands. Thymus weight was decreased in the two highest dose groups. The weights of the uterus and of the ovaries were higher in the 10 mg/kg group and markedly lower in the high dose group compared to the controls.

In males (Table 4), primarily, the weights of liver, kidneys, thymus, adrenal glands, pituitary gland, and testes were affected by $\beta$-HCH. The weights of liver and kidneys in the 10 mg/kg group and higher were dose dependently higher than in the control group. The thymus weight in the two highest dose groups was less, compared to the control group. In the highest dose group, the weights [illegible] adrenal glands and the pituitary gland were markedly higher, whereas the weight of the testes was significantly lower than that in the control group.

Upon macroscopic examination atrophy of the testes and prostate and of the ovaries in all animals of the highest dose group was observed.

TABLE 1

HEMATOLOGIC PARAMETERS OF RATS AT THE END OF A 13-WEEK FEEDING STUDY WITH THE $\beta$-ISOMER OF HEXACHLOROCYCLOHEXANE

| | Lymphocytes | Neutrophils |
|---|---|---|

TABLE I

HEMATOLOGIC PARAMETERS OF RATS AT THE END OF A 13-WEEK FEEDING STUDY WITH THE β-ISOMER OF HEXACHLOROCYCLOHEXANE

| β-HCH[a] (kg/feed) | N[b] | RBC[c] ($10^{12}$/liter) | Hb[d] (mmol/liter) | PCV[e] (l/liter) | WBC[f] ($10^6$/liter) | Neutrophils ($10^6$/liter) | Lymphocytes ($10^6$/liter) |
|---|---|---|---|---|---|---|---|
| Females | | | | | | | |
| 0 | 10 | 8.24 ± 0.53[g] | 9.5 ± 0.4 | 0.46 ± 0.02 | 9680 ± 1492 | 866 ± 374 | 8498 ± 1447 |
| 2 | 10 | 8.38 ± 0.47 | 9.8 ± 0.7 | 0.46 ± 0.02 | 9550 ± 2228 | 553 ± 255[h] | 8723 ± 2259 |
| 10 | 10 | 8.21 ± 0.34 | 9.6 ± 0.4 | 0.45 ± 0.01 | 9440 ± 2062 | 450 ± 185[k] | 8681 ± 1920 |
| 50 | 10 | 8.22 ± 0.27 | 9.6 ± 0.3 | 0.46 ± 0.02 | 8770 ± 1776 | 454 ± 196[i] | 8039 ± 1681 |
| 250 | 3 | 7.29 ± 0.20[h] | 8.6 ± 0.3[i] | 0.40 ± 0.01[k] | 7467 ± 1436[h] | 619 ± 316 | 6462 ± 1183[h] |
| Males | | | | | | | |
| 0 | 10 | 8.72 ± 0.47 | 9.9 ± 0.3 | 0.47 ± 0.02 | 11260 ± 1806 | 654 ± 188 | 10257 ± 1519 |
| 2 | 10 | 8.86 ± 0.57 | 9.9 ± 0.4 | 0.46 ± 0.02 | 10780 ± 1158 | 638 ± 214 | 9830 ± 1098 |
| 10 | 10 | 8.64 ± 0.46 | 9.9 ± 0.3 | 0.47 ± 0.02 | 11830 ± 2204 | 567 ± 349 | 10979 ± 1926 |
| 50 | 10 | 8.88 ± 0.33 | 10.1 ± 0.2 | 0.47 ± 0.01 | 11320 ± 2828 | 792 ± 358 | 10212 ± 2585 |
| 250 | 5 | 7.71 ± 0.21[k] | 8.8 ± 0.4[k] | 0.42 ± 0.02[k] | 7000 ± 1261[k] | 371 ± 75[i] | 6282 ± 1073[k] |

[a] β-HCH: β-isomer of hexachlorocyclohexane.
[b] N: number of animals.
[c] RBC: concentration of erythrocytes.
[d] Hb: concentration of haemoglobin.
[e] PCV: packed cell volume.
[f] WBC: concentration of leucocytes.
[g] Mean ± SD.
[h] $0.01 \leq p < 0.05$.
[i] $0.001 \leq p < 0.01$.
[k] $p < 0.001$.

TABLE 2

GLYCOGEN CONTENT, MICROSOMAL ENZYME ACTIVITIES AND CONCENTRATION CYTOCHROME *P*-450 IN LIVER OF RATS AT THE END OF A 13-WEEK FEEDING STUDY WITH THE β-ISOMER OF HEXACHLOROCYCLOHEXANE

| β-HCH[a] (kg/feed) | Glycogen (mg/g liver) | AH[b] | APDM[c] | Cyt *P*-[illegible] (nmol/g protein) |
|---|---|---|---|---|
| Females | | | | |
| 0 | 18 ± 6[e] | 5.6 ± 2.9 | 5.3 ± 3.0 | 109 ± 82 (7)[f] |
| 2 | 22 ± 13 | 5.7 ± 1.9 | 5.2 ± 1.7 | 90 ± 27 (9) |
| 10 | 32 ± 24 | 4.5 ± 1.7 | 4.8 ± 1.5 | 82 ± 26 (6) |
| 50 | 25 ± 12 | 6.1 ± 1.4 (9) | 6.2 ± 1.1[h] (9) | 97 ± 17 (6) |
| 250 | 25 ± 18 (4) | 5.6 ± 1.0 (4) | 12.0 ± 0.5[h] (4) | 303 ± 294 (4) |
| Males | | | | |
| 0 | 24 ± 6 | 3.6 ± 1.0 | 5.5 ± 2.2 | 80 ± [illegible] (8) |
| 2 | 22 ± 14 (9) | 4.6 ± 1.0[g] (9) | 7.0 ± 2.1 (9) | 87 ± [illegible] (7) |
| 10 | 24 ± 11 | 4.0 ± 1.2 | 5.9 ± 2.2 | 84 ± 21 (5) |
| 50 | 26 ± 17 | 4.7 ± 1.3[h] | 8.3 ± 3.1[g] | 123 ± 61[h] (6) |
| 250 | 35 ± 4[h] (5) | 5.7 ± 1.2[h] (5) | 12.1 ± 2.5[i] (5) | 169 ± 49[h] (5) |

[a] β-HCH: β-isomer of hexachlorocyclohexane.
[b] AH: anilinehydroxylase activity (μmol *p*-aminophenol/30 min/g protein).
[c] APDM: aminopyrin-*N*-demethylase activity (μmol formaldehyde/30 min/g protein).
[d] Cyt *P*-450: cytochrome *P*-450.
[e] Mean ± SD.
[f] ( ): $n \neq 10$.
[g] $0.01 \leq p < 0.05$.
[h] $0.001 \leq p < 0.01$.
[i] $p < 0.001$.

*Microscopic Studies*

The incidence of relevant microscopic lesions in various organs is given in Table 5. In the two highest dose groups, distinct changes in the liver were detected. In the centrilobular regions, hypertrophic hepatocytes with hyaline eosinophilic cytoplasm and enlarged nuclei (polyploidy) were observed. An increased number of mitoses was detected, and occasionally cell necrosis and Kupffer cell hyperactivity was present. Hyaline cytoplasm is usually indicative of proliferation of smooth endoplasmic reticulum. This phenomenon was confirmed by electron microscopy. Periportal cells were small with cytoplasmic vacuolization characteristic for glycogen accumulation. An increased number of glycogen rosettes was observed by electron microscopy. The extent of these effects was dose related. In the two lowest dose groups, a small number of males showed slight centrilobular effects. In the highest dose group, a larger degree of periportal and diffuse fat accummulation was observed. In kidneys of males in the highest dose group, calcinosis in the outer medull[illegible] detected. This feature is usually observ[illegible] only in females. With the exception of the early death animals, spleens of animals in the highest dose group showed an increase of extramedullar hematopoiesis. Some of these rats showed also a slight to moderate depletion of lymphoid tissue of the spleen. The thymus of rats in the highest dose group had cortical atrophy due to lymphocyte depletion. Hypertrophy of the adrenal cortex was p[illegible]nt in high dose rats (Fig. 2). This hypertrophy was mainly a result of enlarged cells in the zona reticularis. In the highest dose group, atrophy of testes characterized by atrophy of seminiferous tubules and disturbance of normal spermatogenesis was observed (Fig. 3). Syncytia of

TABLE 3

BODY AND ORGAN WEIGHTS OF FEMALE RATS AT THE END OF A 13-WEEK FEEDING STUDY WITH THE β-ISOMER OF HEXACHLOROCYCLOHEXANE

| | β-HCH[a] (mg/kg feed) | | | | |
|---|---|---|---|---|---|
| | 0 | 2 | 10 | 50 | 250 |
| Number of animals | 10 | 10 | 10 | 10 | 4 |
| Body weight (g) | 194 ± 21[b] | 204 ± 19 | 204 ± 21 | 197 ± 12 | 164 ± 17[c] |
| Absolute | | | | | |
| Liver (g) | 5.6 ± 0.8 | 6.2 ± 0.9 | 6.4 ± 0.8[c] | 6.7 ± 0.7[d] | 10.5 ± 1.5[e] |
| Kidneys (g) | 1.3 ± 0.2 | 1.5 ± 0.1[d] | 1.5 ± 0.1[d] | 1.5 ± 0.1[c] | 1.4 ± 0.1 |
| Spleen (mg) | 357 ± 64 | 392 ± 70 | 396 ± 78 | 412 ± 61 | 318 ± 98 |
| Thymus (mg) | 324 ± 87 | 327 ± 55 | 336 ± 60 | 264 ± 47 | 124 ± 45[d] |
| Adrenal gl. (mg) | 41 ± 5 | 47 ± 5[c] | 49 ± 8[c] | 45 ± 7 | 68 ± 17[c] |
| Pituitary gl. (mg) | 11 ± 2 | 13 ± 2[c] | 12 ± 2 | 12 ± 2 | 11 ± 1 |
| Uterus (mg) | 279 ± 71 | 340 ± 73 | 345 ± 68[c] | 319 ± 86 | 254 ± 12 |
| Ovaries (mg) | 56 ± 10 | 61 ± 19 | 73 ± 17[c] | 57 ± 14 | 24 ± 7[e] |
| Ratio to body weight ($\% \times 10^{-2}$) | | | | | |
| Liver | 286 ± 19 | 305 ± 29 | 316 ± 12[e] | 338 ± 27[e] | 640 ± 81[e] |
| Kidneys | 68 ± 5 | 75 ± 6[c] | 75 ± 5[d] | 75 ± 16[c] | 85 ± 12[c] |
| Spleen | 18 ± 2 | 19 ± 2 | 19 ± 2 | 21 ± 3[c] | 19 ± 4 |
| Thymus | 17 ± 4 | 16 ± 2 | 16 ± 2 | 13 ± 2[c] | 7 ± 2[e] |
| Adrenal gl. | 2.1 ± 0.3 | 2.3 ± 0.2 | 2.4 ± 0.4 | 2.3 ± 0.4 | 4.2 ± 1.4[c] |
| Pituitary gl. | 0.6 ± 0.1 | 0.6 ± 0.1 | 0.6 ± 0.1 | 0.6 ± 0.1 | 0.7 ± 0.1 |
| Uterus | 14 ± 3 | 17 ± 4 | 17 ± 3 | 16 ± 4 | 16 ± 3 |
| Ovaries | 2.9 ± 0.5 | 3.0 ± 0.5 | 3.6 ± 0.7[c] | 2.9 ± 0.8 | 1.4 ± 0.4[e] |

[a] β-Isomer of hexachlorocyclohexane.
[b] Mean ± SD.
[c] $0.01 \leq p < 0.05$.
[d] $0.001 \leq p < 0.01$.
[e] $< 0.001$.

degenerated spermatids were seen. In addition, the number of interstitial cells was markedly decreased. In females of the highest dose group, an atrophy of the ovaries was found with absence of corpora lutea, but presence of Graafian follicles (Fig. 4). The ovaries from the interim death high dose animals were normally developed with all stages of oogenesis including corpora lutea being present. In the uterus of several rats, the endometrium epithelium was hyperplastic and strongly vacuolized (Fig. 5). Glandular tubules were dilated. In two of the four terminally killed females, squamous metaplasia of endometrium epithelium was observed (Fig. 5). All other tissues and organs were without treatment-related lesions.

## DISCUSSION

This 13-week feeding study with β-HCH, a non-pesticidal isomer of hexachlorocyclohexane, was designed to extend our knowledge of the toxicity of this compound which is present in human food and human tissues. The doses used in this study were derived from the lowest dose tested in a chronic feeding study by Fitzhugh *et al.* (1950), 10 mg/kg feed, showing slight hepatotoxic signs. For the subchronic

TABLE 4

BODY AND ORGAN WEIGHTS OF MALE RATS AT THE END OF A 13-WEEK FEEDING STUDY WITH THE β-ISOMER OF HEXACHLOROCYCLOHEXANE

| | β-HCH[a] (mg/kg feed) | | | | |
|---|---|---|---|---|---|
| | 0 | 2 | 10 | 50 | 250 |
| Number of animals | 10 | 10 | 10 | 10 | 5 |
| Body weight (g) | 304 ± 30[b] | 327 ± 26 | 328 ± 19[c] | 336 ± 24[c] | 257 ± 21[d] |
| Absolute | | | | | |
| Liver (g) | 8.7 ± 1.3 | 9.6 ± 1.2 | 10.0 ± 1.0[c] | 10.8 ± 1.8[d] | 14.3 ± [illegible][e] |
| Kidneys (g) | 1.9 ± 0.2 | 2.0 ± 0.1 | 2.1 ± 0.2 | 2.3 ± 0.2[e] | 2.0 [illegible] |
| Spleen (mg) | 479 ± 88 | 480 ± 53 | 534 ± 79 | 574 ± 104[c] | 566 ± 96 |
| Thymus (mg) | 380 ± 63 | 388 ± 57 | 438 ± 82 | 339 ± 53 | 169 ± 28[e] |
| Adrenal gl. (mg) | 41 ± 7 | 48 ± 7[c] | 48 ± 5[c] | 48 ± 6[c] | 94 ± 11[e] |
| Pituitary gl. (mg) | 10 ± 2 | 11 ± 1 | 11 ± 1 | 12 ± 2[c] | 13 ± 2[c] |
| Testes (g) | 2.6 ± 0.2 | 2.6 ± 0.2 | 2.5 ± 0.5 | 2.6 ± 0.2 | 1.0 ± 0.4[e] |
| Ratio to body weight ($\% \times 10^{-2}$) | | | | | |
| Liver | 286 ± 21 | 293 ± 31 | 305 ± 26 | 320 ± 39[c] | 557 ± 61[e] |
| Kidneys | 62 ± 4 | 62 ± 2 | 63 ± 3 | 68 ± 3[d] | 79 ± 9[d] |
| Spleen | 16 ± 2 | 15 ± 2 | 16 ± 2 | 17 ± 2 | 22 [illegible][e] |
| Thymus | 13 ± 2 | 12 ± 2 | 13 ± 3 | 16 ± 1[d] | 7 [illegible] |
| Adrenal gl. | 1.4 ± 0.2 | 1.5 ± 0.2 | 1.4 ± 0.1 | 1.4 ± 0.2 | 3.7 ± 0.7[e] |
| Pituitary gl. | 0.3 ± 0.0 | 0.3 ± 0.0 | 0.3 ± 0.0 | 0.4 ± 0.0 | 0.5 ± 0.1[e] |
| Testes | 85 ± 8 | 79 ± 8 | 77 ± 15 | 77 ± 7[c] | 38 ± 16[e] |

[a] β-Isomer of hexachlorocyclohexane.
[b] Mean ± SD.
[c] $0.01 \leq p < 0.05$.
[d] $0.001 \leq p < 0.01$.
[e] $p < 0.001$.

study, one lower dose and two higher doses than 10 mg/kg were chosen on an arithmetical scale.

In the highest dose group, 250 mg/kg feed, progressive clinical signs were noted which led to early autopsy of about 50% of the animals in this group. These signs were unexpected as the LD50 in the rat was more than 10,000 mg/kg body wt (Hoffmann, 1983). On the other hand, Fitzhugh *et al.* (1950) noted in a chronic feeding study that the mean age of death of rats fed 800 mg/kg feed was 4.4 ± 1.3 weeks. The observed signs which were indicative for severe CNS-depression might be related to the amount of β-HCH in the brain. Portig and Vohland (1983) noted various stages of CNS-depression in relation to the β-HCH content of the brain. These authors showed that coma occurred at levels of approximately 50 mg/kg wet tissue or higher. In two of the comatose males in our experiment, the concentration of β-HCH in the brain was almost 80 mg/kg (Greve, unpublished data). The variability of the CNS depression was remarkably high as some animals showed depressive signs after 2 weeks of treatment, whereas others remained without effects during the 13 weeks of the study.

Besides the clinical signs, various other effects were observed in the highest dose group. The slightly but significantly lower RBC, Hb, and PCV, in association with a higher concentration of immature red blood cells and the increased extramedullar hematopoiesis in

TABLE 5

INCIDENCE OF RELEVANT HISTOPATHOLOGICAL AND HISTOCHEMICAL LESIONS IN TISSUES AND ORGANS OF RATS AT THE END OF A 13-WEEK FEEDING STUDY WITH THE β-ISOMER OF HEXACHLOROCYCLOHEXANE

| | Dose (mg β-HCH[a]/kg feed) | | | | | | | | | | | |
|---|---|---|---|---|---|---|---|---|---|---|---|---|
| | 0 | | 2 | | 10 | | 50 | | 250 | | 250[b] | |
| Number of animals | 10 | 10 | 10 | 10 | 10 | 10 | 10 | 10 | 4 | 5 | 6 | 5 |
| Sex | ♀ | ♂ | ♀ | ♂ | ♀ | ♂ | ♀ | ♂ | ♀ | ♂ | ♀ | ♂ |
| Liver (*N*) | 10 | 10 | 10 | 10 | 10 | 10 | 10 | 10 | 4 | 5 | 5 | 4 |
| Hyalinization of centrilobular cells | | | | 3 | | 4 | | 3 | 4 | 4 | 2 | 2 |
| Increase of mitoses | | 1 | | | | | 2 | | 2 | 4 | 2 | 3 |
| Focal liver cell necrosis | | | | | | | | 1 | | 1 | | |
| Kupffer cell hyperactivity | | | | | | | | | | | 2 | |
| Liver (oil red O) (*N*) | 5 | 5 | | | | | 5 | 5 | 4 | 5 | | |
| Periportal fat accumulation | 3 | 4 | | | | | 5 | 4 | 3 | 5 | | |
| Diffuse fat accumulation | 2 | 1 | | | | | | | | 1 | | |
| Kidney (*N*) | 10 | 10 | | | | | 10 | 10 | 4 | 4 | 6 | 5 |
| Calcinosis in outer medulla | 10 | | | | | | 7 | | 4 | 4 | 3 | 5 |
| Spleen (*N*) | 10 | 10 | | | | | 10 | 9 | 4 | 5 | 6 | 4 |
| Increased extramedullar hematopoiesis | | | | | | | | | 2 | 5 | | |
| Adrenal glands (*N*) | 9 | 10 | | | 10 | 9 | 10 | 10 | 4 | 5 | 6 | 5 |
| Cortical hypertrophy | | | | | | | | | 3 | 5 | 2 | 2 |
| Thymus (*N*) | 10 | 10 | | | 10 | 10 | 10 | 10 | 3 | 5 | 6 | 5 |
| Cortical atrophy | | | | | | | | | 3 | 4 | 2 | 2 |
| Testis (*N*) | | 10 | | | | 10 | | 10 | | 5 | | 5 |
| Atrophy of seminiferous tubulus | | | | | | | | | | 5 | | 5 |
| Decrease of interstitial cells | | | | | | | | | | 4 | | 3 |
| Ovaries (*N*) | 9 | | | | 10 | | 10 | | 4 | | 5 | |
| Atrophy | | | | | | | | | 4 | | 1 | |
| Uterus (*N*) | 9 | | | | 10 | | 10 | | 4 | | 6 | |
| Epithelial hyperplasia | | | | | | | | | 3 | | 1 | |
| Epithelial metaplasia | | | | | | | | | 2 | | | |
| Dilated endometrial glands | | | | | | | | | 1 | | 2 | |

[a] β-HCH: β-isomer of hexachlorocyclohexane.
[b] Intercurrently autopsied animals.

the spleen, point toward anemia. Although this effect was mild and is a more or less common feature for the highest dose group in toxicity studies, it is considered to be of toxicological relevance and related to the exposure of β-HCH. The observed lymphoid depletion of thymus and spleen could be the cause of the reduction of the lymphocytes. As no myelograms were prepared, the involvement of bone marrow could not be established.

The lower concentration of circulating thyroid hormone in absence of effects on thyroid weight and morphology might be caused by a reduction of the tropic stimulus of the organ from the pituitary gland. As neither this stimulus nor the peptide hormone producing cells

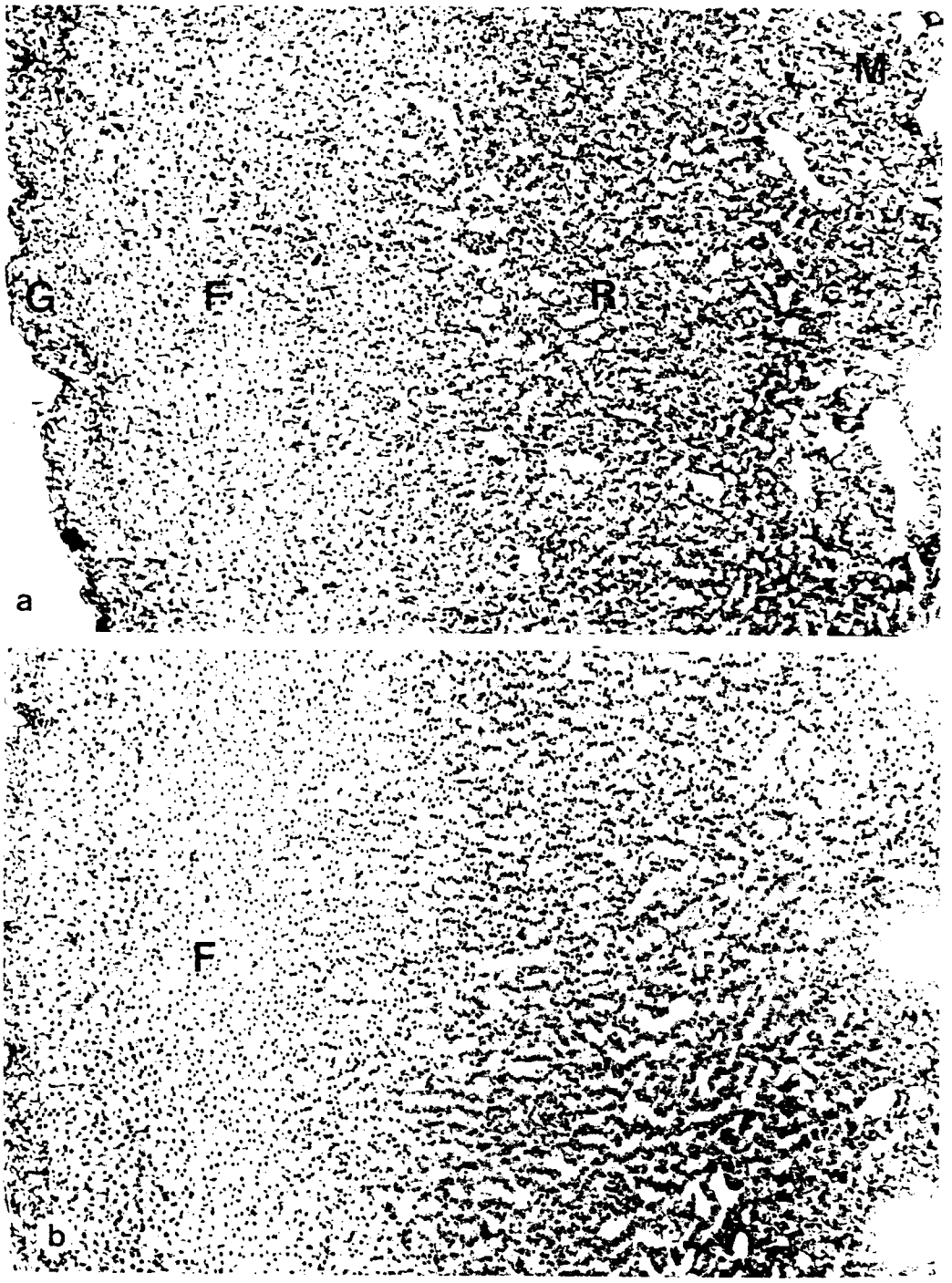


FIG. 2. Adrenal gland of rat of the control group (a) and of the highest dose group (b) with cortical hypertrophy mainly caused by enlargement of cells of the zona reticularis (R). Visible are also zona fasciculata (F), zona glomerulosa (G) and adrenal medulla (M). HE × 87.




FIG. 3. Testis
spermatogenesis
of seminiferous

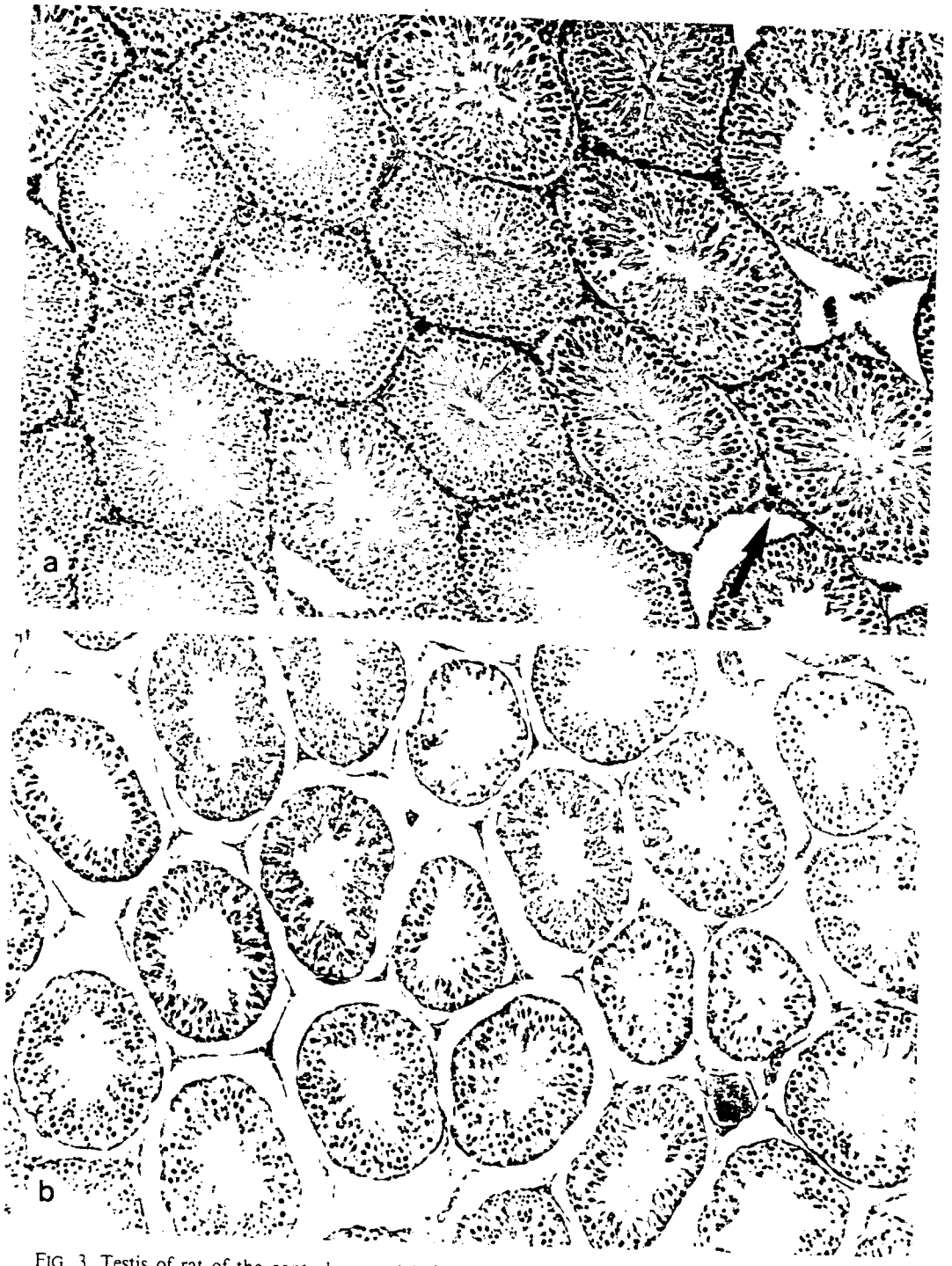


FIG. 3. Testis of rat of the control group (a) showing normal seminiferous tubules with all stages of spermatogenesis and interstitial cells (arrow) and of animal of the highest dose group (b) with clear atrophy of seminiferous tubules and decreased number of interstitial cells. HE × 87.

FIG. 4. Ovary of rat of the control group (a) showing all stages of follicles and corpora lutea (C) and atrophic ovary of animal of the highest dose group (b) in which corpora lutea are absent. HE × 35.

of the adenohypophyse were investigated, this effect remains open for further study.

The weights of several organs were significantly affected. The retarded growth of the males caused some non-specific effects on organ weights. However, on basis of the relative

FIG. 5. Uterus
squamous metapl

organ weights it is
liver, kidneys, th
gonads. The high

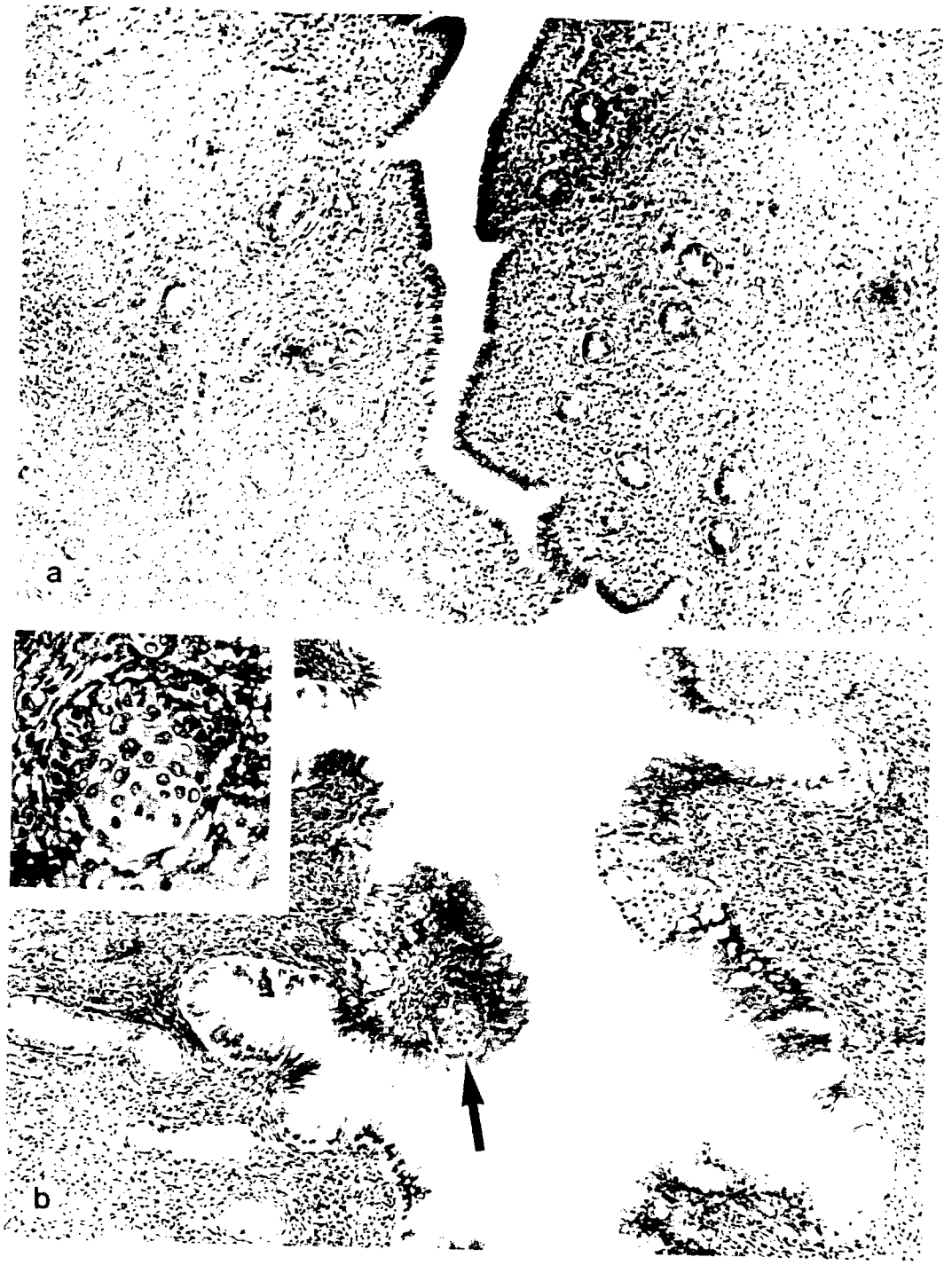


FIG. 5. Uterus of rat of the control group (a) and of the highest dose group (b) with hyperplasia and squamous metaplasia (arrow) of endometrium epithelium. HE × 87. Inset: detail of metaplastic focus ×219.

organ weights it is clear that β-HCH affected li er, kidneys, thymus, adrenal glands, and gonads. The higher liver weights can be explained by enzyme induction which was concluded from both biochemical assays and histopathological and ultrastructural studies. This

hepatotoxic effect concurs with that observed by Fitzhugh *et al.* (1950). The higher kidney weights cannot be explained by biochemical studies or histopathological observations. It is improbable that the observed calcinosis in the kidney medulla of all males in this group, which phenomenon was absent in control males, could contribute to the weight effect.

The lower thymus weight can be explained by the observed cortical atrophy. This atrophy coincided with a lymphopenia and the depletion of splenic lymphoid tissue in some animals of this group. The higher weights of the adrenal glands are probably caused by hypertrophy of cortical cells. This hypertrophy was almost exclusively confined to cells of the zona reticularis. Since neither steroid hormone levels nor levels of adrenocorticotropic hormone were measured, the significance of this hypertrophy remains open for further investigations. Interestingly, Shivanandappa and Krishnakumari (1981, 1983) reported similar increased weights of adrenal glands and hypertrophy of cortical cells in a 90-day feeding study with a dose of 1500 mg technical HCH/kg. This technical HCH contained 5% of the $\beta$-isomer rendering an exposure to 75 mg $\beta$-HCH/kg feed. Since unpublished 13-week feeding studies with $\alpha$- and $\gamma$-HCH carried out in our institute did not show any effect on the adrenal glands, it is likely that the adrenal effects in the studies of Shivanandappa and Krishnakumari are caused by the $\beta$-isomer of the HCHs. From the HE-sections of the pituitary gland no indications could be obtained for the observed enlargement in the males of the two highest dose groups.

Both in males and females, the gonads weighed significantly lower than in the control group and were atrophic. In the testes, this atrophy was characterized by a reduced size of the seminiferous tubules, a lower number of Leydig cells, and an almost complete absence of the spermatogonia. These histopathological effects were also present in the interim death animals. Therefore, a poor physical condition of the animals cannot be excluded as a cause for the atrophy of the testes. On the other hand, Shivanandappa and Krishnakumari (1981, 1983) also observed testicular atrophy and spermatogenic failure in their subchronic feeding study with technical H[illegible]. These authors did not report about a poor physical condition or unscheduled deaths. They concluded that 1500 mg technical HCH/kg feed containing 5% $\beta$-HCH had anti-androgenic effects. In the female animals, the ovaries of the intercurrently killed animals appeared to be normally developed and showed all stages of the oogenesis. Therefore, it is not likely that the atrophy of the o[illegible]s in the terminally killed animals is due [illegible] poor condition. Moreover, the uterus of the terminally killed animals showed endometrial hyperplasia and metaplastic changes and not atrophy. The absence of the corpora lutea in the ovaries of the terminally killed females is indicative for an inhibitory action of $\beta$-HCH on the ovulation. In combination with the hyperplastic lesions in the uterus, this ph[illegible]menon resembles the effects of the long-[illegible]posure to estrogens (Kramer and Gu[illegible]zel, 1979). Furthermore, also in the males, some effects can be explained in view of an exposure to estrogens, e.g., the testicular atrophy, the nephrocalcinosis which is usually seen in females only (Table 5) and is thought to be estrogen mediated (Geary and Cousin, 1969), and the lower levels of thyroid hormone as estrogens have been reported to lo[illegible] thyroxin and pituitary thyroid stim[illegible]ng hormone (Boado *et al.*, 1983). The nature of the present study, however, does not enable us to draw definite conclusions about a possible estrogenic effect of $\beta$-HCH. The fact that the compound has slight but distinct uterotropic activity in juvenile intact rats and mice (Loeber and Van Velsen, 1984) supports this tentative conclusion. Moreover, in [illegible] *Poecilia reticulata* (guppy) induc[illegible] vitellogenesis was observed in both sexes (Wester *et al.*, 1985). This effect is characteristic for estrogenic activity in lower vertebrates.

In the 50 mg/kg group, no histopathological effects are detected except for signs of enzyme induction in the liver, although, the weights of the kidneys, the thymus, and the testes were affected like in the highest dose gro[illegible] In the

lowest dose groups, slight changes indicative for liver enzyme induction were observed in some animals.

Therefore, the general conclusion in this subchronic study is that β-HCH induced liver enzyme induction in a dose of 2 mg/kg feed and higher. In a dose of 50 mg/kg feed and higher, the compound affected lymphoid and endocrine organs. In the highest dose tested, besides neurologic signs leading to the death of almost 50% of the animals, several effects indicative for an estrogenic action of β-HCH were observed. The study of the mechanism of this possible action will be objective for further investigations.

## ACKNOWLEDGMENT

This study was supported by the (Chief) Inspectorate for Food Stuffs. The authors gratefully acknowledge the assistance of Ms. A. J. M. Kromwijk and M. J. E. van Doyen in typing the manuscript. The authors are indebted to Ms. M. E. M. Geleijnse, Mrs. K. de Jong, F. M. Broere, J. van Soolingen, J. M. van Nimwegen, P. K. Beekhof, and M. Paques for their technical skill in the hematological, biochemical, histological, and biotechnical activities. Dr. J. G. Loeber and Dr. P. A. Greve are thanked for their cooperation in the hormonal and analytical assays, respectively, and Dr. J. G. Vos for his critical remarks and encouragement during the study and the writing of the manuscript.

## REFERENCES

ANNAN, W. (1975). A method for the determination of blood lactate and pyruvate using an LKB 8600 reaction rate analyzer. *Med. Lab. Techn.* **32**, 287–294.

BAUMANN, K., ANGERER, J., HEINRICH, R., AND LEHNERT, G. (1980). Occupational exposure to hexachlorocyclohexane. I. Body burden of HCH-isomers. *Int. Arch. Occup. Environ. Health* **47**, 119–127.

BESSEY, O. A., LOWRY, O. H., AND BROCK, M. J. (1946). A method for the rapid determination of alkaline phosphatase with five cubic millimeters of serum. *J. Biol. Chem.* **164**, 321–329.

BOADO, R., ULLAO, E., AND ZANINOVICH, A. A. (1983). Effects of oestradiol benzoate on the pituitary-thyroid axis of male and female rats. *Acta Endocrinol. (Copenh.)* **102**, 386–391.

COCHIN, J., AND AXELROD, J. (1959). Biotechnical and pharmacological changes in the rat following chronic administration of morphine, nalorphine and normorphine. *J. Pharmacol. Exp. Ther.* **125**, 105–110.

Committee on Enzymes of the Scandinavian Society for Clinical Chemistry and Clinical Physiology (1974). Recommended methods for the determination of four enzymes in blood. *Scand. J. Clin. Lab. Invest.* **33**, 291–306.

CURLEY, A., COPELAND, M. F., AND KIMBROUGH, R. D. (1969). Chlorinated hydrocarbon insecticides in organs of stillborns and blood of newborn babies. *Arch. Environ. Health* **19**, 628–632.

Deutsche Forschungsgemeinschaft (1983). *Hexachlorocyclohexan als Schadstoff in Lebensmitteln* (H-J. Hapke, ed.), Verlag Chemie, Weinheim.

DE VOS, R. H., VAN DOKKUM, W., OLTHOF, P. D. A., QUIRIJNS, J. K., MUYS, T., AND VAN DER POLL, J. M. (1984). Pesticides and other chemical residues in Dutch total diet samples (June 1976–July 1978). *Fd. Cosmet. Toxicol.* **22**, 11–21.

ECKENHAUSEN F. W., BENNET, D., BEYNON, K. I., AND ELGAR, K. E. (1981). Organochlorine pesticide concentrations in perinatal samples from mothers and babies. *Arch. Environ. Health* **36**, 81–92.

FITZHUGH, O. G. NELSON, A. A., AND FRAWLEY, J. P. (1950). The chronic toxicities of technical benzene hexachloride and its alpha, beta and gamma isomers. *J. Pharmacol. Exp. Ther.* **104**, 59–66.

FUKANO, S., AND DOGUCHI, M. (1977). PCT, PCB and pesticide residues in human fat and blood. *Bull. Environ. Contam. Toxicol.* **17**, 613–617.

GEARY, C. P., AND COUSIN, F. B. (1969). An oestrogen-linked nephrocalcinosis in rats. *Brit. J. Exp. Pathol.* **50**, 507–515.

GILBERT, D., AND GOLBERG, L. (1965). Liver response tests. III. Liver enlargement and stimulation of microsomal processing enzyme activity. *Fd. Cosmet. Toxicol.* **3**, 417–432.

GRAM, T. E., WILSON, J. T., AND FOUTS, J. R. (1968). Some characteristics of hepatic microsomal systems which metabolize aminopyrine in the rat and rabbit. *J. Pharmacol. Exp. Ther.* **159**, 172–181.

GUPTA, S. K., NEENA, S., PATEL, J. S., CHATTERJEE, S. K., AND KASHYAP, S. K. (1980). Organochlorine insecticide residues in fat of people from urban centres in India. I. *Pesticides* **14**, 13.

HOFFMANN, A. (1983). Toxizitaet von alpha- und beta-HCH. In *Hexachlorocyclohexan als Schadstoff in Lebensmitteln* (H-J. Hapke, ed.), pp. 201–205. Verlag Chemie. Weinheim.

JENSEN A. A. (1983). Chemical contaminants in human milk. *Res. Rev.* **89**, 1–128.

KRAMER, M., AND GUENZEL, P. (1979). The proof of drug effects on endocrine glands of endocrine target organs by means of toxicological investigations. *Pharmacol. Ther.* **5**, 287–297.

LOEBER, J. G., AND VAN VELSEN, F. L. (1984). Uterotropic effect of beta-HCH, a food contaminant. *Food Add. Contam.* **1**, 63–66.

LOWRY, O. H., ROSEBROUGH, N. J., FARR, A. L., AND RANDELL, R. J. (1951). Protein measurement with the Folin phenol reagent. *J. Biol. Chem.* **193**, 265–275.

MOOLENBEEK, C., AND RUITENBERG, E. J. (1981). The Swiss roll: A simple technique for histological studies of the rodent intestine. *Lab. Anim.* **15,** 57–59.

OMURA, T., AND SATO, R. (1964). The carbon-monoxide binding pigment of liver microsomes. I. Evidence for its hemoprotein nature. *J. Biol. Chem.* **239,** 2370–2378.

PORTIG, J., AND VOHLAND, H. W. (1983). Neuropharmakologische und neurotoxische Wirkungen von Hexachlorocyclohexan (HCH). In *Hexachlorocyclohexan als Schadstoff in Lebensmitteln* (H-J. Hapke, ed.), pp. 215–226. Verlag Chemie. Weinheim.

ROEHRIG, K. L., AND ALLRED, J. B. (1974). Direct enzymatic procedure for the determination of liver glycogen. *Anal. Biochem.* **58,** 414–421.

SHIVANANDAPPA, T., AND KRISHNAKUMARI, M. K. (1981). Histochemical and biochemical changes in rats fed dietary benzene hexachloride. *Indian J. Exp. Biol.* **19,** 1163–1168.

SHIVANANDAPPA, T., AND KRISHNAKUMARI, M. K. (1983). Hexachlorocyclohexane-induced testicular dysfunction in rats. *Acta Pharmacol. Toxicol.* **52,** 12–17.

THORPE, E., AND WALKER, A. I. T. (1973). The toxicity of dieldrin (HEOD). II. Comparative long-term oral toxicity studies in mice with dieldrin, DDT, phenobarbitone, beta-BHC and gamma-BHC. *Fd. Cosmet. Toxicol.* **11,** 433–442.

VOS, J. G., KRAJNC, E. I., AND BEEKHOF, P. K. (1982). Use of the enzyme-linked-immunosorbent assay (ELISA) in immunotoxicity testing. *Environ. Health Persp.* **43,** 115–121.

WESTER, P. W., CANTON, J. H., AND BISSCHOP, A. (1985). Histopathological study of Poecilia reticulata (guppy) after long term beta-hexachlorocyclohexane exposure. *Aquatic Toxicol.* **6,** 271–296.

WHO Pesticide Residue Series, no. 3 (1974). *Evaluations of Some Pesticide Residues in Food.* 57. World Health Organization Geneva, Switzerland.

YAMAGUCHI, S., KAKU, S., KUWAHARA, Y., AND YAMADA, A. (1976). Epidemiological findings and evaluation of the amount of organochlorine pesticides in human blood plasma in Japan. *Arch. Environ. Contam. Toxicol.* **3,** 448–460.



The Effec

CATHER

*IIT Research Instit
Toxicology Branch. He

The Effects
ARANYI, C.,
6, 713–720. T
of acetaldehy
allyl chloride
monochlorob
work room a
posures were
induced strep
*pneumoniae.*
performed a
Multiple exp
increases in
exposure to T
For methyler
icantly decre

Increasing attentio
identification and
lutants found in t
pational settings.
are being introdu
ketplace, many of
halation hazard.
used in this study
a list of potential
undergoing risk as
1981 production v
various compoun
mately 50,000 to
national Trade C
better assess the r
those already kno
formation is neede

[1] Presented in part a
Society of Toxicology,
[2] To whom correspo