0923

TOXICOLOGY AND APPLIED PHARMACOLOGY 86, 131–139 (1986)

Ref

Regression of Methyl Bromide-Induced Forestomach Lesions in the Rat

G. A. BOORMAN,* H. L. HONG,* C. W. JAMESON,† K. YOSHITOMI,‡ AND R. R. MARONPOT*

*Chemical Pathology Branch and †Carcinogenesis and Toxicology Evaluation Branch, National Toxicology Program, National Institute of Environmental Health Sciences, P.O. Box 12233, Research Triangle Park, North Carolina 27709, and ‡Department of Pathology, Toxicology Division, Research Laboratories, Fujisawa Pharmaceutical Company, Osaka, Japan

Received April 14, 1986; accepted June 24, 1986

Regression of Methyl Bromide-Induced Forestomach Lesions in the Rat. BOORMAN, G. A., HONG, H. L., JAMESON, C. W., YOSHITOMI, K., AND MARONPOT, R. R. (1986). *Toxicol. Appl. Pharmacol.* **86**, 131–139. There is continuing concern about the role of irritation in cancer development. Methyl bromide, a widely used fumigant and known irritant reported to cause forestomach carcinomas in rats, was dissolved in peanut oil and given by gavage at 50 mg/kg body wt to Wistar rats five times per week for 13 to 25 weeks. Starting at Week 13, methyl bromide administration was discontinued for half of the methyl bromide-treated rats (stop treatment group). After that, rats from both the continuous treatment and stop treatment groups were terminated at 4-week intervals to follow the progression of the stomach lesions. Forestomach lesions were not found in control rats receiving peanut oil and killed at 13 or 25 weeks. At 13 weeks the forestomachs from rats receiving methyl bromide were contracted and adherent to the liver and spleen. Inflammation, acanthosis, fibrosis, and a high incidence of pseudoepitheliomatous hyperplasia were found microscopically in treated animals. At 25 weeks, 100% of the rats receiving methyl bromide continuously had hyperplastic lesions of the forestomach which were more severe than those at 13 weeks. Evidence of malignancy was seen in one rat and the lesion was considered a very early carcinoma. In the stop treatment group that received methyl bromide for 13 weeks, there was regression of the stomach lesions, but at the 12-week final sacrifice, adhesions, fibrosis, and mild acanthosis remained. This study illustrates the need for regression experiments for complex forestomach lesions in rodents, especially when an irritating chemical is given by gavage. © 1986 Academic Press, Inc.

Methyl bromide (Ch_3Br, bromomethane) is a colorless gas at ambient temperatures and currently is widely used as a fumigant for soils, grains, and other food commodities stored in warehouses and mills (Alexeeff and Kilgore, 1983; Roosels *et al.*, 1981). Approximately 1.8 million tons of methyl bromide are produced annually in the United States (USDA, 1978). Most human occupational exposure to methyl bromide is by inhalation (Hine, 1969; Greenberg, 1971).

Recent findings of CH_3Br in both food and drinking water led to an oral gavage study in rats where induction of squamous cell carcinomas of the forestomach was reported (Danse *et al.*, 1984). There was disagreement regarding the malignant nature of these lesions when the histological slides from that study were reviewed (Anonymous, 1984).

The difficulty of distinguishing some cases of marked hyperplasia from neoplasia, the chance to follow regression of lesions, and the importance of Ch_3Br led us to design an augmented study similar to that reported by Danse *et al.* (1984). To better characterize the proliferative response induced in the forestomach by CH_3Br, stop treatment groups were included to study the progression or the regression of the lesions. In the present study groups of male Wistar rats were either treated

0041-008X/86 $3.00
Copyright © 1986 by Academic Press, Inc.
All rights of reproduction in any form reserved.

9433

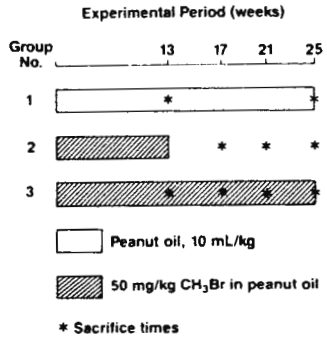

FIG. 1. Dosing and sacrifice schedule for 15 rats per scheduled necropsy.

with methyl bromide for 13 weeks with a 12-week recovery period or treated with methyl bromide for the entire 25-week study period.

METHODS

Methyl bromide was obtained in a single lot from Mathesson Gas Products (East Rutherford, N.J.). The study material was received in a single gas lecture bottle and indicated to be >99% pure by the supplier. The peanut (arachis) oil used for this study was supplied by Durkee Foods (Strongsville, Ohio). Gavage-dosing solutions were prepared by bubbling methyl bromide through the peanut oil until the appropriate weight of the study chemical had dissolved to give 5 mg/ml concentrations. Because of the volatile nature of CH_3Br, aliquots prepared weekly for each day's dosing were kept in tightly capped vials with no head space. Concentrations of the methyl bromide dosing solutions were verified both before and after dosing to ensure that the proper dose was being given to the rats. The methyl bromide dosing solutions were administered by gavage five times a week for 13, 17, 21, and 25 weeks at a dose of 50 mg/kg body wt. The administered volume was 10 ml/kg body wt. Controls received 10 ml/kg peanut oil five times a week for 13 and 25 weeks.

Six-week-old male Wister Rats (Charles River Wistar) weighing 105 to 120 g were assigned randomly to either control or treatment groups. There were a total of nine groups, and each contained 15 animals. The rats were housed two per polycarbonate shoe-box cage. The temperature was 70 ± 5°F, relative humidity 50 ± 10%, and there was a 12-hr light–dark schedule. NIH 07 open formula rodent chow and water was available *ad libitum*. Body weights were taken at the start of the study, and weekly thereafter. The animals were observed daily. Animals found dead were necropsied but tissues were not saved.

Scheduled necropsies were at 13, 17, 21, and 25 weeks following initiation of treatment (Fig. 1). All gross lesions plus lung, liver, esophagus (mid-cervical and lower thoracic areas), and stomach were fixed in 10% buffered formalin. The stomach was opened on the greater curvature, flattened, and fixed while attached to a piece of cardboard. Sections taken lateral and parallel to the lesser curvature included both glandular and nonglandular stomach. Five-micron sections were prepared and stained with hematoxylin and eosin. The tissues examined included gross lesions, left lobe of lung, left lateral lobe of liver, transverse section of esophagus at mid-cervical and lower thoracic areas, and four sections of stomach. The stomach sections were examined independently by two of the authors (G. A. Boorman and R. R. Maronpot). The stomach lesions were graded using a 4-point grading system with 1 being minimal, 2 mild, 3 moderate, and 4 marked. Any discrepancies of diagnosis were resolved by a panel of pathologists who reviewed the lesions in a blind fashion, i.e., not knowing the treatment group or previous diagnosis.

RESULTS

Statistical Analysis

The Student's *t* test was employed to assess the significance of treatment effects within two groups. For comparison of more than two groups the Wilk–Shapiro test was used to

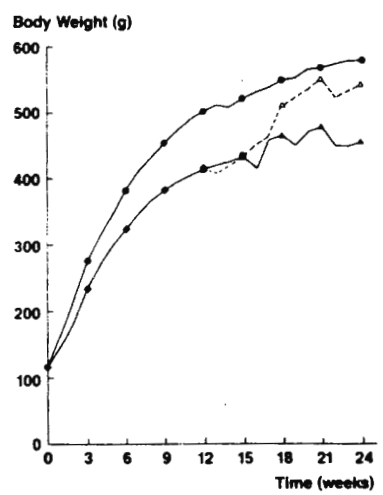

FIG. 2. Mean body weights of rats treated with peanut oil or methyl bromide 50 mg/kg body wt, dissolved in peanut oil. ●, Peanut oil vehicle, $N = 30$; ■, all methyl bromide rats during first 13 weeks, $N = 135$; △, rats allowed to recover; ▲, rats continued on methyl bromide.

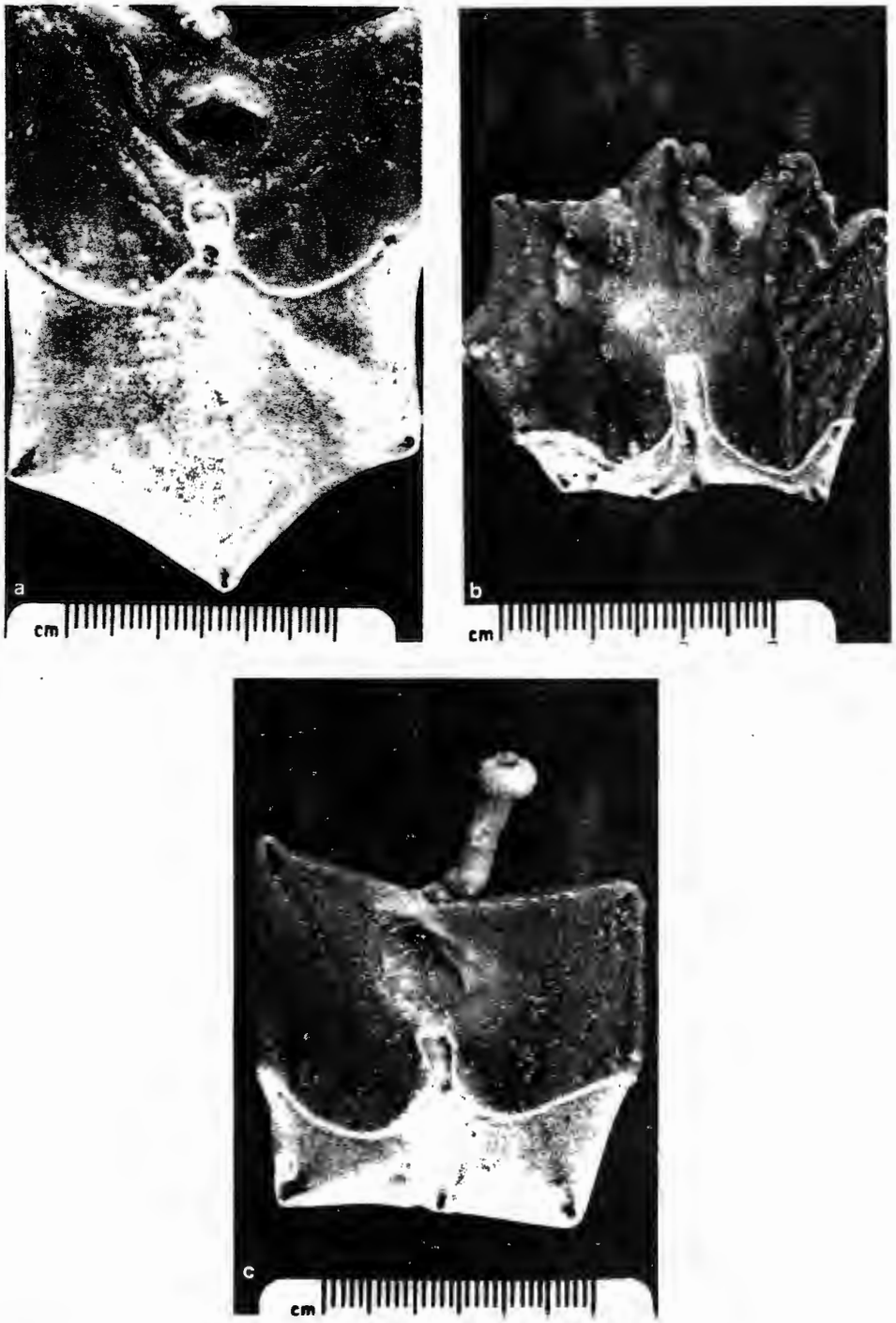

FIG. 3. (a) Stomach of rat receiving peanut oil by gavage for 13 weeks. (×1.5) (b) Stomach of rat receiving 50 mg/kg body wt methyl bromide in peanut oil for 13 weeks. Note contracture of forestomach. (×1.5) (c) Stomach of rat receiving 50 mg/kg body wt of methyl bromide in peanut oil for 13 weeks and allowed to recover for 12 weeks. (×1.9)

TABLE 1

PATHOLOGY SUMMARY TABLE FOR MALE RATS ADMINISTERED METHYL BROMIDE BY GAVAGE IN PEANUT OIL

Weeks of treatment:	13		17		21		25		
Treatment group:[a]	Control	MB	MB-stop	MB	MB-stop	MB	Control	MB-stop	MB
Site/diagnosis:	12[b]	13	10	14	14	10	13	9	11
Nonglandular stomach									
Hemorrhage	1[c]	2	0	0	0	0	0	0	0
Acute inflammation	1	0	1	0	0	0	0	0	0
Chronic inflammation	0	5*	1	3	2	8**	0	0	3*
Fibrosis	0	5*	0	3	2	9**	0	4**	6**
Acanthosis	0	3	2	4	3	0	2	2	1
Pseudoepitheliomatous hyperplasia	0	11**	2	11**	3	10**	0	0	11**
Keratinic cyst	0	2	0	2	1	2	0	1	0
Squamous cell carcinoma	0	0	0	0	0	0	0	0	1
Glandular stomach									
Lymphocytic infiltrate	0	2	2	8	0	9**	1	1	8**
Esophagus									
Chronic inflammation	0	0	0	0	0	2	0	1	4*

[a] Continuous methyl bromide (MB), stop treatment (MB-stop).
[b] Number of animals examined histologically.
[c] Number of animals with diagnosis.
* $p < 0.05$ vs control; ** $p < 0.01$ vs control.

determine normality and Levene's test was used for homogeneity of variances. Data that did not meet the criteria of a normal population were tested by the one-way Kruskal–Wallis multiple-comparison test. Data that were normal were analyzed by one-way ANOVA and Dunnett's test for multiple comparison with a control group (Beranek and Newman, 1983).

Chemistry

The study chemical used in this research was identified as methyl bromide by infrared spectroscopy. The purity of the study chemical was determined by gas chromatography to be approximately 99.5%. Dosing solutions were analyzed by dilution with *n*-heptane and flame ionization gas chromatography of the resultant solution. Preliminary stability studies of methyl bromide/peanut oil solutions (5 mg/ml) were conducted and demonstrated that dosing solutions were stable for up to 4 weeks when stored with no headspace at ambient temperature. Analysis of 10 samples resulted in a mean methyl bromide concentration of 5.2 ± 0.2 mg/ml (range 4.9–5.4). In addition, representative samples of dosing solutions were taken after dose administrations and analyzed for methyl bromide content. In all cases the postdosing analysis results were consistent with the predosing analysis of the same sample and verified that the rats received the target concentration (5 mg/ml) of methyl bromide.

Body Weight Gain

Methyl bromide exposure caused a significant reduction in weight gain and the animals continued to weigh less than controls (Fig. 2). When the methyl bromide treatment was stopped at Week 13, rats continued to gain slowly until Week 17 at which time a weight gain differential was apparent between rats on continued methyl bromide treatment and those in the recovery group. At Week 25

FIG. 4. Pseudoepitheliomatous hyperplasia in forestomach of rat receiving methyl bromide, 50 mg/Kg body wt in peanut oil for 17 weeks. Note marked epithelial thickening, acanthosis, and epithelial pegs. (×40)

the continuous treatment group weighted significantly less than the stop treatment group ($p < 0.05$).

Gross Lesions

Animals that died early usually had an oily substance in the lung or periesophageal area, indicating gavage error. Histological examination was not performed on these animals. Two scheduled sacrifice rats, one control and one treated, had subcutaneous and periesophageal abcesses that were considered to be related to gavage error. In the control animals no other significant lesions were found.

FIG. 5. Epithelial pegs showing well-differentiated cells. A mild inflammatory response is present. (×200)

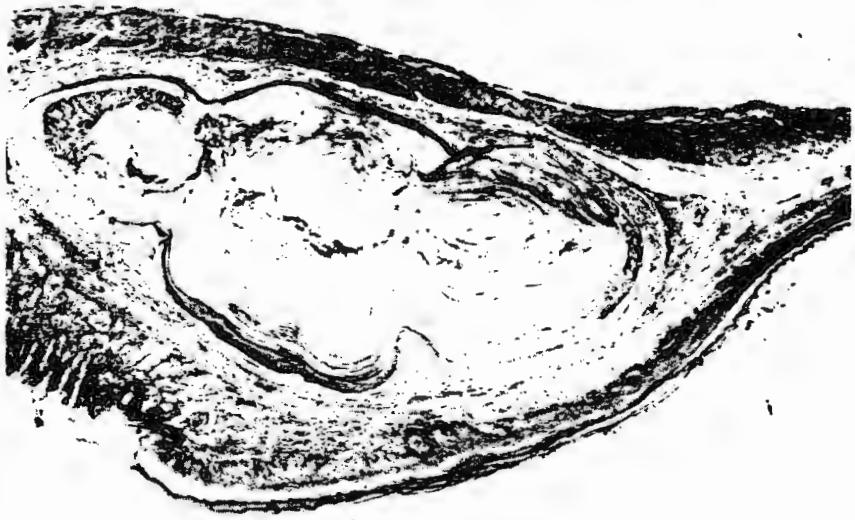

FIG. 6. Keratinic cyst in the forestomach of a rat treated with 50 mg/kg body wt of methyl bromide. Cyst filled with keratin and lined by flattened squamous epithelium. (×44)

In the rats that had been gavaged with methyl bromide for 13 weeks, there were numerous abdominal adhesions. Generally, the forestomach at the greater curvature was adherent to the liver, spleen, and/or diaphragm. When the stomach was opened, the mucosal surface often had 2–4 mm white umbilicated lesions. The forestomach was extremely con-

FIG. 7. Forestomach of a rat treated with 50 mg/kg body wt of methyl bromide for 13 weeks and allowed to recover for 12 weeks. Hyperplastic lesions not present. (×40)

TABLE 2

INCIDENCE AND SEVERITY OF NONGLANDULAR STOMACH LESIONS IN MALE RATS TREATED WITH METHYL BROMIDE BY GAVAGE

Groups[b]	Inflammation[a]	Fibrosis	Acanthosis	Hyperplasia
13-week sacrifice				
Control	8.0 (1)	0 (0)	0 (0)	0 (0)
MB	38.5 (1.8)	38.5* (2.4)	23.1 (1.3)	84.6** (1.6)
17-week sacrifice				
MB-stop	20.0 (2.5)	0 (0)	20 (1)	20 (1)
MB	21.4 (1.7)	21.4 (2.3)	28.6 (1.2)	78.6** (1.7)
21-week sacrifice				
MB-stop	14.3 (1.5)	14.3 (1.0)	21.4 (1)	21.4 (1.0)
MB	80.0** (1.1)	90.0** (2.0)	0 (0)	100** (2.1)
25-week sacrifice				
Control	0 (0)	0 (0)	15.4 (1.0)	0 (0)
MB-stop	0 (0)	44.4** (1.0)	22.2 (1.0)	0 (0)
MB	27.3* (1.3)	54.5** (1.7)	9.1 (1.0)	100** (2.4)

[a] Percentage affected, with mean degrees of severity in parentheses.
[b] Methyl bromide continuous treatment (MB), stop treatment (MB-stop).
* $p < 0.05$ vs control; ** $p < 0.01$ vs control.

tracted and it was impossible to stretch the forestomach for fixation as was done for the controls (Figs. 3a, b). Methyl bromide-treated animals sacrificed at Weeks 17, 21, and 25 showed similar changes. In the stop treatment recovery group, the peritoneal adhesions were still present but the stomach was less contracted (Fig. 3c).

Microscopic Findings

Methyl bromide exposure was associated with inflammation, fibrosis, acanthosis, and pseudoepitheliomatous hyperplasia of the forestomach (Table 1). By 25 weeks' continued exposure, mild acanthotic lesions were found in the lower esophagus. Acanthosis was considered the mildest form of epithelial response with focal to diffuse increase in the thickness of the squamous epithelium. The pseudoepitheliomatous hyperplasia was characterized by epithelial peg formation and accompanied by hyperkeratosis and acanthosis (Fig. 4). The basal portion of these lesions consisted of well-differentiated epithelial cells with an orderly maturation (Fig. 5). Mitotic figures were common. These hyperplastic lesions were often associated with marked submucosal fibrosis and infiltration of lymphocytes and macrophages. In some treated animals a round white nodule 2–4 mm in diameter was often seen near the junction of glandular and nonglandular stomach. Histologically these were keratinic cysts (Fig. 6). When methyl bromide exposure was discontinued the epithelium of the forestomach had fewer cell layers than that of continuous treatment rats (Fig. 7) and the incidence of hyperplastic lesions was lower. The severity of inflammation and fibrosis diminished. One animal treated with CH_3Br for 25 weeks had a severe dysplastic lesion with a relatively high mitotic activity. This lesion ws considered to represent an early carcinoma (Fig. 8). When reviewed by over 12 experienced pathologists in the Research Triangle Park area, the majority opinion was for carcinoma, although some favored dysplasia.

DISCUSSION

Rodent forestomachs may show a marked proliferative response to an irritant with

FIG. 8. An area of early carcinoma. Cells are hyperchromatic and invade the submucosa. There does not appear to be invasion of the muscle layer. (×140)

downgrowth of epithelial cells into the submucosa that does not represent cancer (Bucher *et al.*, 1928). Conversely many compounds that are forestomach carcinogens do produce irritation to the forestomach (Ghanayem *et al.*, 1985a,b). The acrylate ester concentration in ethyl acrylate and the lipophilicity of the dose vehicle appear important in the induction of hyperplastic lesions (Ghanayem *et al.*, 1985b). A relationship between acute forestomach irritation and squamous cell carcinomas has been reported for aristolochic acid given by gavage (Mengs, 1983) and by butylated hydroxyanisole given in the feed (Ito *et al.*, 1982). It has been postulated that "induction of abnormally high levels of cell proliferation in a tissue provides a favorable environment for the development of cancer" (Ito *et al.*, 1982). Recent work suggests that carcinogens induce a high rate of proliferation while some noncarcinogens fail to induce this response (Ghanayem *et al.*, 1986a). Administration of 2% BHA in the diet for 2 years led to forestomach carcinoma (Ito *et al.*, 1982, 1983). When BHA is fed for 13 weeks and then withdrawn, the labeling index in the forestomach epithelium and the proliferative lesions tend to return to normal levels (Iverson *et al.*, 1985). In another study, 4-week treatment with BHA induced forestomach lesions that regressed when treatment was discontinued (Altmann *et al.*, 1985). Similarly ethyl acrylate-induced gastric lesions regress when treatment is discontinued (Ghanayem *et al.*, 1986b). This suggests that the induction of forestomach carcinoma is both time- and dose-dependent. It would appear that a similar situation exists for methyl bromide. The lesions seen at 13 weeks did not appear sufficient to warrant a diagnosis of carcinoma which prompted us to design a similar type experiment. In our studies we saw lesions that were very similar to the figures in the Danse article (1984). When methyl bromide treatment was stopped, these lesions appeared to regress since they were not seen in the rats killed 4, 8, or 12 weeks following cessation of treatment. This argues against the malignant nature of the lesions. Hubbs and Harrington (1985) found similar results in their study where rats treated by gavage with methyl bromide at 25 and 50 mg/kg body wt for 90 days had hyperplastic lesions that regressed in a 60-day recovery period. In the Hubbs and Harrington (1985) study, rats treated for up to 120 days had no evidence of malignancy. In our study, treatment with methyl bromide 50 mg/kg body wt for 25 weeks resulted in one lesion that was considered to represent early carcinoma. While one tumor is not statistically significant, the implications of a tumor in a young rat in the target tissue cannot be ignored.

ACKNOWLEDGMENTS

The authors thank Steve Preissler and Brad Collins, who prepared and analyzed the dosing solutions of methyl bromide at Radian Corporation, Morrisville,

N.C., under NIEHS Contract ES45043. The authors also thank Kevin Denny for managing animal care and dosing and for help at necropsy, and Doris Meyers for gross photography. Finally, the authors thank Dr. Grisham for a critical review of the manuscript and selected lesions.

REFERENCES

ALEXEEFF, G. V., AND KILGORE, W. W. (1983). Methyl bromide. *Residue Rev.* **88,** 101.

ALTMANN, H. J., WESTER, P. W., MATTHIASCHK, G., GRUNOW, W., AND VAN DER HEIJEN, C. A. (1985). Induction of early lesions in the forestomach of rats by 3-tert-butyl-4-hydroxyanisole (BHA). *Food Chem. Toxicol.* **23,** 723–731.

ANONYMOUS (1984). No evidence of methyl bromide carcinogenicity found by NTP panel. *Pestic. Toxicol. Chem. News* **13,** 9–10.

BOLT BERANEK AND NEWMAN, INC. (1983). RS/1 integrated data analysis system for the professional 350 Users' Guide. Book 2: Graphics and Statistics, Vol. 8, pp. 1–30.

BÜCHER, F., SIEBERT, P., AND MOLLOY, P. J. (1928). Über experimentell erzeugte akute peptische Geschwurr des Rattenvormagens. *Beitr. Pathol. Anat. Allg. Pathol.* **81,** 391–425.

DANSE, L. H. J. C., VAN VELSEN, F. L., AND VAN DER HEIJDEN, C. A. (1984). Methylbromide: Carcinogenic effects in the rat forestomach. *Toxicol. Appl. Pharmacol.* **72,** 262–271.

GHANAYEM, B. I., MARONPOT, R. R., AND MATTHEWS, H. B. (1985a). Ethyl acrylate-induced gastric toxicity. I. Effect of single and repetitive dosing. *Toxicol. Appl. Pharmacol.* **80,** 323–335.

GHANAYEM, B. I., MARONPOT, R. R., AND MATTHEWS, H. B. (1985b). Ethyl acrylate-induced gastric toxicity. II. Structure–toxicity relationship and mechanism. *Toxicol. Appl. Pharmacol.* **80,** 336–344.

GHANAYEM, B. I., MARONPOT, R. R., AND MATTHEWS, H. B. (1986a). Forestomach cell proliferation is a common effect of repetitive gavage dosing with forestomach chemical carcinogens. *Cancer Lett.*, in press.

GHANAYEM, B. I., MARONPOT, R. R., AND MATTHEWS, H. B. (1986b). Ethyl acrylate-induced gastric toxicity. III. Development and recovery of lesions. *Toxicol. Appl. Pharmacol.* **83,** in press.

GREENBERG, J. O. (1971). The neurological effects of methyl bromide poisoning. *Ind. Med.* **40,** 27–29.

HINE, C. H. (1969). Methyl bromide poisoning. *J. Occup. Med.* **11,** 1–10.

HUBBS, A. F., AND HARRINGTON, D. D. (1985). Further evaluation of the potential gastric carcinogenic effects of subchronic methyl bromide administration. Amer. College of Vet. Pathol., Dec. 3–5, Denver, Colo. (abstract).

ITO, N., HAGIWARA, A., SHIBATA, M., OGISO, T., AND FUKUSHIMA, S. (1982). Induction of squamous cell carcinoma in the forestomach of F344 rats treated with butylated hydroxyanisole. *GANN* **73,** 332–334.

ITO, N., FUKUSHIMA, S., HAGIWARA, A., SHIBATA, M., AND OGISO, T. (1983). Carcinogenicity of butylated hydroxyanisole in F344 rats. *J. Natl. Cancer Inst.* **70,** 343–349.

IVERSON, F., LOK, E., NERA, E., KARPINSKI, K., AND CLAYSON, D. B. (1985). A 13-week feeding study of butylated hydroxyanisole's the subsequent regression of the induced lesions in male Fischer 344 rat forestomach epithelium. *Toxicology* **35,** 1–11.

MENGS, U. (1983). On the histopathogenesis of rat forestomach carcinoma caused by aristolochic acid. *Arch. Toxicol.* **52,** 209–220.

ROOSELS, D., VAN DEN OEVER, R., AND LAHAGE, D. (1981). Dangerous concentrations of methyl bromide used as a fumigant in Belgium greenhouses. *Int. Arch. Occup. Environ. Health* **48,** 243.

United States Department of Agriculture (USDA) (1978). *The Pesticide Review*, p. 32.