LANL Ref

1216

SETAC PRESS

Environmental Toxicology and Chemistry, Vol. 21, No. 1, pp. 81–86, 2002
Printed in the USA
0730-7268/02 $9.00 + .00

INFLUENCE OF DIETARY 2,4,6-TRINITROTOLUENE EXPOSURE IN THE NORTHERN BOBWHITE (*COLINUS VIRGINIANUS*)

ROBERT M. GOGAL, JR.,*† MARK S. JOHNSON,‡ CALVERT T. LARSEN,† MARY R. PRATER,† ROBERT B. DUNCAN,† DANIEL L. WARD,† and STEVEN D. HOLLADAY†

†Virginia–Maryland Regional College of Veterinary Medicine, Blacksburg, Virginia 24061, USA
‡U.S. Army Center for Health Promotion and Preventive Medicine, Aberdeen Proving Ground, Maryland 21010-5403

(*Received 9 March 2001; Accepted 5 June 2001*)

Abstract—The risk to wildlife from exposure to the explosive, 2,4,6-trinitrotoluene (TNT) has been a concern at numerous military installations where it has been found in the soil. To date, no published data are available describing effects of TNT exposure in an avian species. Subchronic dietary exposure to TNT was therefore evaluated in a species of management concern at military installations, the northern bobwhite (*Colinus virginianus*). Adult male and female quail ($n \approx 5$/sex/dose) were given commercial feed containing 3,000, 1,500, 750, and 100 mg/kg TNT for 90 d following the determination of an acute lethal dose and a 14-d range finding study. Dietary TNT intake caused a dose-dependent decrease in total red blood cell counts, packed cell volume, total plasma protein, blood prolymphocytes, and blood lymphocytes. An increased trend in late apoptotic/necrotic blood leukocytic cells was also observed in TNT-exposed birds, as was hemosiderosis in the liver. With the exception of hemosiderosis, these trends were statistically significant yet of questionable biological significance. Since treatment-related responses in this preliminary study were variable, a conservative interpretation is suggested. However, since these treatments had concentrations that were a log-fold or more than doses in similar studies using mammals, these data suggest that northern bobwhite are less sensitive to oral exposures of TNT than mammals.

Keywords—Quail Oral exposure 2,4,6-Trinitrotoluene *Colinus virginianus* Immunotoxicity

INTRODUCTION

The use, manufacturing, and assembling of high explosives during the last century have resulted in considerable contamination of soil and surface water at many U.S. Army installations [1–3]. Primary constituents of these defense-related contaminants are 2,4,6-trinitrotoluene (TNT) and its potential degradation products [2,3]. As a result, there is a need for investigating the potential adverse effects of environmental TNT exposures on indigenous wildlife species [4–6]. A variety of avian species are known to inhabit heavily contaminated sites; however, there have been no reported evaluations of the effects of TNT exposure in birds.

The effects of oral TNT exposure in laboratory mammals have been well documented [7–9]. Reported acute effects range from central nervous system (CNS)-related neuromuscular ataxia to red-colored urine (chromatouria) [7]. With subacute to subchronic dosing regimens, neuromuscular effects, erythrolytic anemia, hepatic and splenic pathology, and testicular atrophy were observed [7–8]. Similar observations have been made in laboratory studies utilizing wildlife mammalian species and exposure to TNT, with indicators of anemia being the most consistent findings [4,6,10]. Given the physiological differences between mammals and birds, it is unclear if these mammalian data will be predictive of effects in birds following exposure to TNT. To address this, the present study accordingly examined a panel of hematologic and other known sensitive indicators of stress in northern bobwhite exposed to TNT in feed.

MATERIALS AND METHODS

Animals

The initial parent stock of in-bred northern bobwhite quail (*Colinus virginianus*) was acquired from an independent breeder (Richard Orr Farms, Doswel, VA, USA). Breeding flocks were established at the Avian Medicine facility at the Center for Molecular Medicine and Infectious Disease, Virginia–Maryland Regional College of Veterinary Medicine, Virginia Tech, Blacksburg, Virginia, USA. New bird hatches from the parental stock were used for this study. Quail were housed individually in specially built 36 cage pair quail units (Alternative Design, Siloam Springs, AR, USA). Tap water was provided ad libitum by an automated watering system that was checked daily. Fifty birds (25 males and 25 female) were weighed, banded, and divided into five groups (five males and five females) after a four-week quarantine period. Throughout the quarantine and the feeding study trial, quail were maintained under controlled conditions of temperature (23.0 ± 2.0°C), relative humidity (50.0 ± 5.0%), and lighting (12/12 h, light/dark cycle). Quail were provided fresh feed once per week. The quantity provided was designed to exceed normal feed consumption yet reduce spillage. During this weekly feeding, litter pans were cleaned and wasted feed was measured. Throughout the feeding trial, quail were monitored daily for changes in health disposition (i.e., neurologic signs [ataxia]) or the onset of morbidity. Moribund birds were terminated from the study and tissues were collected for histopathology and other analyses. Birds were euthanized by electrocution. Blood collection and tissue isolation occurred at the termination of the 90-d feeding trial. Care and maintenance of the animals were in accordance with the Virginia Tech policies governing the use of animals in research and teaching [11].

Test article

The test standard for TNT was obtained commercially from Chem Service (catalog number 0-2288; West Chester, PA, USA). A certificate of analysis accompanied each shipment of

* To whom correspondence may be addressed (rgogal@vt.edu).

9834

product and guaranteed purity at 99.0 ± 0.5%. The test substance, TNT, used in the feeding trials was obtained from the U.S. Army Research Laboratory (U.S. ARL, Aberdeen Proving Ground, MD, USA). The U.S. ARL TNT was redistilled and crystallized from old product and was determined to be 99.0% pure (Military Unique and Special Chemistry Program, Directorate of Laboratory Science, U.S. Army Center for Health Promotion and Preventive Medicine, Aberdeen, MD).

Feed formulations

The treatment feeding mixtures for the 90-d study were formulated by serially mixing a stock feed mix (6,000 ppm) into the individual treatment feed concentrations. Briefly, the stock feed mixture was formulated by dissolving purified TNT (9.001 g) into 250 ml of acetone and then evenly dispersing this solution onto the stock feed in large trays and allowing it to air dry. Drying time was approximately 2 to 3 h. Each feed treatment was then prepared by mixing the appropriate concentration of the stock feed using a small cement mixer for 8 min. The TNT-feed mixtures were stored between 10 and 20°C. Concentrations of TNT in feed during exposure were confirmed by high-performance liquid chromatography-acetonitrile extraction. The treatment feeding mixtures were prepared at 3,000 mg/kg TNT-feed (diet 1), 1,500 mg/kg TNT-feed (diet 2), 750 mg/kg TNT-feed (diet 3), 100 mg/kg TNT-feed (diet 4), and 0.0 mg/kg TNT-feed (diet 5) following an acute lethal dose determination of 2,003 mg/kg and a 14-d range finding study [12]. The feed was provided fresh on a weekly basis. Weekly feed consumption was determined by taking the difference between the initial weight and the final feed weight plus the quantity spilled in the waste tray. Waste spillage was always less than 0.15 g/d. The TNT stability in feed was evaluated for both 90-d stability with refrigerated samples and weekly stability in the test facility environment. This study was conducted compliant with good laboratory practices.

Blood collection and Analysis

Blood collection. Blood was collected from the jugular vein with a 25-gauge needle and 3-ml syringe. After collection, an 18-gauge needle was attached to the syringe and the blood was transferred into a depressurized heparinized tube. The blood was mixed thoroughly and approximately 200 μl of heparinized blood was removed and transferred into an appropriately marked tube for the whole-blood analysis.

Whole blood cellularity. A 10-μl aliquot of blood was transferred into a tube containing 990 μl of phosphate buffered saline (PBS) and mixed by gentle vortexing. A 10-μl aliquot was removed from each sample and added to a tube containing 990 μl of Natt-Herrick stain. The tube was gently vortexed, and a 10-μl aliquot of the stained blood sample was placed onto a hemacytometer and the cells were enumerated. The number of red blood cells (RBCs) was determined per milliliter and per microliter. In addition, heterophils, lymphocytes, thrombocytes, and monocytes were enumerated and a heterophil/lymphocyte ratio was determined.

Packed cell volume and total protein. A hematocrit capillary tube was inserted into the tube containing the heparinized blood. Once blood filled approximately three fourths of the tube, pressure was applied to the top and the tube was removed. The bottom of the tube was cleaned and inserted into the clay pad and then centrifuged for 5 min. The packed cell volume (PCV) was determined using a graphic reader card. Following enumeration of the PCV, the tube was cut above the RBC layer and two to three drops (30–50 μl) of plasma were placed onto a refractometer and the total protein was determined.

Mean corpuscular volume. The mean corpuscular volume (MCV) was determined via the calculation MCV = (PCV × 10)/RBC (× 10^6/μl).

Whole-blood five-point leukocyte differential

A drop (10–15 μl) of heparinized whole blood was placed on a microscope slide and a smear was made using standard techniques. The blood smear was allowed to air dry. The slide was then stained with a modified Wright stain. The stained slides were allowed to dry overnight, then were coverslipped the next day. A five-point differential was performed where 200 leukocytes were enumerated. The cells enumerated were heterophils, lymphocytes, monocytes, basophils, and eosinophils. Heterophil/lymphocyte ratios were also calculated.

Spleen weight/body weight ratio and cellular recoveries

The spleens were removed by aseptic dissection following euthanasia and cleaned of excess adipose and other connective tissues. Spleens were then individually weighed, and the ratio of splenic weight to quail total body weight was calculated.

Lymphocyte transformation assay

Proliferation to T-cell and Pan-lymphocyte (includes B-cell) mitogens was evaluated for peripheral blood and splenic lymphocytes. These assays have been adapted for birds and followed Gogal et al. [13]. Briefly, isolated or enriched cell suspensions were enumerated and diluted to 3.0 × 10^6 cells/ml. A 100-μl aliquot of the cells was added to triplicate wells of a Corning 96-well round-bottom tissue culture plate (Corning, NY, USA) containing 100 μl of either supplemented RPMI-1640 media alone, Concanavalin A (Con A, 10 μg/ml), Con A (50 μg/ml), or Phorbol 12-myristate 13-acetate (10 ng/ml) + Ionomycin (200 ng/ml), then placed into a humidified incubator at 37°C at 5% CO_2. Approximately 24 h postincubation, 20 μl of alamar blue (Accumed, West Lake, OH, USA) was added to each well and the plates were returned to the incubator. Alamar blue is a viability-proliferation dye, which measures proliferation changes through metabolic reduction of the dye [13,14]. The plates were removed at 48 and 72-h postsetup and the specific absorbances were determined using a Molecular Devices kinetic microplate reader (Menlo Park, CA, USA) at 570 to 600 nm. The proliferative changes were determined and reported as follows:

Δspecific absorbance

= mean specific absorbance (mitogen-induced cells)

− mean specific absorbance (media alone + cells)

Cytological examination of isolated leukocyte fractions (blood and spleen)

During the addition of the isolated-enriched lymphocyte suspensions to the proliferation plates, 300-μl aliquots (0.9 × 10^6) of the cell suspensions (i.e., blood, spleen) were also added to chambers on the cytospin apparatus containing 0.5% bovine serum albumin-phosphate buffered saline. Each cytospin apparatus was then placed into the Cyto-Tek centrifuge (Sakura Finetechnical, Tokyo, Japan) and spun at 500 rpm for 5 min. The slide was removed from each cytospin apparatus and allowed to air dry. The slides were stained with a modified

Wright stain, dried, and coverslipped. They were then submitted for pathological analysis in a blinded manner. The animal number, tissue type, and cytologic preparation date were the only information provided to the pathologist. For each slide, 200 leukocytes were enumerated and scoring of cytospin preps as small lymphocytes, prolymphocytes, lymphoblasts, plasma cells, heterophils, monocytoid, and other was done.

Analysis of apoptosis in splenic- and blood-isolated leukocytes

Isolated lymphocyte cell suspensions were evaluated for changes in level of apoptosis. The apoptotic probes 7-aminoactinimycin D (7-AAD) (Accumed International, Westlake, OH, USA) and Annexin V (Pharmingen, San Diego, CA, USA) were employed and analyzed. Briefly, splenic and peripheral blood lymphocytes (3.0×10^5/well) were coincubated with both the 7-AAD and Annexin V-FITC on ice in the dark for 15 min. Both probes have documented stabilities of at least 30 min according to the manufacturers. The cells were analyzed under a two-color procedure on an Epics XL flow cytometer (Coulter, Miami, FL, USA) [15–17]. Unstained control leukocytes were employed as negative controls to set gates. In the first experiment, single-color fluorescence was assessed for each tissue suspension to standardize peak response. Cytosettings were kept the same for all experiments throughout this study. Scoring was as follows:

a. 7-AAD−/Annexin V− = Live cells

b. 7-AAD−/Annexin V+ = Apoptosis (early)

c. 7-AAD+/Annexin V+ = Apoptosis (mid)

d. 7-AAD+/Annexin V− = Apoptosis (late + necrotic cells)

Histopathology of spleen, liver, and kidney

For light microscopic tissue evaluation, the liver and kidney were collected immediately following euthanasia of each quail, fixed in neutral phosphate-buffered formalin, and processed by routine histological techniques. Five-micron sections of each organ were cut and stained with hematoxylin and eosin. The slides were dried and then routinely processed and stained (Wright's stain) for cytologic evaluation.

Slides for histopathologic evaluation were read in a blinded manner as before, using qualitative, graded response criteria evaluated by comparisons with controls.

Statistical analysis

Discrete responses were analyzed across diets (TNT concentrations in feed). The FREQ procedure of the SAS® System (Ver 7.01, SAS Institute, Cary, NC, USA) was used to perform Fisher's exact test for each discrete response variable. When the overall test of association was significant, each diet was compared with the control using Fisher's exact test with the Bonferroni correction (the alpha level for each comparison with the control was 0.0127, to bring the alpha level overall back to 0.05). The MIXED procedure of the SAS System was used to perform a mixed model analysis of covariance (ANCOVA) for each continuous response variable. The ANCOVA began by testing whether slopes across dose were equal for the sexes. If the slopes were different, a separate line was fit for each sex. When the slopes across dose for each sex were not different, a common slope model was tested and, if significant, a line was fit. All case effects with p-values greater than 0.05 were considered nonsignificant.

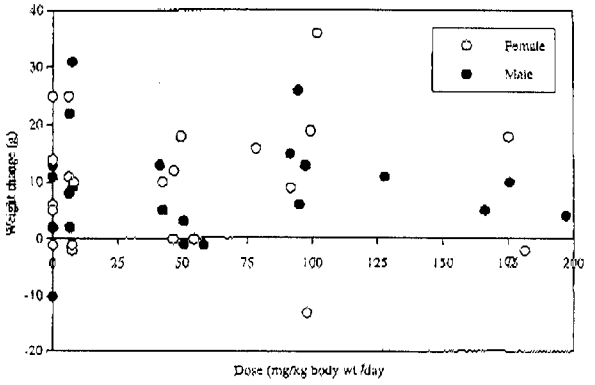

Fig. 1. Weight changes based on dose (mg/kg/d). Each dot represents an individual bird. Weight changes ranged from −13.0 g to 36.0 g.

RESULTS

Feed consumption and weight changes

Quail consumed feed consistently throughout exposure and there were no differences between treatments ($p > 0.87$). Quail consumed 13.94 ± 2.77 g and 14.98 ± 3.42 g feed/d for males and females, respectively. No weight changes were found attributable to treatment (males, 8.78 ± 9.07 g; females, 10.72 ± 11.42 g; $p > 0.97$). Weight changes ranged from −13.0 g to 36.0 g with a mean of 8.98 ± 1.50 g (Fig. 1). Based on feed consumed, the calculated doses to males and females consuming the experimental diets were approximately 178, 97.5, 48.0, and 7.0 mg TNT/kg/d. Feed consumption was about equal between sexes.

Clinical observations

Four birds in the high-dose group became moribund and were euthanized or died within 30 d of the initiation of the feeding study. These birds exhibited symptoms of ataxia, muscular weakness, and convulsions prior to death. No other birds in any of the other treatments exhibited these symptoms.

Hematology

With the Natt-Herrick blood background stain, the RBC of the TNT-exposed birds appeared to have a darker cell wall and nucleus. The nucleus was characterized as being more rounded, smaller, and darker. Also noted in the plasma was an intense yellowish color (lipemia) compared with plasma from control animals. Evaluation of the total RBC, packed cell volume, mean corpuscular volume, and total protein showed neither effect of sex nor sex-by-dose interaction effect. However, an overall linear decrease in RBC number (Fig. 2), packed cell volume (Fig. 3), and total protein (Fig. 4) with increasing dose was observed.

Cellularity and tissue/body weight ratio

Peripheral blood and splenic cellularity were evaluated. There was no effect of dose or sex nor any sex-by-dose interaction effect on the total lymphocyte cellularity or total cellularity of either the peripheral blood or spleen. There was no effect of dose or sex nor any sex-by-dose interaction effect on spleen weight/body weight ratio (data not shown).

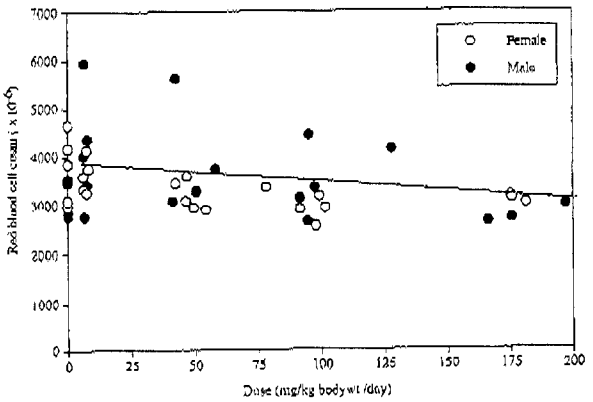

Fig. 2. Total red blood cell count based on TNT dose (mg/kg body wt/d) ($p < 0.05$, analysis of covariance).

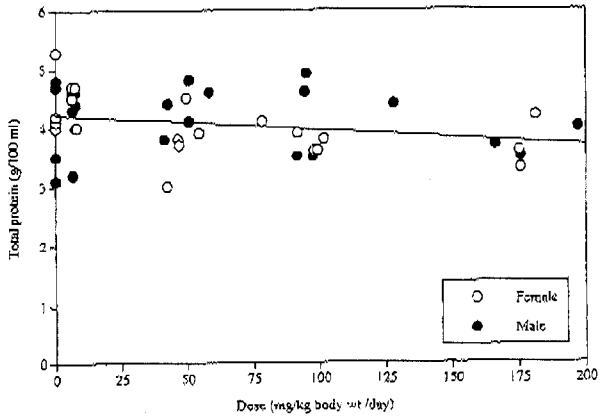

Fig. 4. Measurement of total protein across TNT dose (mg/kg/body wt/d) ($p < 0.05$, analysis of covariance).

Cellular proliferation

Both peripheral blood lymphocytes and splenic lymphocytes were assessed for proliferation to T cell and pan lymphocyte mitogens. There was no significant effect of dose or sex nor any sex-by-dose interaction effect on lymphocyte proliferation (data not shown).

Cellular apoptosis

Enriched splenic and peripheral blood leukocytic populations were evaluated for incidence of cellular apoptosis. There was no effect of dose or sex nor any sex-by-dose interaction effect on percent viable cells, early apoptotic cells, late apoptotic/necrotic cells, or total apoptotic cells of the peripheral blood leukocytes. Further, there was also no effect of dose or sex nor any sex-by-dose interaction effect on the above-measured apoptotic endpoints in the splenic leukocytes. However, the percentage of indeterminate apoptotic/necrotic blood leukocytes increased linearly with dose (Fig. 5; ANCOVA, $p < 0.05$).

Histopathology

There was a significant association between diet and Kuppfer cell hemosiderosis ratings ($p < 0.001$; Fig. 6). However, none of the pairwise comparisons of each dose against the control were significant. There were no significant associations between diet erythrophagocytosis ratings or hepatocyte vacuolation ratings.

DISCUSSION

To our knowledge, the effects of TNT exposure in birds have not been evaluated. Many species of birds are potentially exposed to TNT in contaminated soils, largely due to their foraging habits. Northern bobwhite were chosen as the study model since they are native to North America, are a game species of management concern, have a life history that suggests that soil exposures may be significant [18], and are amenable to laboratory toxicological investigations [19,20]. Mammals exposed to TNT show a variety of hematologic effects [4,6–10]. Splenic pathology has also been documented in laboratory rodents treated with TNT, including hematologic effects, suggesting that the immune system may be a target. A battery of tests that includes hematologic and immunologic endpoints was therefore employed in TNT-exposed quail to determine if oral exposures resulted in similar toxicologic effects as seen in mammals.

Exposure to TNT caused a variety of effects in the northern bobwhite. Effects observed through the subchronic 90-d feeding trial included a decrease in total red blood cell counts, a decrease in packed cell volume, a decline in total plasma protein, a decline in prolymphocyte counts from enriched leu-

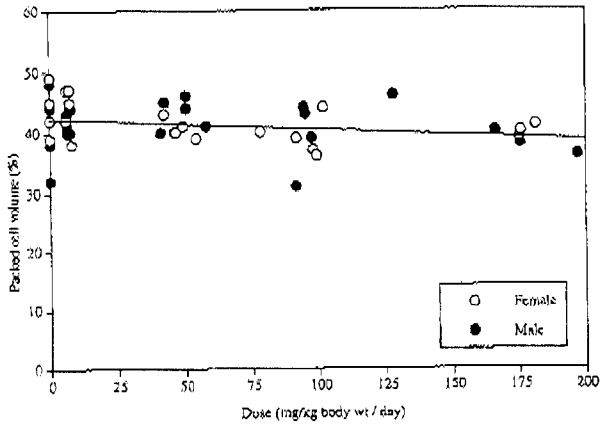

Fig. 3. Measurement of packed cell volume across TNT dose (mg/kg body wt/d) ($p < 0.05$, analysis of covariance).

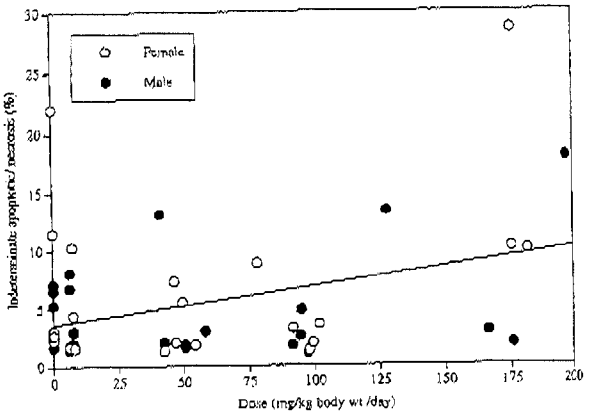

Fig. 5. Comparison of the percentage of late apoptotic/necrotic blood leukocytes between diet ($p < 0.05$, analysis of covariance).

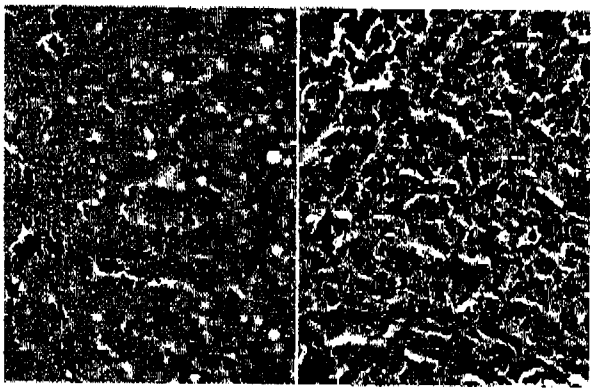

Fig. 6. Histopathology of the control (A) and 175 mg/kg body weight/d TNT-treated (B) quail liver. The brown-stained cells denoted by the arrows are Kuppfer cells containing hemosiderin (magnification ×200).

kocyte fractions of the peripheral blood, a decline in lymphocyte counts from enriched leukocyte fractions of peripheral blood, and an increase in indeterminate apoptotic/necrotic leukocytic cells from enriched leukocyte fractions of the peripheral blood. Although the trends were statistically significant, none of these effects were remarkable compared with data collected for mammals [7–9]. A nonsignificant trend toward increased hemosiderosis in the Kuppfer cells of the liver was also observed. Hemosiderosis in the liver has been described in mammals exposed to lower levels of TNT than the present birds [6–9]. No significant differences in any of the above parameters were found across treatment groups compared with controls. We acknowledge that individual variation in feed consumption within treatments contributed to relatively high variability in treatment-group data, yet given the range of TNT concentrations in feed, we expected to observe more pronounced effects. In addition, although the values for the hematological parameters decreased with increasing dose, these values still fall within the normal ranges for these species [21]. Therefore, although trends were evident, the biological relevance of the hematologic effects in birds is questionable.

The limited hematologic toxicity of TNT in birds compared with mammals may be due to the physiological differences between avian and mammalian hematopoietic systems. Birds are relatively unique in their metabolic capacity in terms of oxygen transport requirements needed for sustained flight. Consequently, their red blood cell regeneration capacity is greater than that of mammals of comparable mass [22,23]. Moreover, birds possess nucleated red blood cells [22,23] that are more refractory to compounds shown to damage the nonnucleated red blood cells common to mammals. For example, avian erythrocytes are resistant to osmotic lysing solutions used in vitro to remove RBCs from whole blood. Further, birds have a high blood-volume regenerative capacity relative to mammals, including enhanced erythropoietic capacity. This may explain why the present changes seen in the hematology were not as profound as those reported in mammalian studies. Further, birds' serum osmotic pressure is approximately half that of mammals [24], which may also add to the refractory nature of avian blood.

The decline in prolymphocyte counts and lymphocyte counts and the increased apoptotic/necrotic leukocytic cells in TNT-exposed birds suggest the possibility of adverse immunologic effects in these animals. It is noteworthy that such targeting of white blood cells has not previously been reported in mammals dosed with TNT; however, such evaluations were limited in scope. The ability of lymphocytes to proliferate following mitogen stimulation was evaluated in the present study and found not to be affected by TNT. Other functions of these cells (e.g., antigen presentation, lysis of cells expressing foreign antigen, antibody production) were not studied; thus, it is not known if TNT affected these functions.

Acute toxicity leading to mortality was observed only in birds fed the highest dose of TNT and was accompanied by signs consistent with CNS-related effects (e.g., ataxia). Whether TNT exposure caused toxicity not observed on the CNS is not known and should be considered in future studies. It was noted that mortality in birds occurred at dietary levels also associated with mortality in rodent studies; however, mice consume as much as 25% of their body weight/d while the quail consumed only about 6% of their body weight/d. Data are not available regarding systemic TNT exposure in birds as compared with rodents under the above conditions, but these feeding data suggest that quail may show CNS effects at a lower systemic TNT level than do rodents.

Based on the results of this 90-d study, a low observed-adverse-effect level in the serious category (i.e., due to the incidence of mortality) was determined to be 178 mg/kg/d. Acknowledging the limitations of this study, we estimated a no-observable-adverse-effect level (NOAEL) of 7 mg/kg/d. We wish to point out that this NOAEL may be an underestimation of the true NOAEL and that other target tissues (e.g., CNS) will need to be investigated to increase confidence in the present estimated NOAEL in TNT-exposed birds.

Acknowledgement—This work was supported by the Environmental Quality and Technology Program through the U.S. Army Corps of Engineers. We thank Warren Hilstrom (U.S. Army Research Laboratory) for providing the TNT, Joan Kalnitsky for the flow cytometric analyses, Linda Correll and Sandy Perkins for their quality-control monitoring, Jill Songer for histopathology, and Richard Orr for his supply of the parent bird stock.

REFERENCES

1. Burrows EP, Rosenblatt DH, Mitchell WR, Parmer DL. 1989. Organic explosives and related compounds: Environmental and health considerations. TR-8901. Technical Report. U.S. Army Biomedical Research and Development Laboratory, Frederick, MD.
2. Walsh ME, Jenkins TF. 1992. Identification of TNT transformation products in soil. 92-16. Special Report. U.S. Army Corps of Engineers, Cold Regions Research and Engineering Laboratory, Hanover, NH.
3. Talmage SS, Opresko DM, Maxwell CJ, Christopher JE, Welsh PMC, Reno PH, Daniel FB. 1999. Nitroaromatic munition compounds: Environmental effects and screening values. *Rev Environ Contam Toxicol* 161:1–156.
4. Johnson MS, Ferguson JW, Holladay SD. 2000. Immune effects of oral 2,4,6-trinitrotoluene (TNT) exposure to the white-footed mouse, *Peromyscus leucopus*. *Int J Toxicol* 19:5–11.
5. Johnson MS, Vodela JK, Reddy G, Holladay SD. 2000. Fate and the biochemical effects of 2,4,6-trinitrotoluene exposure to tiger salamanders (*Ambystoma tigrinum*). *Ecotoxicol Environ Saf* 46: 186–191.
6. Reddy GS, Chandra AM, Qualls CW Jr. 2000. Toxicity of 2,4,6-trinitrotoluene (TNT) in hispid cotton rats (*Sigmodon hispidus*): Hematological, biochemical, and pathological effects. *Int J Toxicol* 19:1–9.
7. Dilley JV, Tyson CA, Spanggord RJ, Sasmore DP, Newell GW, Dacre JC. 1982. Short-term oral toxicity of 2,4,6-trinitrotoluene in mice, rats, and dogs. *J Toxicol Environ Health* 9:565–585.
8. Levine BS, Furedi EM, Gordon DE, Barkley JJ. 1984. Subchronic toxicity of trinitrotoluene in Fischer 344 Rats. *Toxicology* 32: 253–265.

9. Levine BS, Furedi EM, Gordon DE, Lish PM. 1990. Six month oral toxicity study of trinitrotoluene in beagle dogs. *Toxicology* 63:233–244.
10. McCain WC. 1998. Fourteen-day range finding and ninety-day feeding study of 2,4,6-trinitrotoluene in the white-footed mouse (*Peromyscus leucopus*). Toxicological Study 2340-38-95-6-1. U.S. Army Center for Health Promotion and Preventive Medicine, Aberdeen Proving Ground, MD.
11. National Academy Press. 1996. Virginia Tech policies governing the use of animals in research and teaching. In *ILAR/NRC Guide for Care and Use of Laboratory Animals*. Washington, DC, pp 1–125.
12. Gogal RM. 2000. Influence of feed exposure with TNT derivatives on quail (northern bobwhite, *Colinus virginianus*) immunity as measured by National Toxicology Program immune endpoints. Final Report/Avian Toxicology Study 99503G, 981124G. Avian Immunotoxicology Risk Assessment Laboratory, Virginia Polytechnic Institute and State University, Blacksburg, VA, USA.
13. Gogal RM Jr, Ahmed SA, Larsen CT. 1997. Analysis of avian lymphocyte proliferation by a new, simple, nonradioactive assay (lympho-pro). *Avian Dis* 41:714–725.
14. Ahmed SA, Gogal RM, Walsh JE. 1994. A new rapid and simple non-radioactive assay to monitor and determine the proliferation of lymphocytes: An alternative to 3H-thymidine incorporation assay. *J Immunol Methods* 170:211–214.
15. Scmid I, Uittenbogaart CH, Keld B, Giorgi JV. 1994. A rapid method for measuring apoptosis and dual-color immunofluorescence by single laser flow cytometry. *Cytometry* 15:12–20.
16. Donner KJ, Becker KM, Hissong BD, Ahmed SA. 1999. Comparison of multiple assays for kinetic detection of apoptosis in thymocytes exposed to dexamethasone or diethylstilbesterol. *Cytometry* 35:80–90.
17. Gogal RM Jr, Smith BJ, Kalnitsky J, Holladay SD. 2000. Analysis of apoptosis of lymphoid cells in fish exposed to immunotoxic compounds. *Cytometry* 39:310–318.
18. U.S. Environmental Protection Agency. 1993. *Wildlife Exposure Factors Handbook*. EPA/600/R-93/187a. Office of Research and Development, Washington, DC.
19. Shirazi MA, Bennett RS, Ringer RK. 1994. An interpretation of toxicity response of bobwhite quail with respect to duration of exposure. *Arch Environ Contam Toxicol* 26:417–424.
20. Peebles ED, Cheaney JD, Vaughn KM, Latour MA, Smith TW, Haynes RL, Boyle CR. 1996. Changes in gonadal weights, serum lipids, and glucose during maturation in the juvenile northern bobwhite quail (*Colinus virginianus*). *Poult Sci* 75:1411–1416.
21. Ernst RA, Coleman TH, Kulenkamp AW, Ringer RK, Pangborn S. 1971. The packed cell volume and differential leucocyte count of bobwhite quail (*Colinus virginianus*). *Poult Sci* 50:389–391.
22. Ritchie BW, Haison GJ, Harrison LR. 1994. *Avian Medicine: Principles and Application*. Winger, Lake Worth, FL, USA.
23. Feldman BF, Zinkl JG, Jain NC. 2000. *Schalm's Veterinary Hematology*. Lippincott, Williams & Wilkins, Hagerstown, MD, USA.
24. Spector WS. 1961. *Handbook of Biological Data*. WB Saunders, Philadelphia, PA, USA.