59234

ENVIRONMENTAL RESEARCH 40, 531–539 (1986)

# Thallium-Induced Testicular Toxicity in the Rat

L. FORMIGLI,* R. SCELSI,† P. POGGI,† C. GREGOTTI,‡ A. DI NUCCI,‡
E. SABBIONI,§ L. GOTTARDI,* AND L. MANZO*,[1]

*Pharmacology and Toxicology Division, Department of Internal Medicine, †Institute of Pathology, and ‡Institute of Pharmacology II, University of Pavia Medical School, Pavia, Italy; and §Radiochemistry and Nuclear Chemistry Division, Commission of the European Communities Joint Research Center, Ispra, Italy

Received May 1985

Reproductive tract functions were studied in adult male Wistar rats given 10 ppm thallium as thallium sulfate in the drinking water. After 60 days of treatment, spermatozoa isolated from the cauda epididymides and vas deferens showed reduced motility and immature germ cells were found in the tubular lumen. Histological examination of testes in thallium-treated animals revealed disarrangement of the tubular epithelium and ultrastructural changes in the Sertoli cells with cytoplasmic vacuolation and distension of the smooth endoplasmic reticulum. The activity of testicular β-glucuronidase was significantly reduced whereas acid phosphatase and sorbitol dehydrogenase activities were unchanged. Plasma testosterone levels were within normal limits. No abnormalities in testicular morphology and biochemistry were seen in animals sacrificed at the end of the first month of thallium exposure. These findings indicate that the male reproductive system is a susceptible target site to toxic effects of thallium under chronic exposure. They also suggest a major involvement of Sertoli cells in the mechanism underlying thallium-induced testicular damage. © 1986 Academic Press, Inc.

## INTRODUCTION

The adverse effects of chemicals on male reproduction is an area of growing concern (Gunn and Gould, 1970), and the assessment of fertility disorders caused by drugs and environmental agents has become increasingly important in experimental andrology and toxicology (Dixon and Hall, 1982).

Thallium is an extremely toxic metal. Several intoxications and fatalities have been reported following ingestion of thallium-containing rodenticides (Cavanagh *et al.*, 1974) and concern has recently been expressed for the health consequences of long-term absorption of thallium released into the environment from various anthropogenic sources including coal mines and coal-burning power plants (Smith and Carson, 1977; Zitko, 1975). Although studies of thallium toxicity have focused primarily on effects on the nervous system (Cavanagh *et al.*, 1974; Manzo *et al.*, 1983), skin (Cavanagh and Gregson, 1978), and cardiovascular tract (Lameijer and Van Zwieten, 1976), thallium poisoning has also been reported to produce testicular atrophy in laboratory animals (Truhaut, 1958). Thallium has been shown to accumulate preferentially in the human testis (Davis *et al.*, 1981), rat testis (Sabbioni *et al.*, 1980), and rat epididymis (Lameijer and Van Zwieten, 1977). Moreover high concentrations of thallium have been found to have muta-

[1] To whom correspondence should be addressed.



0013-9351/86 $3.00
Copyright © 1986 by Academic Press, Inc.
All rights of reproduction in any form reser

7208

genic and antimitotic properties and to affect basic cellular activities such as differentiation, protein synthesis, and energy metabolism (Sabbioni and Manzo, 1980). Since the thallium ion accumulates in mammalian tissues after contin exposure (Manzo *et al.*, 1983), it may constitute a health hazard even at the relatively low exposure levels occurring in a contaminated environment. This paper describes the effects of chronic thallium exposure on the male reproductive system of the rat.

## MATERIALS AND METHODS

Male Wistar rats (Charles River, Calco, Italy), weighing 350–380 g, were housed in stainless-steel cages under controlled temperature and light conditions and acclimatized for 2 weeks before use. Thallium was administered in the drinking water, 10 ppm as $Tl_2SO_4$, for 30 or 60 days. Controls were pair-fed to the thallium-treated animals and received tap water. Food and water were available *ad libitum*. Body weight and water consumption were measured daily throughout the study. At the end of the two administration periods, thallium-treated rats and their pair-fed controls (10 animals per group) were killed by exsanguination and blood samples were taken.

*Histology*. Testes were immediately removed and weighed and the tunica albuginea was discarded. Testicular parenchyma was cut in 1-mm blocks and fixed in 0.1 M cacodylate-buffered glutaraldehyde–paraformaldehyde (Karnovsky, 1965). Semithin sections were stained with toluidine blue for light-microscope examination. Material for electron microscopy was fixed in Karnovsky's solution, postfixed in osmium-collidine, dehydrated, and embedded in Epon. Thin sections were stained with uranyl acetate and lead citrate and examined using a Zeiss 109 electron microscope. The diameters of transverse sections of seminiferous tubules were measured by means of a Leitz ocular micrometer. At least 10 random measurements were made from each slide.

*Spermatozoa motility*. Spermatozoa isolated from cauda epididymides and vas deferens were suspended in Ham's F-10 medium (Chen and Jones, 1982) and sperm motility was determined by direct microscope observation of warmed slides. The percentage of motile spermatozoa was calculated for each sample by classifying 100 sperm per specimen as motile or nonmotile. An average based on four different determinations was used as a final figure.

*Biochemical investigations*. A portion of the testis was homogenized in 5 vol (w/v) of ice-cold 0.1 M acetate buffer, pH 4.5, using a glass homogenizer with a Teflon pestle and the homogenate was centrifuged at 1000*g* for 10 min at 4°C. The nuclear pellet was resuspended in acetate buffer and centrifuged again at 1000*g* for 30 min. The combined supernatant fluids were then centrifuged at 17,000*g* for 30 min. The sediment was resuspended in the same volume of acetate buffer as the original homogenate and assayed for acid phosphatase (Walter and Schütt, 1974) and β-glucuronidase (Fishman, 1974). The remaining portion of the testis was homogenized in 0.2 M triethanolamine buffer, pH 7.4, and centrifuged at 105,000*g*. Sorbitol dehydrogenase was measured in the soluble (postmicrosomal) fraction according to the method of Gerlach and Hibby (1974). Protein concentration was determined by the method of Lowry *et al.* (1951). The nonprotein thiol

groups were measured from trichloroacetic acid (6.5%)-deproteinized tissue-homogenate samples by the method of Saville (1958).

*Chemical investigations.* Plasma testosterone analysis was performed using a Coat-A-Count solid-phase $^{125}I$ radioimmunoassay kit (Lee Co. Diagnostics, Southfield, Mich.) based on a no-extraction method with a sensitivity down to 0.11 ng testosterone/ml. Testosterone concentrations in serum-based standards ranged from 0.3 to 30 ng/ml.

Thallium levels in the testis were measured by laser-enhanced ionization spectrometry (LEIS) as described by Travis *et al.* (1982).

*Statistical analysis.* Data were compared by analysis of variance.

## RESULTS

During the 60-day treatment period, the total intake of thallium was 16.2 mg Tl/rat, corresponding to an average daily intake of 270 μg Tl/rat. Thallium treatment did not significantly affect food and water consumption or body weight gain and no prominent hair loss or clinical signs of neuropathy were seen. As shown in Table 1, a significant decrease in sperm motility was observed in the rats after 60 days of thallium exposure. Nine out of ten animals in the thallium group had less than 60% motile sperm in their semen, as compared to only one rat in the control group. In addition most treated animals exhibited high numbers of immature cells in their epididymal spermatozoa.

Both the absolute and relative weights of testes and testicular nonprotein content were similar in control and thallium-treated animals. Average plasma testosterone levels, in control and thallium-treated animals, were 3.06 ± 0.7 and 2.9 ± 0.7 ng/ml, respectively. LEIS analysis of testicular thallium revealed average tissue levels of 6.3 ± 0.4 μg Tl/g in the 60-day treated rats and less than 0.08 ng/g in pair-fed controls.

Histological examination of the testis revealed no significant differences in tubular diameter between control and thallium-treated rats. However, changes in seminiferous epithelium were invariably present in the 60-day thallium group (Fig. 1). These included increased release of later spermatids into the tubular lumen, with numerous vacuole-like spaces between the germ cells (Fig. 2). The morphology of spermatogonia, spermatocytes, and spermatids showed no remarkable changes. At electron microscopy, diffuse cytoplasmic vacuolation and

TABLE 1
EFFECT OF THALLIUM ADMINISTRATION ON MALE REPRODUCTIVE SYSTEM PARAMETERS IN THE RAT

| | Control | Thallium[a] |
|---|---|---|
| Relative testicular weight[b] | 0.36 ± 0.02 | 0.37 ± 0.03 |
| Seminiferous tubular diameter (μm) | 290 ± 9.5 | 276 ± 10.7 |
| Sperm motility (%) | 66.5 ± 4.47 | 40.5 ± 8.11[c] |
| Plasma testosterone (ng/ml) | 3.06 ± 0.7 | 2.90 ± 0.7 |
| Testicular nonprotein thiol content (μmole/g) | 1.60 ± 0.14 | 1.69 ± 0.02 |
| Testicular thallium concentrations (μg/g) | <0.08 | 6.3 ± 0.4[c] |

[a] 10 ppm thallium, as thallium sulfate in the drinking water for 60 days.
[b] Testis/body weight ratio × 100.
[c] Significantly different from control, $P < 0.01$. Values are the mean ± SE of 10 rats.

FIG. 1. Histological picture of a seminiferous tubule. (a) control rat; (b) rat given 10 ppm thallium in the drinking water for 60 days. Note the disarrangement of the seminiferous epithelium with premature sloughing of the germ cells in the tubular lumen. Toluidine blue ×200.

distension of the smooth endoplasmic reticulum of the basal and perinuclear cytoplasm were frequently observed in the Sertoli cells (Fig. 3).

Since changes in testicular biochemistry may precede other signs of toxic damage (Chapin *et al.*, 1982), investigations were extended to selected testicular enzyme activities considered as indicators of testicular function in the rat (Hodgen and Sherins, 1973; Males and Turkington, 1971; Mills and Means, 1972). As shown in Fig. 4, the activity of testicular β-glucuronidase was significantly reduced after 60 days of thallium treatment. At this stage, no significant changes in the activity of acid phosphatase and sorbitol dehydrogenase were observed. In the animals killed after 30 days of thallium exposure, the results of all biochemical investigations were virtually the same as those in controls and no abnormalities in testicular morphology were seen.

## DISCUSSION

In this study, accumulation of thallium in the testis associated with morphological, biochemical, and functional abnormalities in the reproductive tract was observed in rats given 10 ppm thallium in the drinking water for 2 months. Since plasma testosterone levels were similar in thallium-treated animals and in their controls, the effect of thallium was probably unrelated to alterations in androgenic homeostasis. In previous experiments (Manzo *et al.*, 1983), continuous exposure to 10 ppm thallium induced typical signs of thallotoxicosis such as hair loss and peripheral nervous system disorders, but these effects occurred later

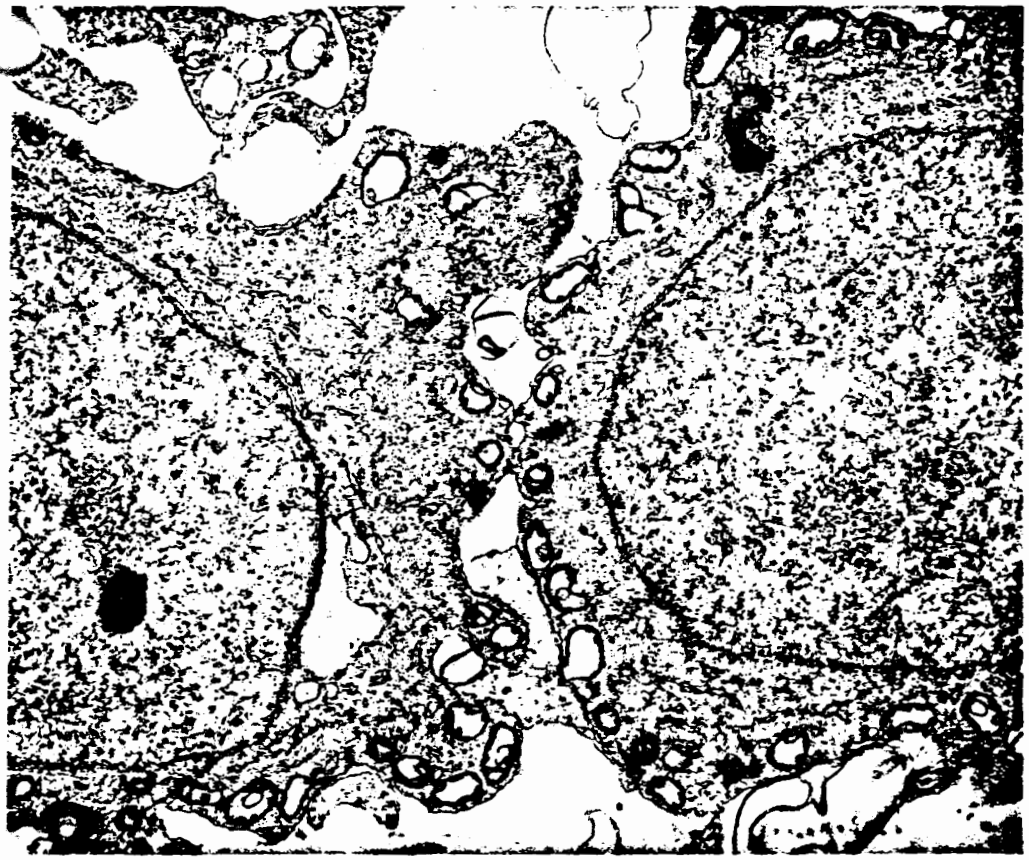

FIG. 2. Vacuole-like space formation between seminiferous cells with loss of contact of adjacent spermatids in a thallium-treated rat. × 15,700

(i.e., after 4–8 months), as compared to the testicular changes. This suggests that the male reproductive system is particularly sensitive to the early effects of thallium in chronically exposed rats.

The motility of epididymal spermatozoa was reduced in the thallium-treated animals. This abnormality may reflect a direct action of thallium on the testis and/or post-testicular changes related to the accumulation of spermiotoxic thallium levels in the excretory pathways of the reproductive system. Inhibition of sperm motility was observed in *in vitro* experiments using boar ejaculates incubated with thallium at concentrations as low as 0.001 mM (L. Gottardi *et al.*, in preparation). These concentrations are considerably lower than those measured in the epididymis (Lameijer and Van Zwieten, 1977) and testis (this study) of rats after long-term exposure to 10 ppm thallium.

On the other hand, as shown in the present study, thallium can induce selective alterations in biochemical markers of testicular function. Thus, inhibition of testicular β-glucuronidase, an enzyme primarily located in Sertoli cells and spermatogonia (Males and Turkington, 1971), was demonstrated in the 60-day treated rats. In contrast, both the ubiquitous acid phosphatase (Reddy and Svoboda, 1967) and sorbitol dehydrogenase, which is normally associated with postmeiotic

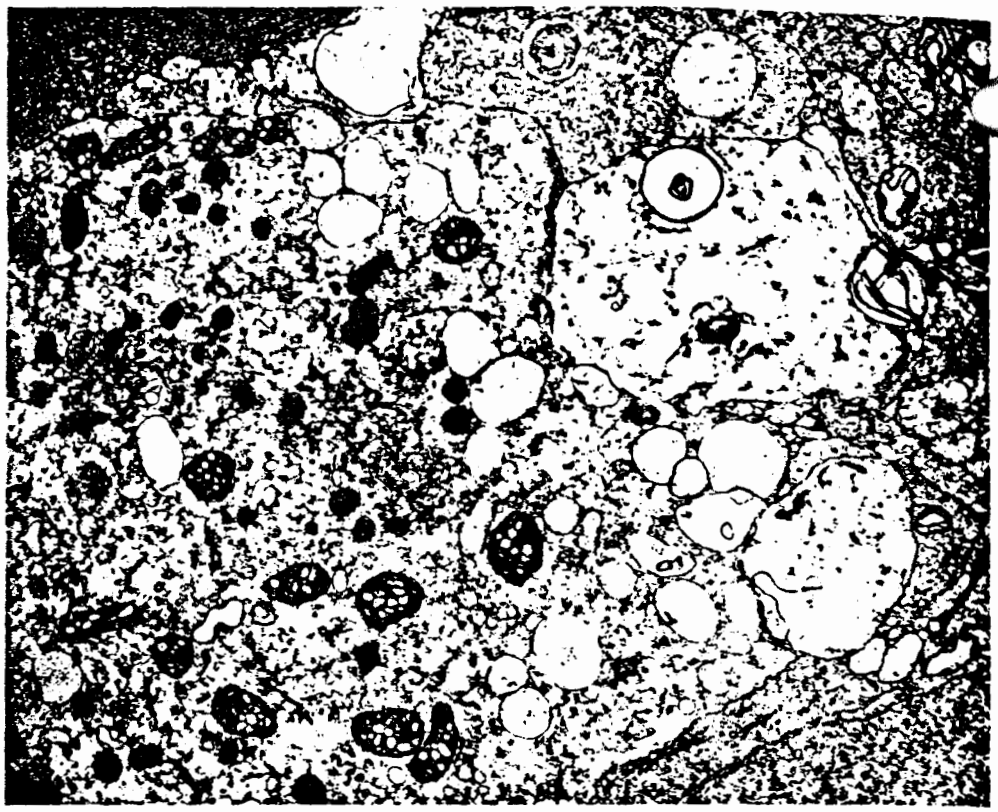

FIG. 3. Electron micrograph of a Sertoli cell after 60 days of thallium exposure. × 15,700.

spermatogenic cells (Mills and Means, 1972), did not differ from controls. Sertoli cells are the main regulators of normal spermatogenesis and exert a critical role in controlling germ cell movements from the basal lamina to the tubular lumen and the release of later spermatids (Dym, 1977; Lacy, 1960). In thallium-treated rats

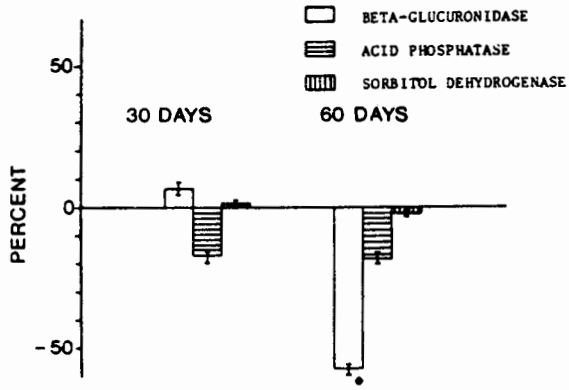


FIG. 4. Testicular enzyme activities after 30 and 60 days of thallium treatment. Ordinate is percentage change of average values from pair-fed controls. The mean enzyme activities (nmole product formed/min/mg protein) in control rats were 0.048, 0.15, and 4.3 (30-day group) and 0.046, 0.18, and 4.4 (60-day group) for β-glucuronidase, acid phosphatase, and sorbitol dehydrogenase, respectively. *Significantly different from control, $P < 0.01$ ($n = 10$).

degenerative changes in Sertoli cells were associated with disarrangement of the seminiferous epithelium and premature release of developing germ cells. Thus both the biochemical and morphological findings are consistent with a major involvement of Sertoli cells in the process underlying the thallium-induced testicular damage.

No enzymatic changes or gross anatomical abnormalities were seen in the testis of rats sacrificed after 30 days of thallium exposure. At this stage, testicular thallium levels were not measured. Studies of the time course of thallium accumulation in the testis, combined with detailed analysis of the various stages of the seminiferous epithelium (Leblond and Clermond, 1952; Creasy and Foster, 1984), may be useful in clarifying whether a relationship exists between thallium accumulation, duration of exposure, and development of testicular lesions.

The mechanism by which thallium affects the male reproductive system is not clear. Hasan and Ali (1981) described increased lipid peroxidation in the brain of rats exposed repeatedly to high doses of thallium ions and postulated a neurotoxicity mechanism based on depletion of glutathione and impairment of antioxidant-protection processes in cells. In the rat, both testis and semen contain very high levels of glutathione-dependent enzymes (Mukhtar *et al.*, 1978). Inhibition of glutathione peroxidase associated with increased lipid peroxidation in the testis (Omaye and Tappel, 1975) and depletion of nonprotein sulfhydryls in testis and epididymis (Chapin *et al.*, 1984) have been observed in rats after exposure to agents such as cadmium and methyl chloride which also causing histopathological changes in the male reproductive organs. Our experiments showed unaltered glutathione levels in the testes of the 60-day thallium-treated rats. This finding clearly does not exclude possible effects of thallium on metabolic activities dependent on intracellular glutathione homeostasis. In recent experiments, we found no direct combination of thallium with the glutathione molecule *in vitro;* however, 1 mM thallium has been effective in depleting cellular glutathione levels in *in vitro* preparations obtained from isolated rat hepatocytes (Richelmi *et al.*, 1984).

Thallium toxicity has also been interpreted in terms of altered energy metabolism resulting from thallium-induced disorders in flavoprotein-dependent activities (Cavanagh, 1984). The testis is especially dependent on glucose as a substrate for energy metabolism (Setchell and Hinks, 1967) and factors impairing glucose utilization are known to adversely affect testicular functions (Gravis *et al.*, 1977; Sullivan *et al.*, 1979). Epididymal sperm function can also be altered by toxic agents causing inhibition of sperm energy metabolism (Kluwe *et al.*, 1983). An interesting feature of the "energy-deprivation" hypothesis of thallium toxicity is that it implies common pathogenetic mechanisms in the development of damage to the peripheral nerve (Cavanagh, 1984), hair follicle (Cavanagh and Gregson, 1978), and reproductive tract.

## ACKNOWLEDGMENTS

LEIS analysis of testicular thallium was performed by Dr. N. Omenetto, Dr. P. Cavalli, and Dr. G. Rossi. Thanks are also due to Dr. C. Roccio for his help in plasma testosterone analysis. Supported by grants from the Commission of the European Communities (Contract ENV 811.1 TT), Italian National Research Council (CNR), and Ministry of Public Education.

## REFERENCES


Cavanagh, J. B. (1984). The problems of neurons with long axons. *Lancet* **1**, 1284–1287.

Cavanagh, J. B., Fuller, N. H., Johnson, H. R. M., and Rudger, P. (1974). The effects of thallium with particular reference to the nervous system changes. *Q. J. Med.* **43**, 293–319.

Cavanagh, J. B., and Gregson, M. (1978). Some effects of a thallium salt on the proliferation of hair follicle cells. *J. Pathol.* **125**, 179–191.

Chapin, R. E., Norton, R. M., Popp, J. A., and Bus, J. S. (1982). The effect of 2,5-hexandione on reproductive hormones and testicular enzyme activities in the F-344 rat. *Toxicol. Appl. Pharmacol.* **62**, 262–272.

Chapin, R. E., White, R. D., Morgan, K. T., and Bus, J. S. (1984). Studies of lesions induced in the testis and epididymis of F-344 rats by inhaled methyl chloride. *Toxicol. Appl. Pharmacol.* **76**, 328–343.

Chen, C., and Jones, W. R. (1982). Human *in vitro* fertilization using a murine model. *In* "*In Vitro* Fertilization and Embryo Transfer" (E. S. E. Hafez, Ed.), pp. 111–115. MIP Press, Boston.

Creasy, D. M., and Foster, P. M. D. (1984). The morphological development of glycol ether-induced testicular atrophy in the rat. *Exp. Mol. Pathol.* **40**, 169–176.

Davis, L. E., Standefer, J. C., Kornfeld, M., Abercrombie, D. M., and Butler, C. (1981). Acute thallium poisoning: Toxicological and morphological studies of the nervous system. *Ann. Neurol.* **10**, 38–44.

Dixon, R. L., and Hall, J. L. (1982). Reproductive toxicology. *In* "Principles and Methods of Toxicology" (A. W. Hayes, Ed.), pp. 107–140. Raven Press, New York.

Dym, M. (1977). The role of Sertoli cells in spermatogenesis. *In* "Male Reproductive System" (R. D. Yates and M. Gordon, Eds.), pp. 155–169. Masson, New York.

Fishman, W. H. (1974). Beta-glucuronidase. *In* "Methods in Enzymatic Analysis" (H. U. Bergmeyer, Ed.), Vol. 2, pp. 929–943. Academic Press, New York.

Gerlach, U., and Hibby, W. (1974). Sorbitol dehydrogenase. *In* "Methods in Enzymatic Analysis" (H. U. Bergmeyer, Ed.), Vol. 2, pp. 569–573. Academic Press, New York.

Gravis, C. J., Chen, I. L., and Yates, R. D. (1977). Ultrastructure and cytochemistry of epinephrine-induced testicular degeneration. *In* "Male Reproductive System" (R. D. Yates and M. Gordon, Eds.), pp. 35–55. Masson, New York.

Gunn, S. A., and Gould, T. C. (1970). Cadmium and other mineral elements. *In* "The Testis" (D. Johnson, W. R. Gomes, and H. L. Vandemark, Eds.), Vol. 3, pp. 378–482. Academic Press, New York.

Hasan, M., and Ali, S. F. (1981). Effects of thallium, nickel, and cobalt administration on the lipid peroxidation in the different regions of the rat brain. *Toxicol. Appl. Pharmacol.* **57**, 8–13.

Hodgen, G. D., and Sherins, R. J. (1973). Enzymes as markers of testicular growth and development in the rat. *Endocrinology* **93**, 985–989.

Karnovsky, M. J. (1965). A formaldehyde–glutaraldehyde fixative of high osmolarity for use in electron microscopy. *J. Cell Biol.* **27**, 137–138.

Kluwe, W. M., Lamb, J. C., Greenwell, A., and Harrington, F. W. (1983). 1,2-Dibromo-3-chloropropane (DBCP)-induced infertility in male rats mediated by a post-testicular effect. *Toxicol. Appl. Pharmacol.* **71**, 294–298.

Lameijer, W., and Van Zwieten, P. A. (1976). Acute cardiovascular toxicity of thallium(I) ions. *Arch. Toxicol.* **35**, 49–61.

Lameijer, W., and Van Zwieten, P. A. (1977). Kinetic behaviour of thallium in the rat. *Arch. Toxicol.* **37**, 265–273.

Leblond, C. P., and Clermont, Y. (1952). Definition of the stages of the cycle of the seminiferous epithelium in the rat. *Ann. N.Y. Acad. Sci.* **55**, 548–573.

Lowry, O. H., Rosenbrough, N. J., Farr, A. L., and Randall, R. J. (1951). Protein measurement with the Folin phenol reagent. *J. Biol. Chem.* **193**, 265–275.

Males, J. L., and Turkington, R. W. (1971). Hormonal control of lysosomal enzymes during spermatogenesis in the rat. *Endocrinology* **88**, 579–588.

Manzo, L., Scelsi, R., Moglia, A., Poggi, P., Alfonsi, E., Pietra, R., Mousty, F., and Sabbioni, E. (1983). Long-term toxicity of thallium (I) in the rat. *In* "Chemical Toxicology and Clinical Chem-

istry of Metals" (S. S. Brown and J. Savory, Eds.), pp. 401–405. Academic Press, Orlando/London.

Mills, N. C., and Means, A. R. (1972). Sorbitol dehydrogenase of rat testis: Changes of activity during development, after hypophysectomy and following gonadotrophic hormone administration. *Endocrinology* **91**, 147–156.

Mukhtar, H., Lee, I. P., and Bend, J. R. (1978). Glutathione-S-transferase activities in rat and mouse sperm and human semen. *Biochem. Biophys. Res. Commun.* **83**, 1093–1098.

Omaye, S. T., and Tappel, A. L. (1975). Effect of cadmium chloride on the rat testicular soluble selenoenzyme, glutathione peroxidase. *Res. Commun. Chem. Pathol. Pharmacol.* **12**, 695–711.

Reddy, K. J., and Svoboda, D. J. (1967). Lysosomal activity in Sertoli cells of normal and degenerating seminiferous epithelium of rat testis. *Amer. J. Pathol.* **51**, 1–17.

Richelmi, P., Baldi, C., Bellomo, G., Manzo, L., and Bertè, F. (1984). Thallium toxicity in isolated rat hepatocytes: the role of glutathione. *In* "Proceedings, 22nd National Congress of the Italian Society of Pharmacology, Abst. p. 307.

Sabbioni, E., and Manzo, L. (1980). Metabolism and toxicity of thallium. *In* "Advances in Neurotoxicology" (L. Manzo, Ed.), pp. 249–270. Pergamon Press, Oxford New York.

Sabbioni, E., Marafante, E., Rade, J., Di Nucci, A., Gregotti, C., and Manzo, L. (1980). Metabolic patterns of low and toxic doses of thallium in the rat. *In* "Mechanisms of Toxicity and Hazard Evaluation" (B. Holmstedt, R. Lauwerys, M. Mercier, and M. Roberfroid, Eds.), pp. 559–564. Elsevier, Amsterdam.

Saville, B. (1958). A scheme for the colorimetric determination of microgram amounts of thiols. *Analyst* **83**, 670–672.

Setchell, B. P., and Hinks, N. T. (1967). The importance of glucose in the oxidative metabolism of the testis of the conscious ram and the role of the pentose cycle. *Biochem. J.* **102**, 623–630.

Smith, C., and Carson, B. L. (1977). "Trace Metals in the Environment," Vol. I. "Thallium." Ann Arbor Sci. Publ., Ann Arbor.

Sullivan, J. L., Smith, F. A., and Garman, R. H. (1979). Effects of fluoroacetate on the testis of the rat. *J. Reprod. Fertil.* **56**, 201–207.

vis, J. C., Turk, G. C., and Green, R. B. (1982). Laser enhanced ionization spectrometry. *Anal. Chem.* **54**, 1006A.

Truhaut, R. (1958). "Recherches sur la toxicologie du thallium." Institut National de Securité pour la Prevention des Accidents du Travail, Paris.

Walter, K., and Schütt, C. (1974). Acid and alkaline phosphatase in serum. *In* "Methods in Enzymatic Analysis" (H. U. Bergmeyer, Ed.), Vol. 2, pp. 856–859. Academic Press, New York.

Zitko, V. (1975). Toxicity and pollution potential of thallium. *Sci. Total Environ.* **4**, 185–192.