ECOTOXICOLOGY AND ENVIRONMENTAL SAFETY 4, 39–50 (1980)

59326

Toxicity, Fertility, Teratogenicity, and Dominant Lethal Tests in Rats Administered Cadmium Subchronically

I. Toxicity Studies

SHIZUYO SUTOU, KYOKO YAMAMOTO, HIROMI SENDOTA, KOZUE TOMOMATSU, YASUYOSHI SHIMIZU, AND MINEKAZU SUGIYAMA

Nomura Research Institute, 1600 Kajiwara, Kamakura, Kanagawa, Japan

Received September 17, 1979

In order to obtain an overall understanding of the toxicity of cadmium (Cd), a single experimental series was designed to investigate the diverse effects of Cd. Four groups of Sprague–Dawley rats, each of which consisted of 14 male and 14 female rats, were administered Cd ($CdCl_2$) orally at dose levels of 0, 0.1, 1.0, 10.0 mg/kg/day for 6 weeks. After this, the animals were mated for 3 weeks, changing partners every week, for fertility and teratogenicity tests. Cd was given during this mating period. Females were administered Cd during gestation and sacrificed on the 20th day of gestation for fetal examination. After a total of 9 weeks administration, males were subjected to dominant lethal tests by mating 2 females per male per week for 6 weeks. Pregnant females were killed on the 13th day of gestation to test for dominant lethality. This paper reports the results of the general toxicity tests. The main toxic signs, seen only in the 10 mg/kg group, were repression of food intake and body weight gain, depilation, whitening of the incisors, and salivation. Hematological analyses showed that the number of RBC increased while hemoglobin and hematocrit levels decreased, and the number of WBC increased, mainly as a result of neutrophilia. Serum biochemical analyses indicated increased levels of GPT and creatinine, reflecting damage to the liver and kidneys. Increased glucose levels were seen in males. A major change found at the time of autopsy by macroscopic observation of organs was hypertrophy of the jejunum and ileum with a darkish-brown color in nonpregnant females of the 10 mg/kg group. Microscopically, hyperplasia with a high frequency of mitotic figures was seen in the lamina propria mucosae. The weight of the thymus decreased and the weight of the adrenals increased in both males and females. The weight of the ovaries decreased. Major histopathological changes were focal necrosis in the liver and hyperplasia of the adrenal cortices with patchy necrosis in nonpregnant females of the 10.0 mg/kg group. Determination of Cd in the liver and kidneys suggested that excretion of the accumulated Cd was slow. Two aspects of Cd toxicity, i.e., the inhibition of nutrient resorption by unresorbed Cd and the toxicity expressed by resorbed Cd, as well as the causative factors of the adrenal hyperplasia, are discussed.

INTRODUCTION

Cadmium (Cd) causes diverse toxicity in experimental animals and man; it is associated with the so-called "itai-itai" disease. Some of the reported toxic effects of Cd, however, such as chemical sterilization (Parizek, 1960), teratogenesis (Ferm and Carpenter, 1967), and cytogenetic anomalies (Deknudt and Léonard, 1975; Watanabe *et al.*, 1979) were observed under extremely artificial conditions such as intratesticular administration of Cd at a high dose level and intraperitoneal administration of Cd during organogenesis. Since exposure routes to Cd are usually oral or through inhalation, and exposure is chronic, oral and subchronic

0147-6513/80/010039-12$02.00/0
Copyright © 1980 by Academic Press, Inc.
All rights of reproduction in any form reserved.

7225



FIG. 1. Experimental design.

administration was chosen for our experiments. As the toxic effects of Cd are diverse, attempts were made to investigate a wide range of toxicity in a single experimental series, namely, general toxicity, fertility, teratogenicity, and dominant lethality. This paper reports the results of the toxicity studies.

MATERIALS AND METHODS

The experimental design is illustrated in Fig. 1. Sprague–Dawley rats at 4 weeks of age were purchased from Shizuoka Agricultural Cooperative Association for Laboratory Animals. The animals were freely supplied with pelleted dry chow (NMF, Oriental Yeast Co.) and water and kept in wire cages in pairs. The cages were placed in a fully air-conditioned facility where the temperature was regulated at 24 ± 1°C, and the humidity at 55 ± 5%. After a taming period of a week, four groups, each of which consisted of 14 males and 14 females, were orally administered Cd ($CdCl_2$, Wako Pure Chemical Industries, Ltd.) at dose levels of 0, 0.1, 1.0, and 10.0 mg/kg/day for 6 weeks. Males and females in each group were mated 6 days a week for a maximum of 3 weeks, chaning partners every week if necessary. Administration continued throughout the mating period. Copulation was confirmed by detection of spermatozoa in vaginal smears. Pregnant females were administered Cd throughout gestation and were killed on the 20th day of gestation for fetal examination. Nonpregnant females were killed after a total administration period of 13 weeks. After a total of 9 weeks administration, males were subjected to dominant lethal tests by mating 2 females per male per week for 6 weeks. Pregnant females were killed on the 13th day of gestation, and the numbers of corpora lutea, live fetuses, early deaths (no remnants of fetuses), and late deaths (remnants of fetuses) were recorded. One week after the cessation of dominant lethal tests, which represents a recovery period of 50 days, male rats were killed and examined.

Body weight was determined once a week for males, and once a week before

gestation and once every 2 days after gestation for females. Food and water consumption was measured once a week for the first 6 weeks. After mating, the consumption was determined twice a week for pregnant females only.

Hematological observations were carried out on blood from the orbital plexus venosus. Numbers of RBC and WBC were counted with a micro cell counter (Toa Medical Electronics Co.). Hematocrit was determined by a centrifugation method and hemoglobin, by a cyanmethemoglobin method. Fractionation of WBC was performed on blood smears stained with Wright–Giemsa fluid.

Serum biochemical analyses were carried out with Hitachi automatic analyzer (Model 400, Hitachi, Ltd.). Parameters tested were GOT (a modification of the method of Reitman–Frankel), GPT (as for GOT), alkaline phosphatase (a modification of the method of King–King), LDH (colorimetry of pyruvate by reaction with dinitrophenylhydrazine), total protein (the biuret method), albumin (the BCG method), blood glucose (the glucose oxidase method), urea–nitrogen (the urease–indophenol method), creatinine (the method of Jeffe), bilirubin (the method of Jendrassik–Cleghorn), and globulin (total protein minus albumin).

Animals were bled to death under anesthesia with ethylether and subjected to autopsy. In the cases of pregnant females used for fertility and teratogenicity studies, the thymus, heart, lungs, liver, kidneys, spleen, adrenals, ovaries, and placentas were removed and weighed. The number of corpora lutea was counted under a stereoscopic microscope. The number and location of live, resorbed, and macerated fetuses were counted and recorded. Live fetuses were subjected to sex determination, measurement of body weight, body length, and tail length, and examination for external malformations. About one-third of the live fetuses were fixed in Bouin's fluid for visceral examination by the method of Wilson (1965), and the other two-thirds were fixed in 70% ethanol for skeletal examination by the method of Dawson (1926).

After hematological examination, blood was collected from the arteriae femoralis of male rats and sera were isolated by centrifugation for biochemical analyses. After macroscopic examination, the thymus, heart, lungs, liver, adrenals, kidneys, spleen, and testes were removed and weighed. In nonpregnant females, the ovaries and uterus instead of testes were removed and weighed.

The organs of three male animals from each group, of three female animals from the 0 and 10 mg/kg groups, and of all nonpregnant females were fixed in formalin fixative, stained with hematoxylin–eosin, and examined histologically. In addition to the main organs, the cerebrum, cerebellum, thyroid, eyes, stomach, duodenum, ileum, rectum, pancreas, urinary bladder, uterus, and ovaries were also examined in nonpregnant females.

Examination of the fundus was carried out with a fundus camera (Kowa RC2, Kowa Co.). The ratio of the width of veins to that of arteries was determined by measuring three pairs of veins and arteries per animal.

One, one, and two pregnant females from the 0, 1.0, and 10 mg/kg groups, respectively, were subjected to rentogenographic observation using Softex (CMBW, Softex Co.).

The determination of Cd in the liver and kidneys was carried out by homogenization of the tissues, followed by lyophilization, oxidization to ash with a plasma reactor (PR-503, Yamato Scientific Co.), dissolution in 1/50 N HCl, and analysis with an atomic absorption spectrophotometer (Model 308, Hitachi, Ltd.).

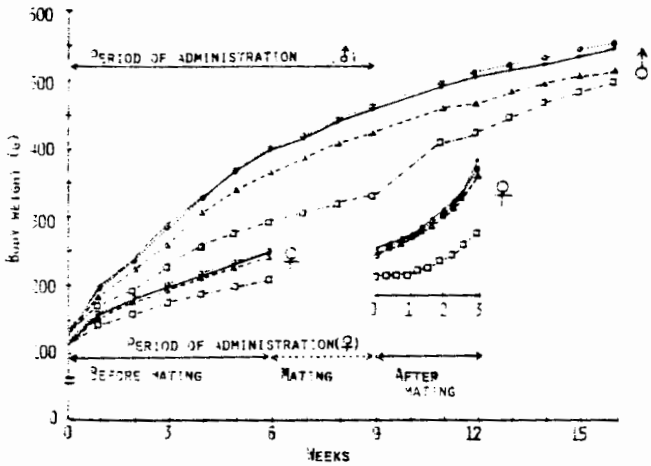

FIG. 2. Body weight changes of male and female rats. Control (●); 0.1 mg/kg (○); 1.0 mg/kg (△); and 10.0 mg/kg (□).

RESULTS

General Symptoms

One female from each of the 0.1, 1.0, and 10.0 mg/kg groups was killed by misadministration. Major toxic symptoms observed in 14 males and 13 females in the highest dose group (10 mg/kg) were as follows: depilation, 2 males and 8 females; salivation, 3 males and 6 females; bleaching of incisors, 3 females. Depilation began appearing 1 week after the start of administration at the head back area, and required about 1 month or more for recovery. Some did not recover. Animals of the other groups did not show such major symptoms.

Body Weight

Figure 2 shows the changes of body weight. Administration of 1.0 mg/kg slightly suppressed the body weight gain of male animals and no recovery was seen during a period of 7 weeks. Severe suppression of weight gain was brought about by the administration of 10.0 mg/kg. The recovery of body weight gain was biphasic, being initially rapid just after the cessation of Cd administration and then slow throughout the remaining recovery period. Mean body weight gains for the 0, 0.1, 1.0, and 10.0 mg/kg groups during the administration period were 329, 330, 295, and 203 g, and those during the recovery period were 86, 94, 89, and 161 g, respectively. Only the 10.0 mg/kg group showed growth retardation in females both before and after mating. Body weight gains for the 0, 0.1, 1.0, and 10.0 mg/kg groups was 129, 130, 122, and 91 g before mating and 131, 126, 120, and 62 g during gestation, respectively. The poor growth of pregnant females in the 10.0 mg/kg group was due to the combined effect of the toxicity of Cd and the small number of live fetuses, which in any case showed growth retardation.

Food and Water Consumption

There were no marked differences in food and water consumption among the 0, 0.1, and 1.0 mg/kg groups. Animals in the 10.0 mg/kg group consumed less food and

water than those in the other three groups. When the food efficients were calculated, the 10.0 mg/kg group showed a smaller value than the others. The food coefficients (g body weight gain/g food consumption/day) of male rats in the fourth week, for example, were 0.139, 0.136, 0.147, and 0.072 for the 0, 0.1, 1.0, and 10.0 mg/kg groups, respectively.

Organ Weight

Table 1 shows the organ weights of male and pregnant female rats. Since the males were killed after a recovery period of 7 weeks, two factors, the lasting toxicity of Cd and the recovery process, were considered to be reflected concomitantly in the males. As the females were killed during the period of administration, toxicity was reflected more directly in the females. The organ weights of the thymus, liver, and ovaries decreased. However, since the body weight of pregnant animals is affected by fetuses, the relative organ weights are not reliable. Thus, it is difficult to determine whether the decreased organ weight was a result of body weight decline or specific toxicity of Cd. The weight of the adrenals, however, increased in spite of the lower body weight, and this was also the case for male animals. In males, the relative organ weights of the lung, heart, liver, and spleen were greater than those of the control group, which might reflect some aspect of the recovery phase.

Hematology

Hematological findings are listed in Table 2. Here again, females reflect the toxicity of Cd more directly than males. While the number of RBC increased in females of the 10 mg/kg group, levels of hemoglobin and hematocrit were greatly reduced, indicating the appearance of smaller RBC than normal. The number of WBC also increased. Fractionation of WBC indicated that the main contribution was due to the increased number of neutrophils, that is, neutrophilia. Increased numbers of RBC and WBC were also seen in males. Hemoglobin and hematocrit, however, had recovered to normal levels.

Serum Biochemical Analyses

The results of serum biochemical analyses are shown in Table 3. Nonpregnant females showed increased levels of GPT and creatinine, indicating damage to the liver and kidneys, respectively. After a recovery period, the males showed significant differences from the control in having a decreased level of albumin, an increased level of globulin, a decreased A/G ratio, and an increased level of creatinine. Thus, toxic effects of Cd were still apparent in the liver and kidneys after 7 weeks recovery.

Histological Examination

No marked changes were observed in the main organs from male and pregnant female rats in any group. Sporadic findings included slight infiltration of small round cells around the bronchus or arteries in the lungs and tiny granuloma in the liver.

In nonpregnant females, focal necrosis was seen in the liver in five animals out of

TABLE 1

ABSOLUTE AND RELATIVE ORGAN WEIGHTS OF ANIMALS

Rats		Males				Pregnant females			
Dose (mg/kg/day)		0	0.1	1.0	10	0	0.1	1.0	10
No. of animals		14	14	14	14	11	10	12	5
Thymus	(mg)	251 ± 63[a]	230 ± 42	205 ± 39*	222 ± 59	271 ± 51	272 ± 61	238 ± 48	131 ± 38**
	(mg%)	47.1 ± 13.0	41.9 ± 7.7	40.5 ± 8.1	45.2 ± 11.7				
Lung	(g)	1.71 ± 0.15	1.84 ± 0.27	1.72 ± 0.14	1.80 ± 0.24	1.38 ± 0.10	1.36 ± 0.17	1.44 ± 0.24	1.23 ± 0.20
	(g%)	0.319 ± 0.035	0.334 ± 0.046	0.348 ± 0.035*	0.369 ± 0.063*				
Heart	(g)	1.43 ± 0.13	1.49 ± 0.21	1.44 ± 0.13	1.37 ± 0.15	0.93 ± 0.08	0.93 ± 0.09	0.98 ± 0.11	0.86 ± 0.17
	(g%)	0.259 ± 0.016	0.270 ± 0.020	0.291 ± 0.031**	0.280 ± 0.028*				
Liver	(g)	13.9 ± 1.9	14.5 ± 1.8	13.2 ± 1.3	14.1 ± 1.9	15.3 ± 1.2	14.9 ± 1.9	15.6 ± 1.4	12.9 ± 2.2*
	(g%)	2.57 ± 0.22	2.62 ± 0.13	2.60 ± 0.16	2.88 ± 0.33**				
Spleen	(mg)	796 ± 139	828 ± 141	798 ± 70	842 ± 186	678 ± 115	661 ± 95	663 ± 84	630 ± 70
	(mg%)	147 ± 20	150 ± 16	157 ± 11	170 ± 29*				
Kidneys	(g)	3.40 ± 0.43	3.42 ± 0.45	3.33 ± 0.32	3.18 ± 0.32	1.99 ± 0.19	1.97 ± 0.29	1.98 ± 0.23	1.85 ± 0.23
	(g%)	0.629 ± 0.049	0.620 ± 0.062	0.656 ± 0.040	0.645 ± 0.027				
Adrenals	(mg)	66 ± 6	66 ± 12	61 ± 9	68 ± 10	87 ± 9	83 ± 14	84 ± 10	107 ± 8**
	(mg%)	12.3 ± 1.5	12.0 ± 1.5	12.1 ± 1.4	13.8 ± 1.9*				
Testes	(g)	3.42 ± 0.24	3.48 ± 0.20	3.29 ± 0.23	3.53 ± 0.27				
	(g%)	0.637 ± 0.58	0.640 ± 0.079	0.652 ± 0.076	0.792 ± 0.073				
Ovaries	(mg)					145 ± 11	129 ± 20*	141 ± 20	112 ± 17**
Carcass	(g)	410 ± 42	419 ± 35	392 ± 32	375 ± 35*	231 ± 21	224 ± 19	217 ± 18	154 ± 20**
	(g%)	75.8 ± 1.5	76.1 ± 2.8	77.2 ± 3.3	76.2 ± 2.1				

[a] Mean ± SD

* Significantly different from the control at $P < 0.05$.

** Significantly different from the control at $P < 0.01$.

Testes	(g)	3.42 ± 0.24	3.48 ± 0.20	3.29 ± 0.23	3.53 ± 0.27							
	(g%)	0.637 ± 0.58	0.640 ± 0.079	0.652 ± 0.076	0.792 ± 0.073							
Ovaries	(mg)					145 ± 11	129 ± 20*	141 ± 20	217 ± 18	112 ± 1	154 ± 20**	
Carcass	(g)	410 ± 42	419 ± 35	392 ± 32	375 ± 35*	231 ± 21	224 ± 19					
	(g%)	75.8 ± 1.5	76.1 ± 2.8	77.2 ± 3.3	76.2 ± 2.1							

* Mean ± SD
* Significantly different from the control at $P < 0.05$.
** Significantly different from the control at $P < 0.01$.

TABLE 2

Hematological Findings

Rats	Males				Nonpregnant females		
Dose (mg/kg/day)	0	0.1	1.0	10	0	1.0	10
No. of animals	14	14	14	14	2	1	8
Red blood cells (10^4/mm^3)	764 ± 72*	726 ± 68	755 ± 74	836 ± 96**	803 ± 14	835	853 ± 30*
White blood cells (10^2/mm^3)	80 ± 16	81 ± 16	88 ± 20	108 ± 17**	52 ± 9.9	129	98 ± 20.1
Hemoglobin (g/dl)	17.4 ± 0.8	16.6 ± 0.5**	17.0 ± 0.3	17.5 ± 0.7	16.8 ± 5.7	16.8	14.3 ± 1.5*
Hematocrit (%)	47.0 ± 1.7	46.3 ± 1.1	46.8 ± 1.0	47.0 ± 1.6	45.3 ± 1.1	45.0	38.5 ± 2.3**
Fractionation of WBC (%)							
Eosinophils					0.5 ± 0	0.5	0.6 ± 0.2
Neutrophils					10.8 ± 3.2	9.0	21.1 ± 9.5
Lymphocytes					88.0 ± 2.8	90.0	77.7 ± 9.7
Monocytes					0.8 ± 0.4	0.5	0.6 ± 0.2
Basophils					0	0	0

* Mean ± SD.
* Significantly different from the control at $P < 0.05$.
** Significantly different from the control at $P < 0.01$.

eight in the 10 mg/kg group (Fig. 3). Infiltration of small round cells in the kidneys was observed in one out of three animals in the control group and four out of eight in the 10 mg/kg group. Slight atrophy of glomeruli was seen in the kidneys from two animals out of eight in the 10 mg/kg group. Pyelitis was seen in one out of three animals in the 0.1 mg/kg group. On macroscopic observation during autopsy, nonpregnant females of the 10 mg/kg group showed abnormally enlarged jejunums and ileums, with a darkish-brown color.

Microscopically, hypertrophy and hyperplasia of the lumina propria mucosae with a high frequency of mitotic figures was observed (Fig. 4). The weight of the adrenals was increased in spite of the decreased body weight (Table 1). The adrenal cortex showed hyperplasia with patchy necrosis (Fig. 5).

TABLE 3

Serum Biochemical Analyses

Rats	Males				Nonpregnant females		
Dose (mg/kg/day)	0	0.1	1.0	10	0	1.0	10
No. of animals	14	14	14	14	2	1	8
GOT (K.U.)	101 ± 10*	102 ± 12	99 ± 19	100 ± 15	114 ± 30	97	125 ± 10
GPT (K.U.)	32.0 ± 6.3	33.2 ± 7.9	31.4 ± 4.4	31.9 ± 6.4	26 ± 8	25	61.4 ± 7.8**
ALP (K.A.U.)	9.2 ± 2.5	11.4 ± 4.9	10.8 ± 4.8	12.3 ± 5.9	7.5 ± 1.9	4.9	7.8 ± 2.7
LDH (C.W.U.)	165 ± 3.4	153 ± 54	139 ± 41	149 ± 38	105 ± 13	112	149 ± 41
T-P (g/dl)	6.4 ± 0.7	6.6 ± 0.6	6.4 ± 0.8	6.9 ± 0.5	7.1 ± 0.1	7.6	6.1 ± 0.7
ALB (g/dl)	4.1 ± 0.1	4.2 ± 0.6	4.0 ± 0.1*	3.9 ± 0.1**	4.1 ± 0.1	4.1	4.0 ± 0.3
GLB (g/dl)	2.3 ± 0.7	2.4 ± 0.8	2.5 ± 0.8	3.0 ± 0.4*	3.1 ± 0.2	3.5	2.1 ± 0.6
ALB/GLB	2.0 ± 0.8	2.3 ± 2.0	1.8 ± 0.7	1.3 ± 0.4*	1.4 ± 0.1	1.2	2.1 ± 0.6
BIL (mg/dl)	0.28 ± 0.04	0.31 ± 0.05	0.27 ± 0.05	0.30 ± 0.04	0.25 ± 0.07	0.3	0.28 ± 0.05
CRE (mg/dl)	23.1 ± 2.6	23.6 ± 1.2	25.1 ± 1.5*	26.6 ± 2.3**	24 ± 0	27	27.9 ± 2.0*
GLU (mg/dl)	147 ± 29	152 ± 18	150 ± 12	166 ± 12*	124 ± 23	155	130 ± 19
U-N (mg/dl)	19.0 ± 2.4	19.2 ± 2.8	18.9 ± 1.7	19.4 ± 2.0	13.2 ± 0.4	29.6	21.0 ± 4.7

* Mean ± SD.
* Significantly different from the control at $P < 0.05$.
** Significantly different from the control at $P < 0.01$.

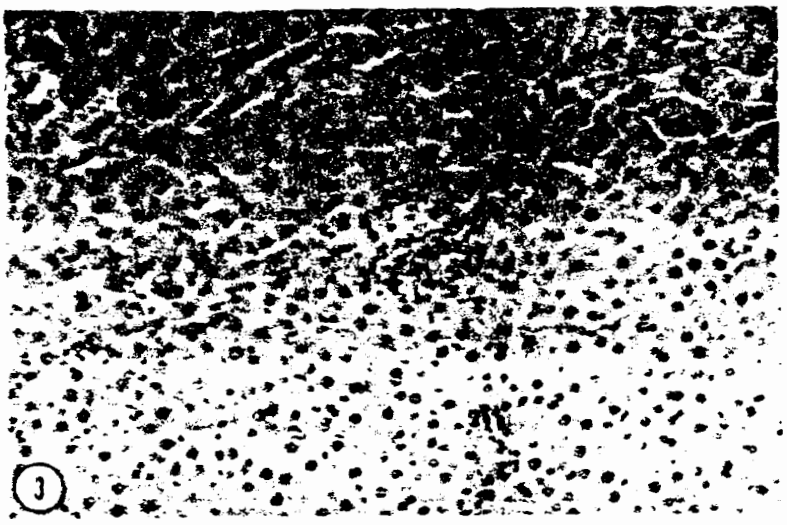

3



4



5

Fundus Examination

The fundus of nonpregnant females showed no marked changes. When the ratio of the width of veins to that of arteries was calculated, values of 1.41 (n = 2) in the control group, 1.5 (n = 1) in the 1.0 mg/kg group, and 1.60 (n = 8) in the 10 mg/kg group were obtained. Slight vasoconstriction appeared to be present. However, the small number of animals and the small magnitude of the differences betweeen the control and treated animals mean that it is not possible to conclude whether or not there was an adverse effect of Cd on the blood vessels.

Rentogenography

At autopsy, the bones of pregnant females of the 10 mg/kg group showed less resistance to cutting and seemed more fragile that those of the control. Rentogenograms of one, one, and two animals from the control, 1.0 mg/kg group, and 10.0 mg/kg group, respectively, showed no marked differences among them. Osteomalacia was not detected by this method.

Effect of Cd on Mating Behavior

Mating was carried out 6 days a week for 3 weeks. Two, one, and eight females from the 0, 1.0, and 10.0 mg/kg groups, respectively, did not perform copulation. One female from the 0 mg/kg group and two females from the 0.1 mg/kg group copulated abortively. The average time span until copulation was 3.6 (n = 11), 2.9 (n = 10), 4.9 (n = 12), and 9.0 (n = 5) days in the 0, 0.1, 1.0, and 10.0 mg/kg groups, respectively. The highest dose group showed delay in performing copulation and gave a reduced copulation ratio.

Content of Cd

The contents of Cd in the liver and kidneys are shown in Fig. 6. In general, the kidneys contained more Cd than the liver on the basis of unit weight. However, the liver outweighs the kidneys by far (Table 1), so that the total content of Cd is much greater in the liver than in the kidneys. Nonpregnant females received most Cd and contained most Cd. Since pregnant females received Cd until the 19th day of gestation, the later animals became pregnant, the more Cd they received. Males received Cd for 9 weeks then received none for 7 weeks. Though it is difficult to compare males with females, it seems clear that excretion of Cd from the liver and kidneys is delayed.

DISCUSSION

Marked anemia accompanied by reduced hemoglobin and stunted growth seems to be the first manifestation of chronic toxicity of Cd in rats, as shown here and by others (Fitzhugh and Meiler, 1941; Wilson *et al.*, 1941; Decker *et al.*, 1958); similar results were also obtained in pigs (Barker and Trout, 1973). Wilson *et al.* (1941)

FIG. 3. Focal necrosis in the liver from a nonpregnant animal of the 10.0 mg/kg group (× 100).

FIG. 4. Hypertrophy and hyperplasia of the ileum from a nonpregnant female of the 10.0 mg/kg group (× 100).

FIG. 5. Hyperplasia of the adrenal cortex with patchy necrosis observed in a nonpregnant female of the 10.0 mg/kg group (× 100).

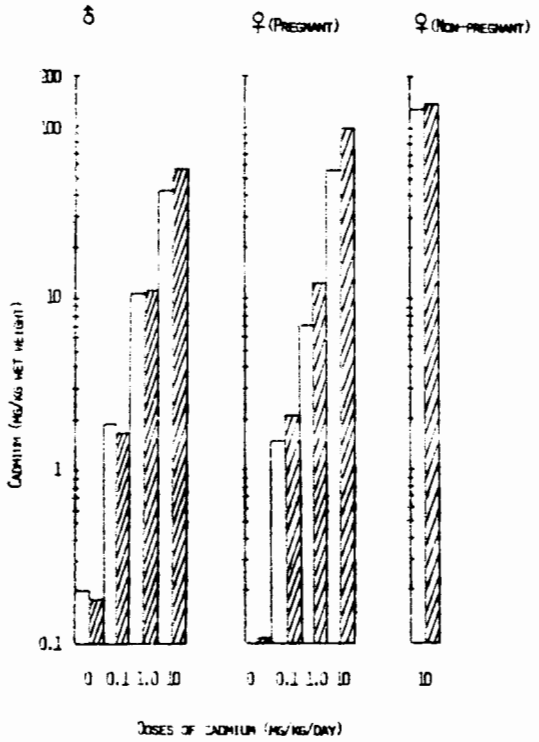

FIG. 6. Accumulation of cadmium in the liver (open bars) and kidneys (hatched bars).

reported that a normal rate of growth was rapidly attained on changing from a 0.0125% Cd diet to the control diet and concluded that no permanent damage resulted from Cd ingestion so far as growth rate was concerned. Close examination, however, indicated that the recovery of body weight after Cd ingestion was biphasic, as shown in Fig. 2. First there is a rapid phase just after the discontinuance of Cd administration, followed by a slow phase.

Rapid recovery is possible only when the Cd toxicity is temporary and reversible. The early phase may thus correspond to the inhibition of resorption of nutrients by unresorbed Cd in the digestive tract. More than 90% of Cd administered orally remains in the tract without being resorbed (Friberg *et al.*, 1974), causing water to remain in the tract. Either this water retention and/or competitive or enzyme-inhibiting action of Cd may inhibit the resorption of nutrients, including iron cations. Inhibition of nutrient resorption would result in adaptive hyperplasia of the intestine (Fig. 4), and a limited supply of iron would lead to anemia (Table 2).

The slow recovery phase may correspond to recovery from the lasting toxic effect of resorbed Cd, mainly on the liver and kidneys. While Cd is initially accumulated in the liver, metallothionein-bound Cd is concentrated in the kidneys (Cherian *et al.*, 1976; Tanaka *et al.*, 1975). Our data (Fig. 6) show that Cd was accumulated in the liver and kidneys almost in proportion to the dose level and that only a small fraction of the accumulated Cd was excreted during 7 weeks. Damage to the liver and kidneys was detected in serum biochemical analyses (Table 3) and histologically (Fig. 3).

The increased weight of the adrenals both in females, in spite of their decreased body weight, and in males, in spite of the recovery period (Table 1), is noteworthy. As Cd has been reported to inhibit steriod biosynthesis (Kar and Das, 1959) and to be accumulated in the adrenal cortex (Dencker, 1975), it is likely that circulating cortisol levels are diminished, leading to a compensatory increase in ACTH release by negative feedback control. Consequently, hyperplasia of the adrenal cortex (Fig. 5) arises.

Patchy necrosis and the durable nature of the adrenal hyperplasticity suggest that Cd accumulation per unit weight is high, and that excretion is slow. Experiments using radioactive Cd by Dencker (1975) showed that radioactivity was accumulated mainly in the liver, kidney, adrenal cortex, pituitary, and placenta in pregnant hamsters and mice.

Bleaching of the incisors was observed in our studies, as reported by others (Wilson *et al.*, 1941; Fitzhugh and Meiller, 1941; Ginn and Volker, 1944; Decker *et al.*, 1958). The simultaneous occurrence of reduced hemoglobin and bleaching of the incisors are indicative of an inadequate iron supply. It has been reported that enamel pigments are similar in structure to hemoglobin (Ginn and Volker, 1944).

Fitzhugh and Meiller (1941) and Wilson *et al.* (1941) reported that anemia was accompanied by reduced hemoglobin and a reduced number of RBC. In our studies, hemoglobin levels were reduced, but the RBC count was increased. This may be because the Cd toxicity was only moderately severe, or may represent a short-term response which might be reversed later. Wilson *et al.* (1941) reported that the bone marrow from Cd poisoned animals was very hyperplastic as compared with the controls.

ACKNOWLEDGMENT

This work was supported in part by a grant from the Environmental Agency, Japan.

REFERENCES

BARBER, R. J., AND TROUT, A. K., JR. (1973). Cadmium toxicity in growing swine. *J. Nutr.* **103**, 964–972.

CHERIAN, M. G., GOYER, R. A., AND DELAQUERRIERE-RICHARDSON, L. (1976). Cadmium-metallothionein-induced nephropathy. *Toxicol. Appl. Pharmacol.* **38**, 399–408.

DAWSON, A. B. (1926). A note on the staining of the skeleton of cleared specimens with arizarin red. *Stain Technol.* **1**, 123–124.

DECKER, L. E., BYERRUM, R. U., DECKER, C. F. HOPPERT, C. A., AND LANGHAM, R. F. (1958). Chronic toxicity studies. I. Cadmium administration in drinking water to rats. *Arch. Ind. Health* **18**, 228–231.

DEKNUDT, G., AND LÉONARD, A. (1975). Cytogenetic investigation on leucocytes of workers from a cadmium plant. *Environ. Physiol. Biochem.* **5**, 319–327.

DENCKER, L. (1975). Possible mechanisms of cadmium fetotoxicity in golden hamsters and mice: Uptake by the embryo, placenta and ovary. *J. Reprod. Fert.* **43**, 461–471.

FERM, V. H., AND CARPENTER, S. J. (1967). Teratogenic effect of cadmium and its inhibition by zinc. *Nature (London)* **216**, 1123.

FITZHUGH, O. G., AND MEILLER, F. H. (1941). The chronic toxicity of cadmium. *J. Pharmacol. Exp. Ther.* **72**, 15.

FRIBERG, L., PISCATOR, M., NORDBERG, G. F., AND KJELL STRÖM, T. (1974). *Cadmium in the Environment*, 2nd ed. CRC Press, Cleveland.

GINN, J. T., AND VOLKER, J. F. (1944). Effect of cadmium and fluorine on the rat dentition. *Proc. Soc. Exp. Biol. Med.* **57**, 189–191.

KAR, A. B., AND DAS, R. P. (1959). Effect of cadmium chloride on the response of the uterus to progesterone. *J. Sci. Ind. Res.* **C18**, 79–81.

PARIZEK, J. (1960). Sterilization of the male by cadmium salts. *J. Reprod. Fert.* **1**, 249–309.

TANAKA, K., SUEDA, K., ONOSAKA, S., AND OKAHARA, K. (1975). Fate of ^{109}Cd-labeled metallothionein in rats. *Toxicol. Appl. Pharmacol.* **33**, 258–266.

WATANABE, T., SHIMADA, T., AND ENDO, A. (1979). Mutagenic effects of cadmium on mammalian oocyte chromosomes. *Mutat. Res.* **67**, 349–356.

WILSON, J. (1965). Methods for administering agents and detecting malformations in experimental animals. In *Teratology Principles and Techniques* (J. Wilson and J. Warkany, eds.), pp. 262–272. Univ. of Chicago Press, Chicago.

WILSON, R. H., DEEDS, F., AND COX, A. J., JR. (1941). Effects of continued cadmium feeding. *J. Pharmacol. Exp. Ther.* **71**, 222–235.